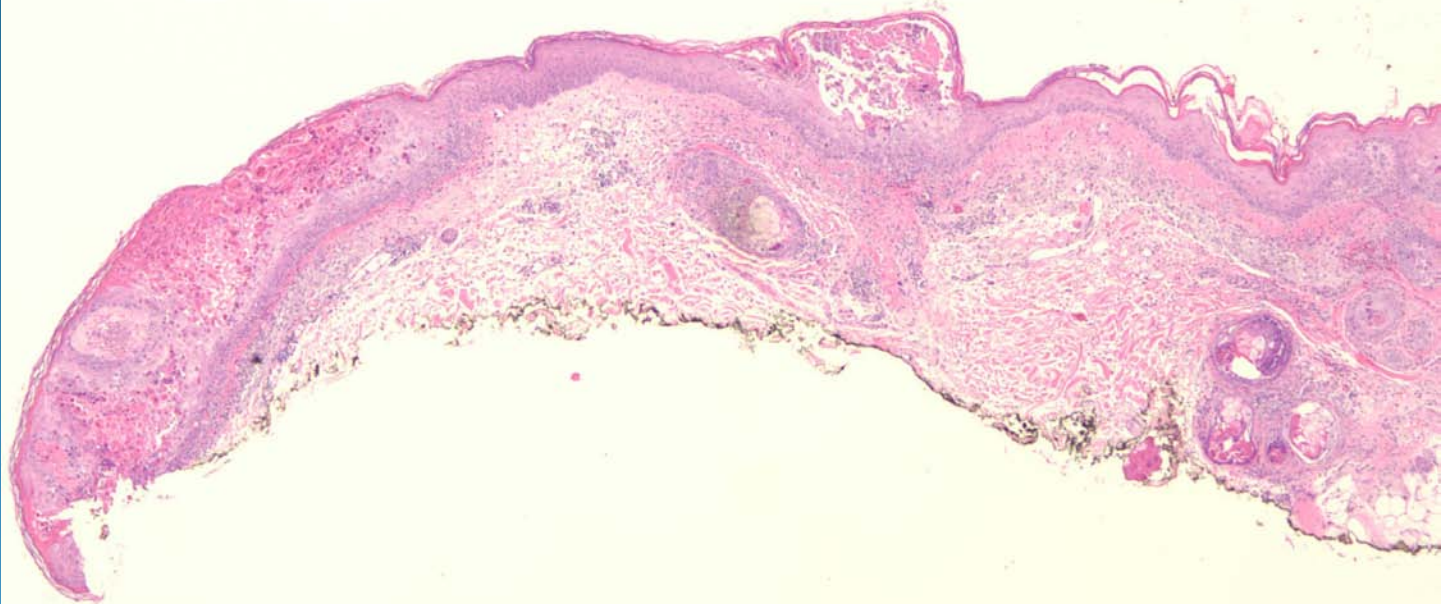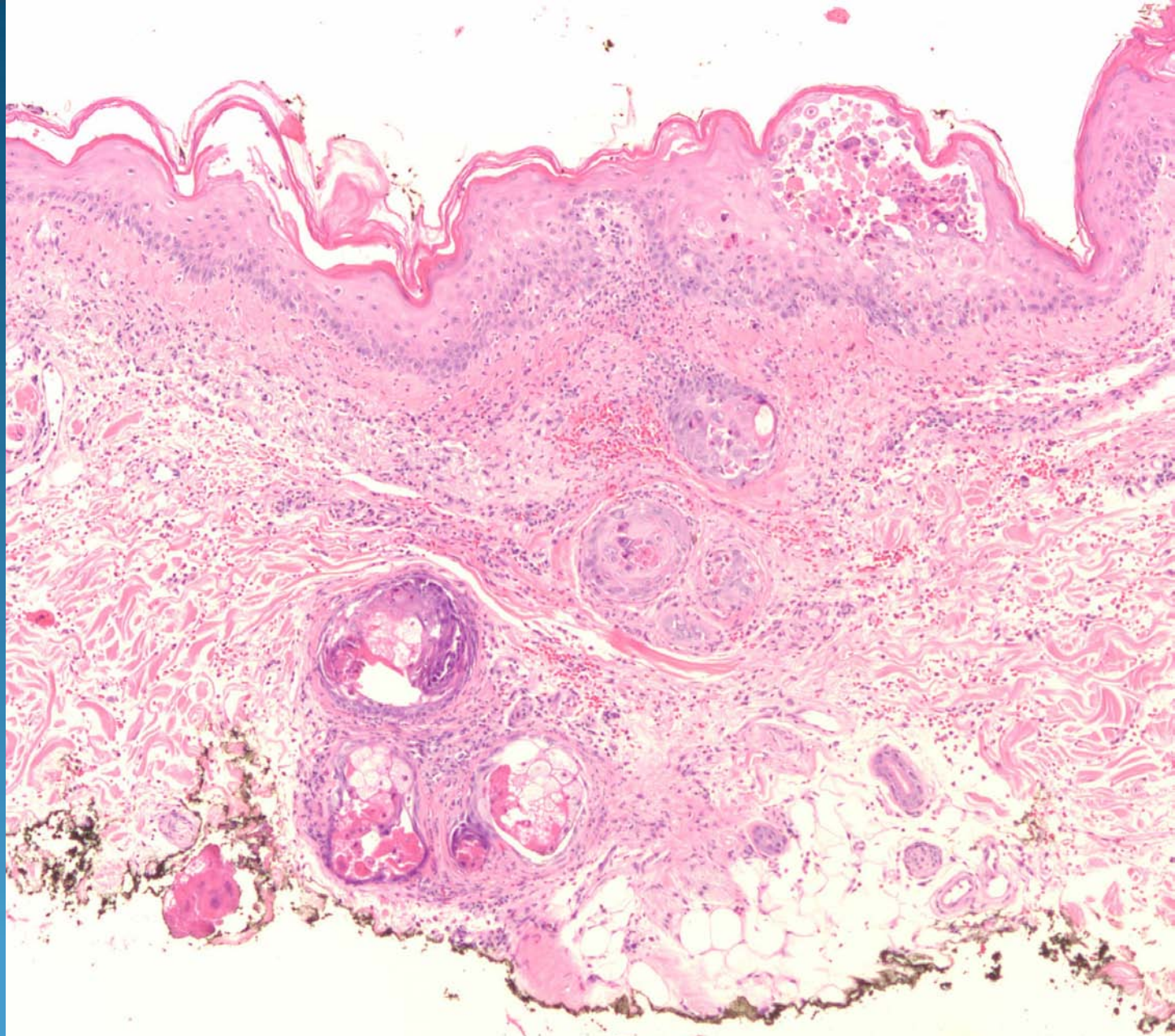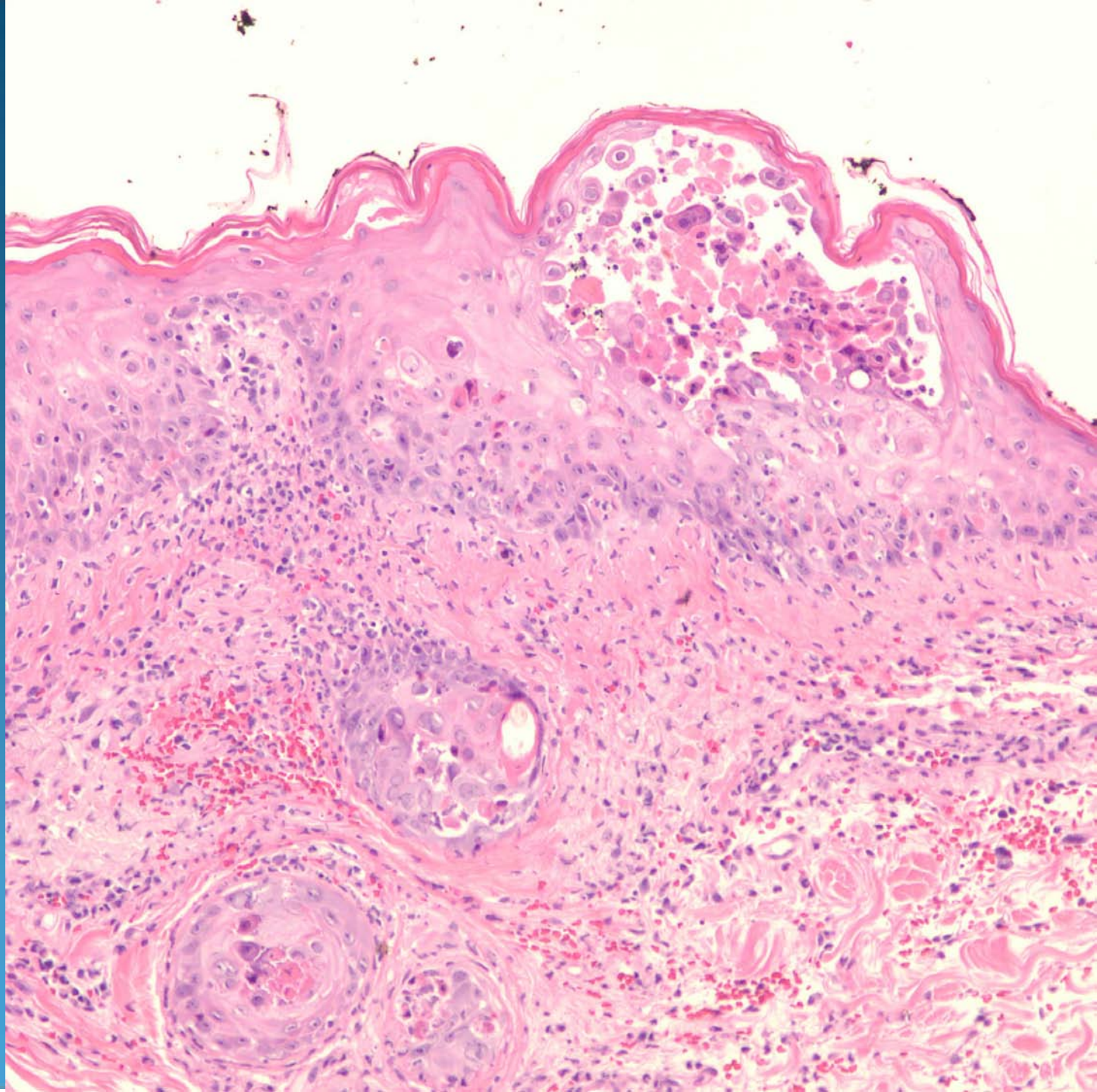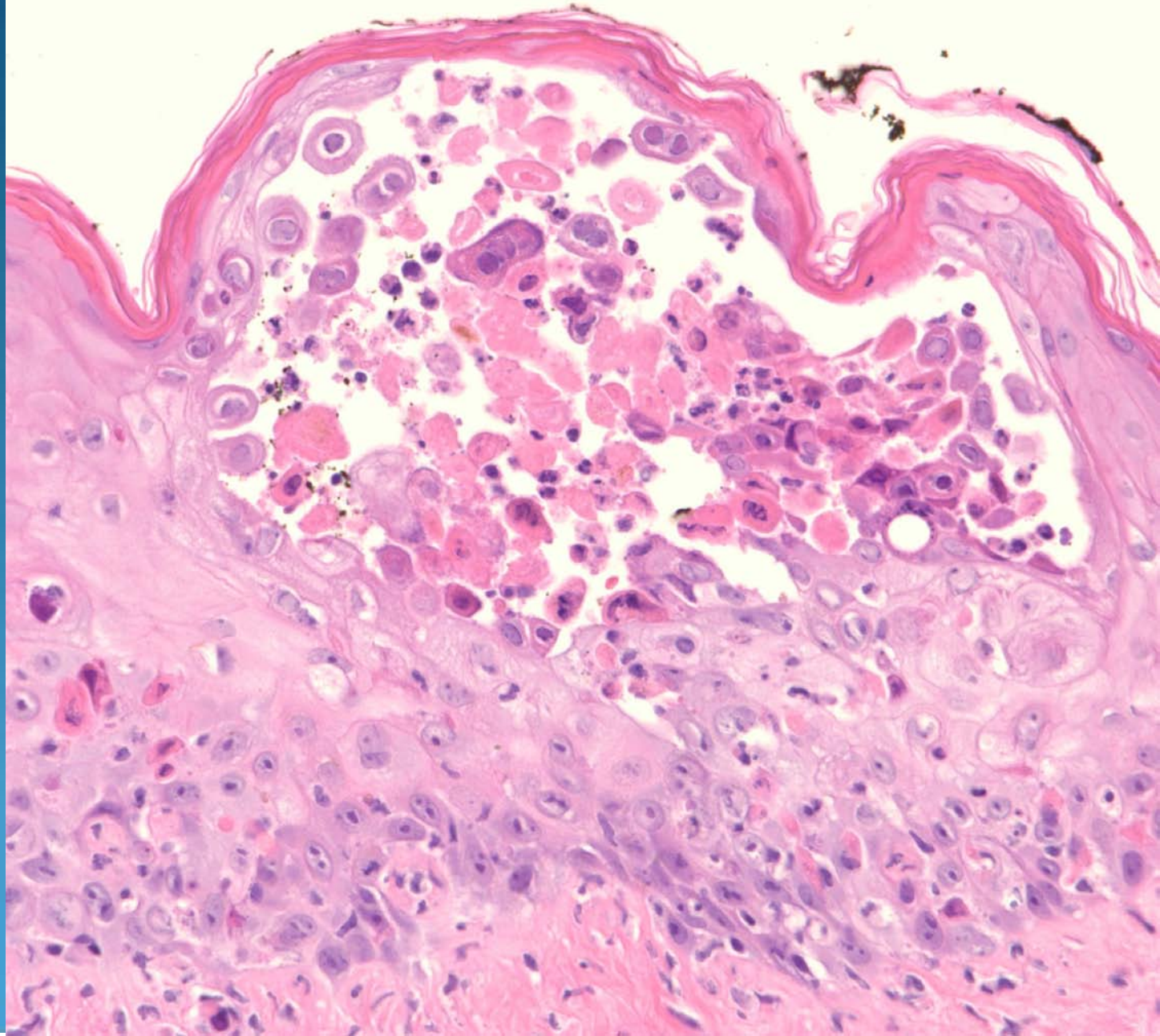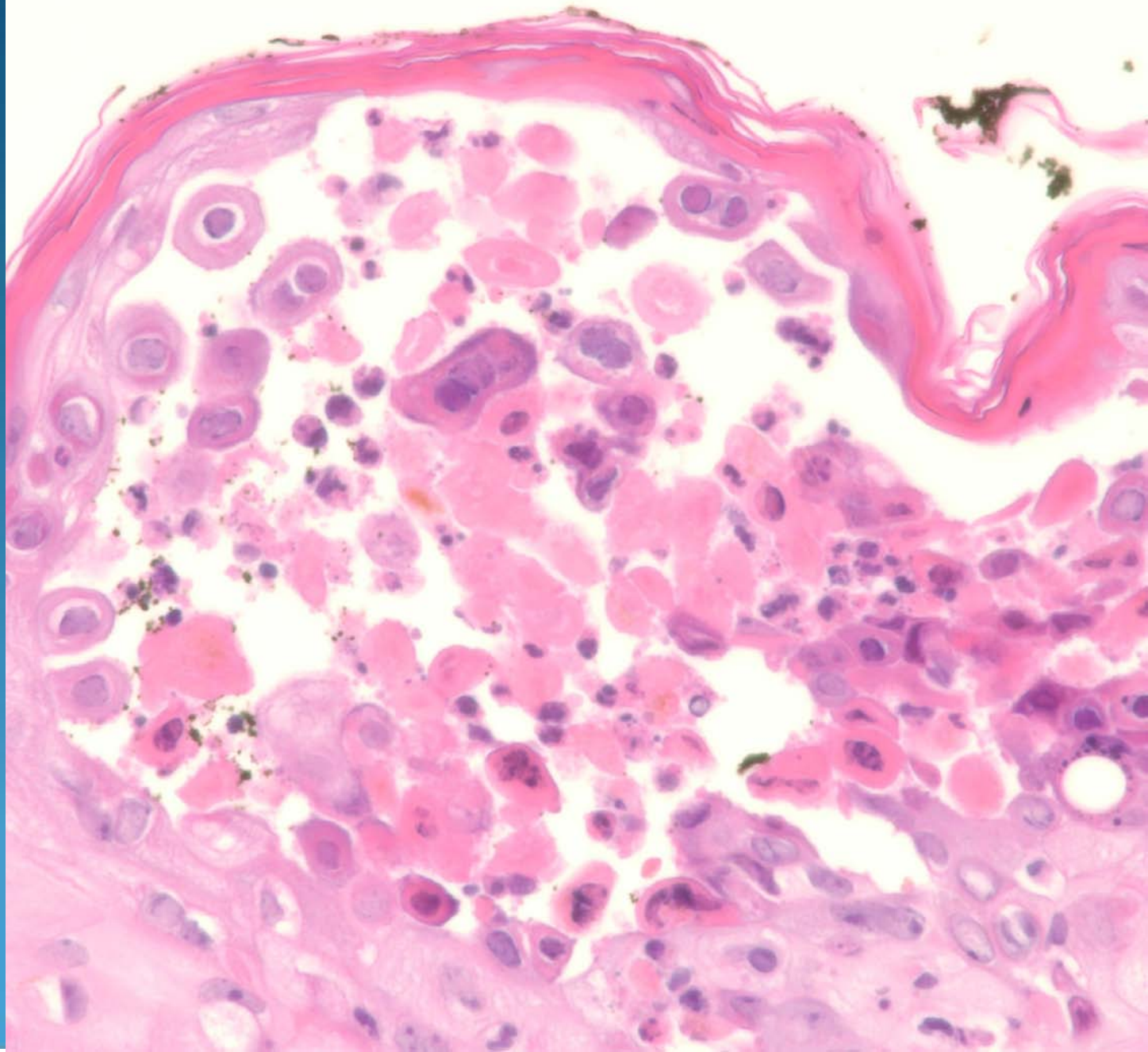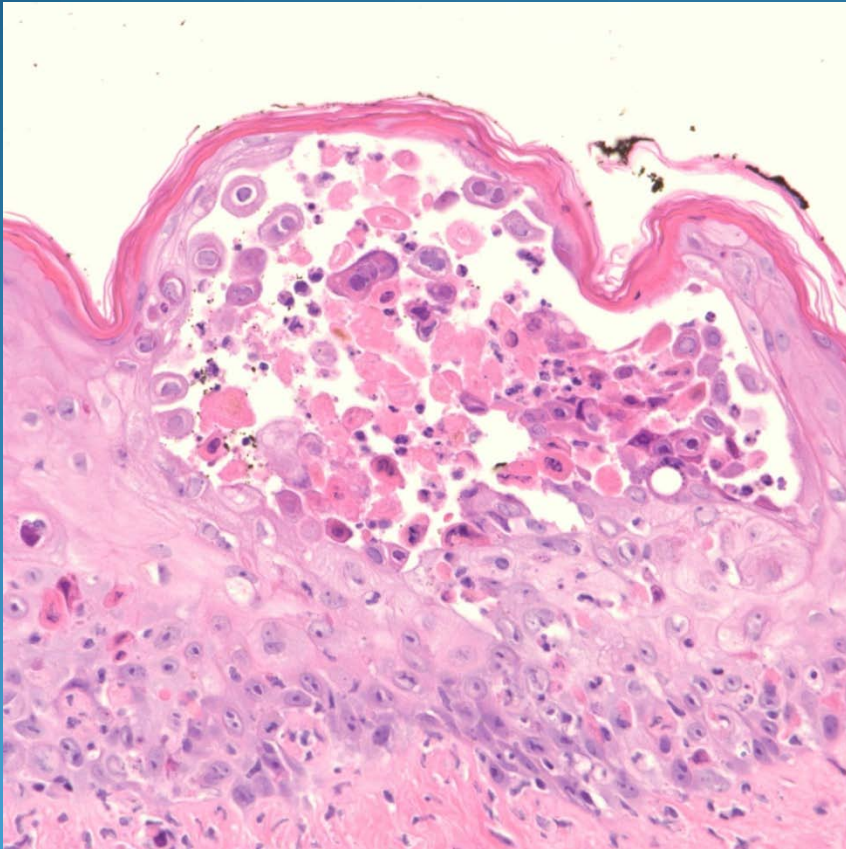


Zoster (Shingles)

Pearls



- May be histologically similar to Herpes virus infection
- Intraepithelial blister with acantholytic cells showing multinucleation and nuclear chromatin margination
- Early cases may show perineural lymphocytic infiltration
- Clinical-pathological correlation
- Negative staining for HSVI/II antibodies