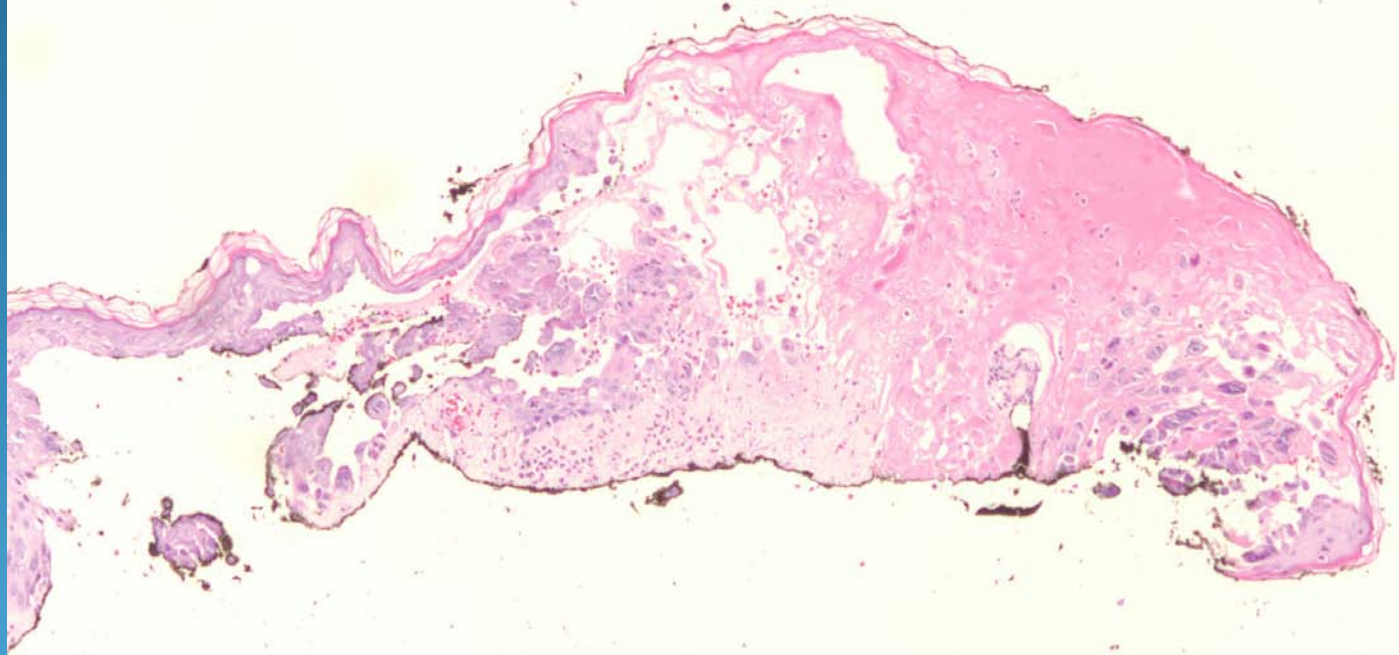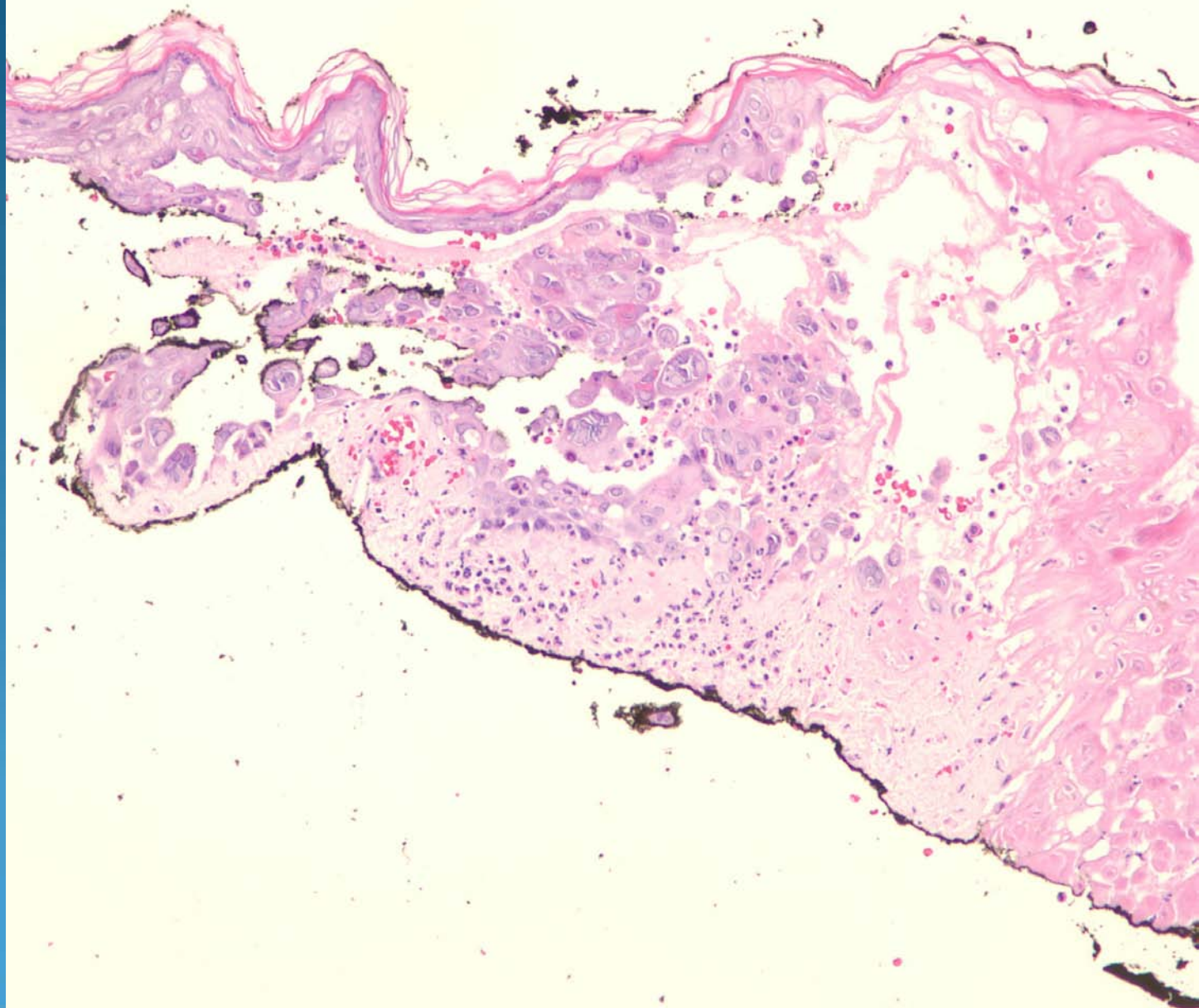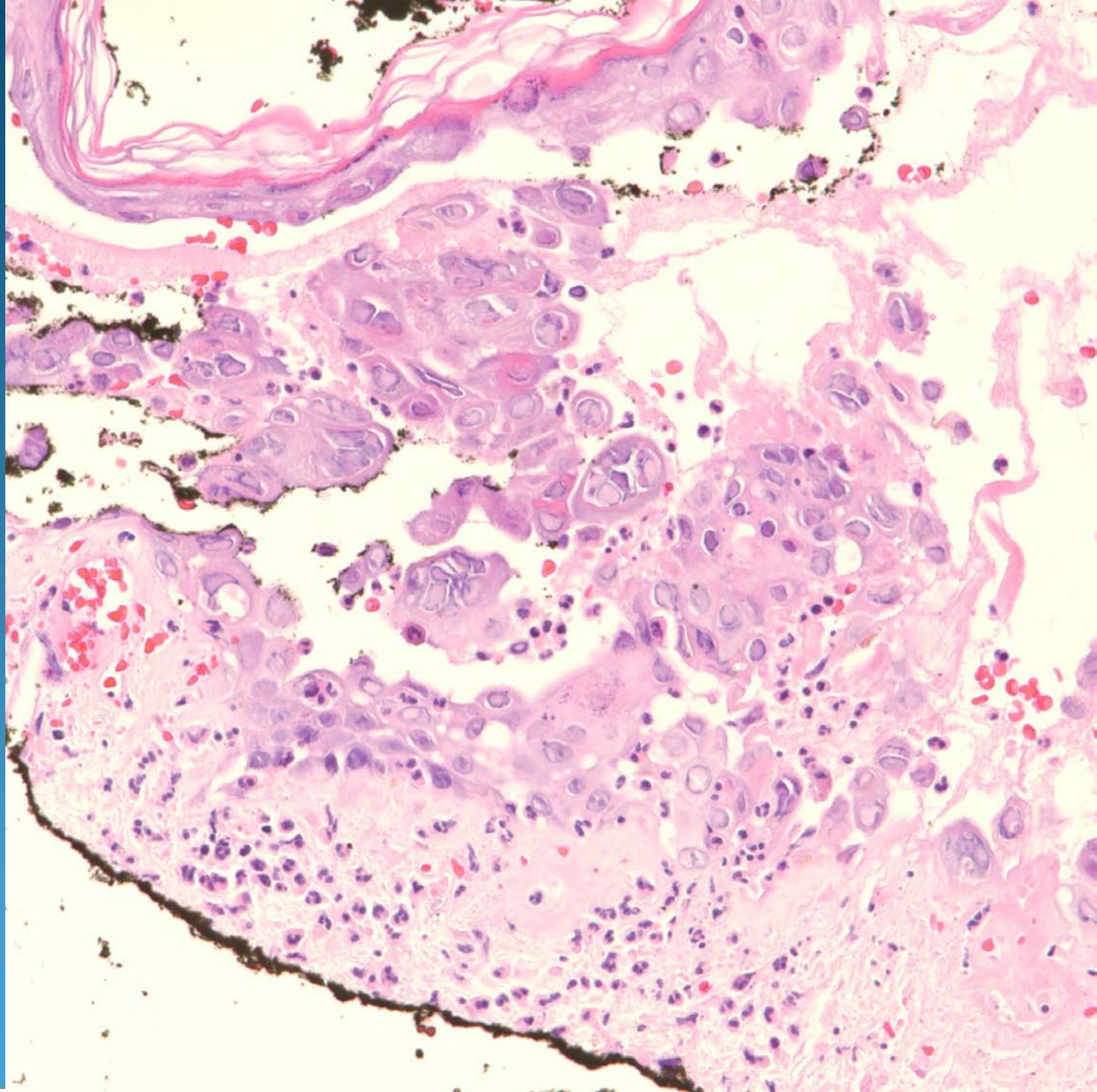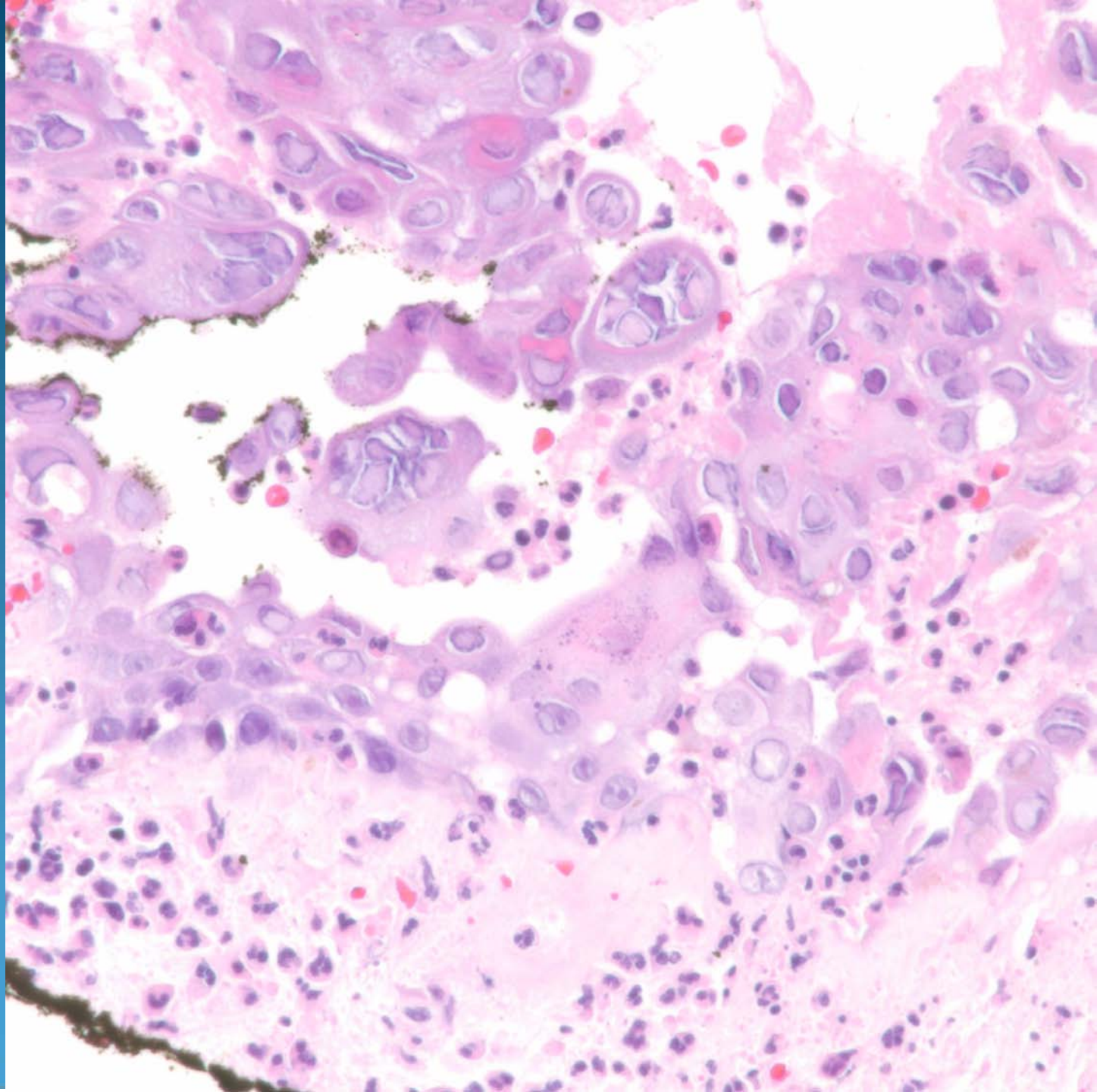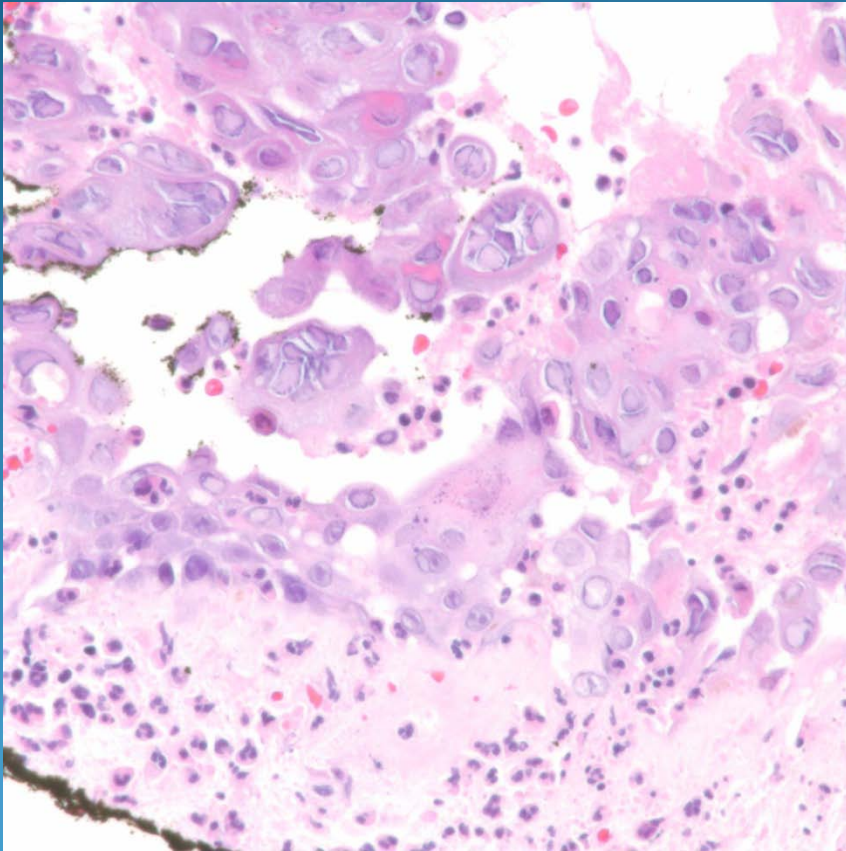


Zoster (Shingles)

Pearls



- Intraepidermal blister with acantholytic cells
- Look for viral cytopathic changes within acantholytic cells- chromatin margination and multinucleation
- May see changes extend along adnexal epithelium