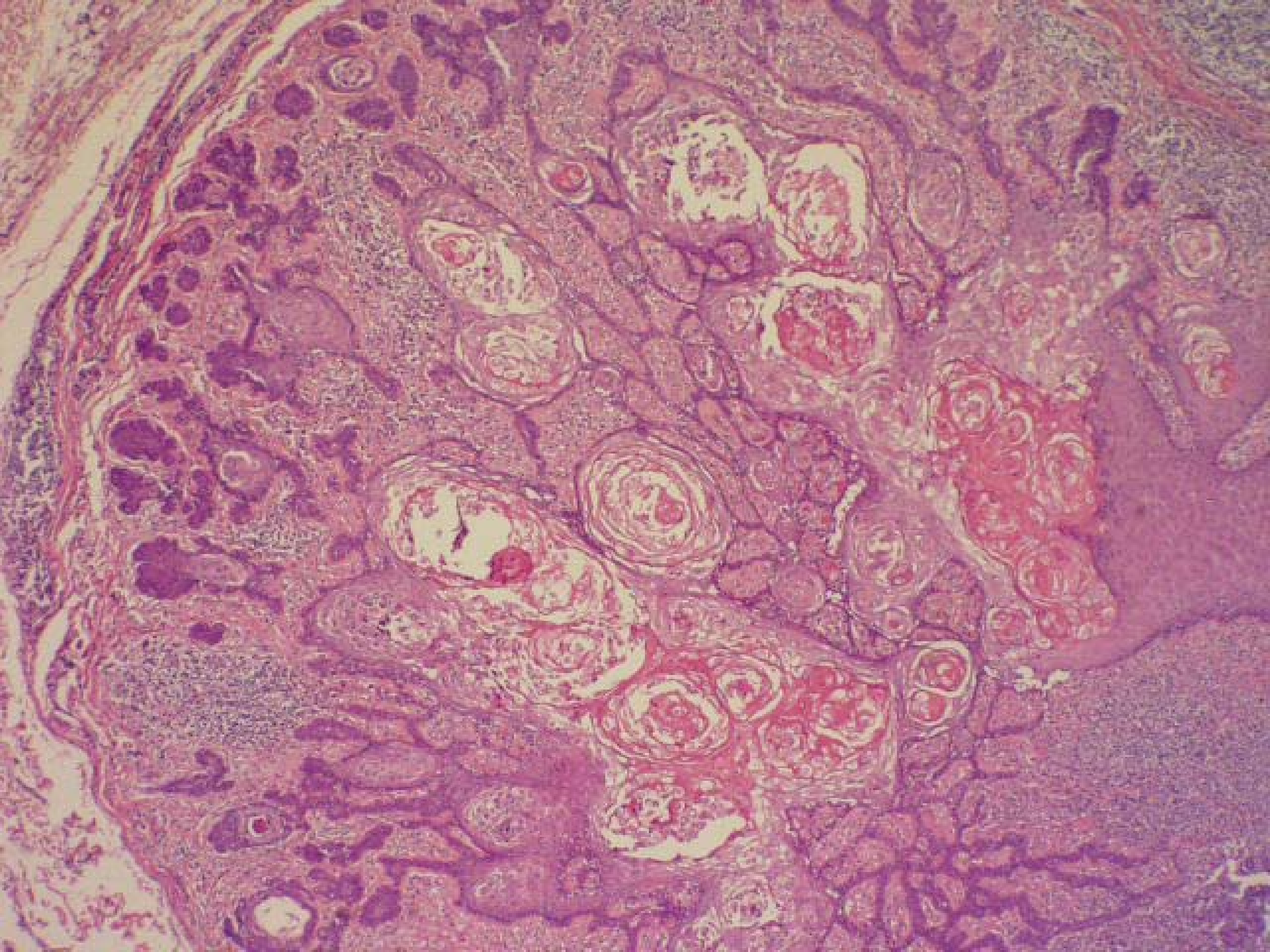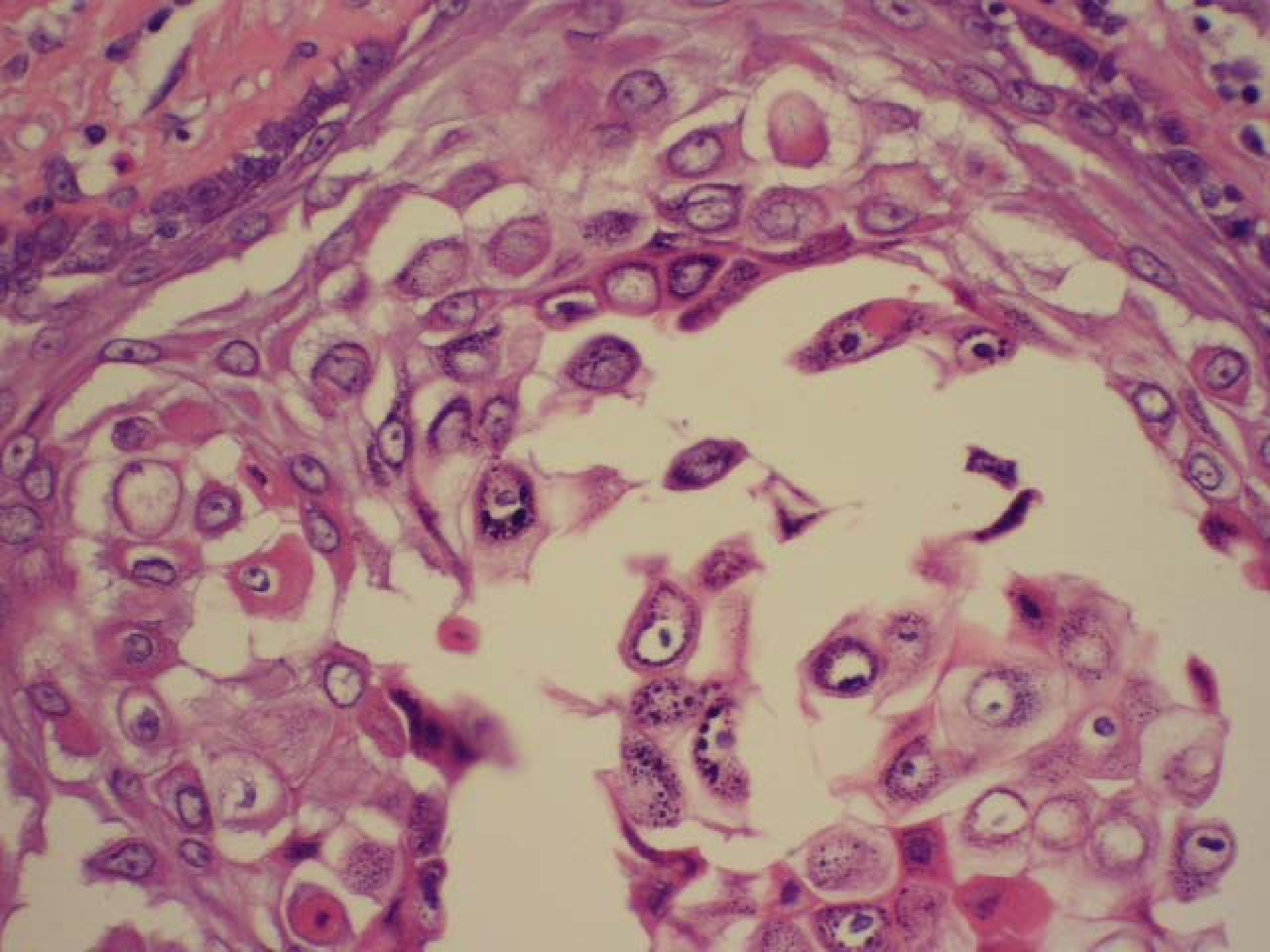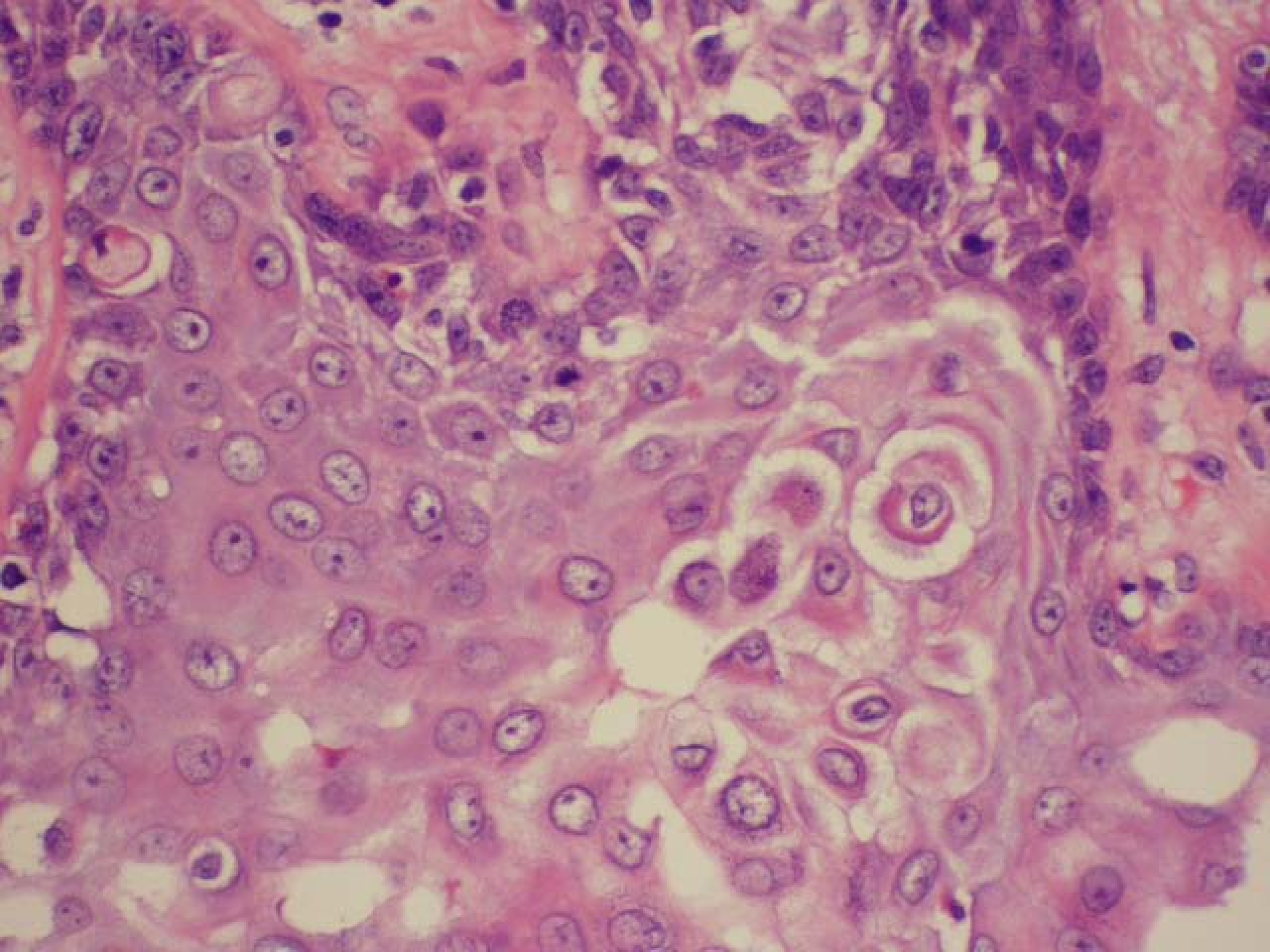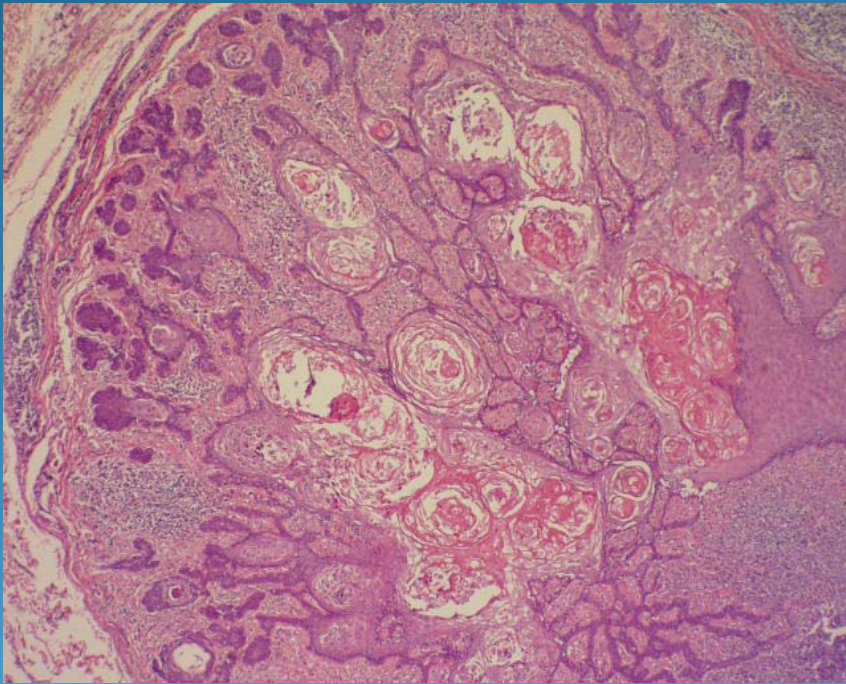


Warty Dyskeratoma

Pearls



- Cup-shaped invagination with acantholytic villi
- Corp ronds and corp grains
- Follicular process resembling a cyst with acantholysis