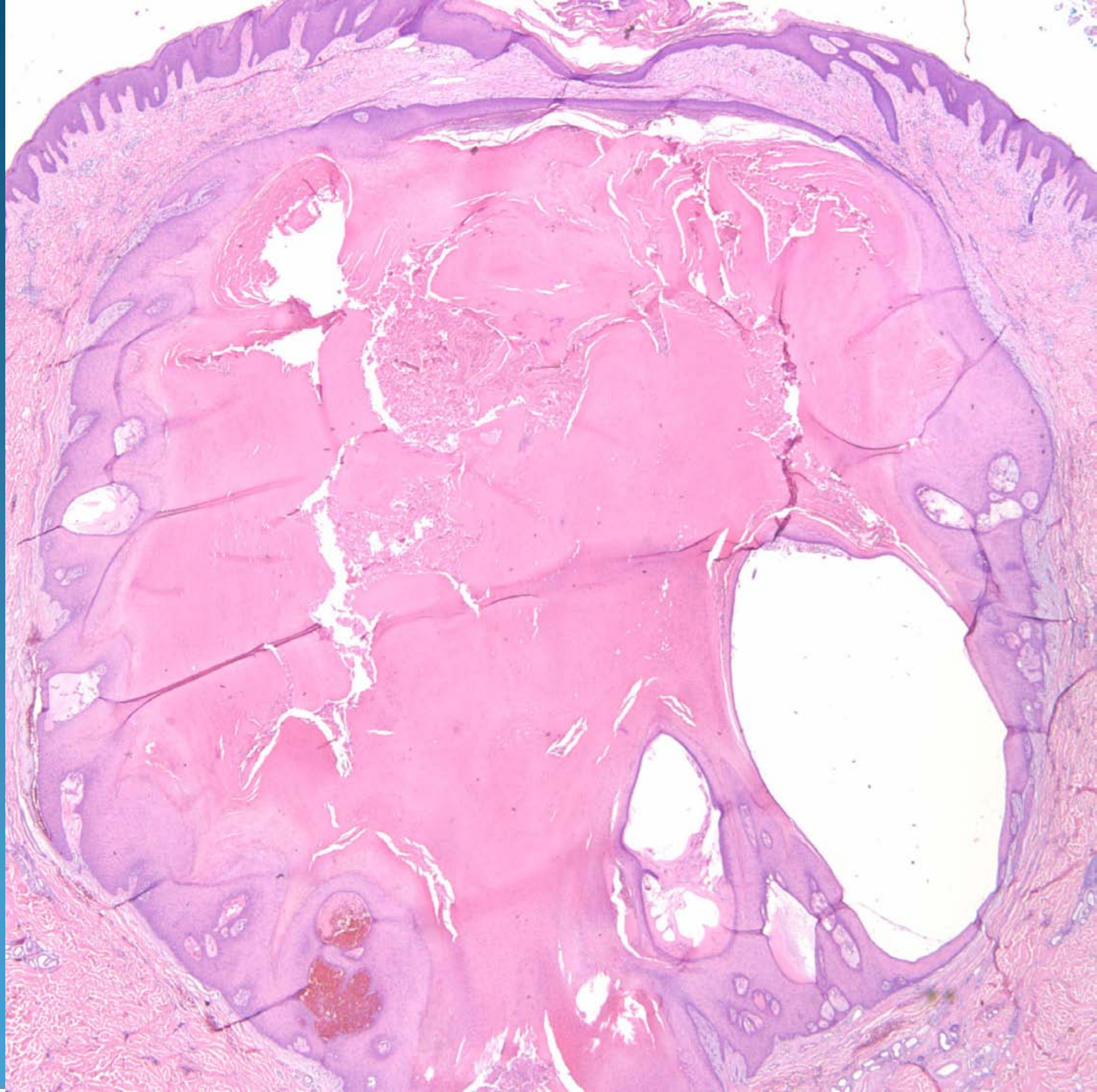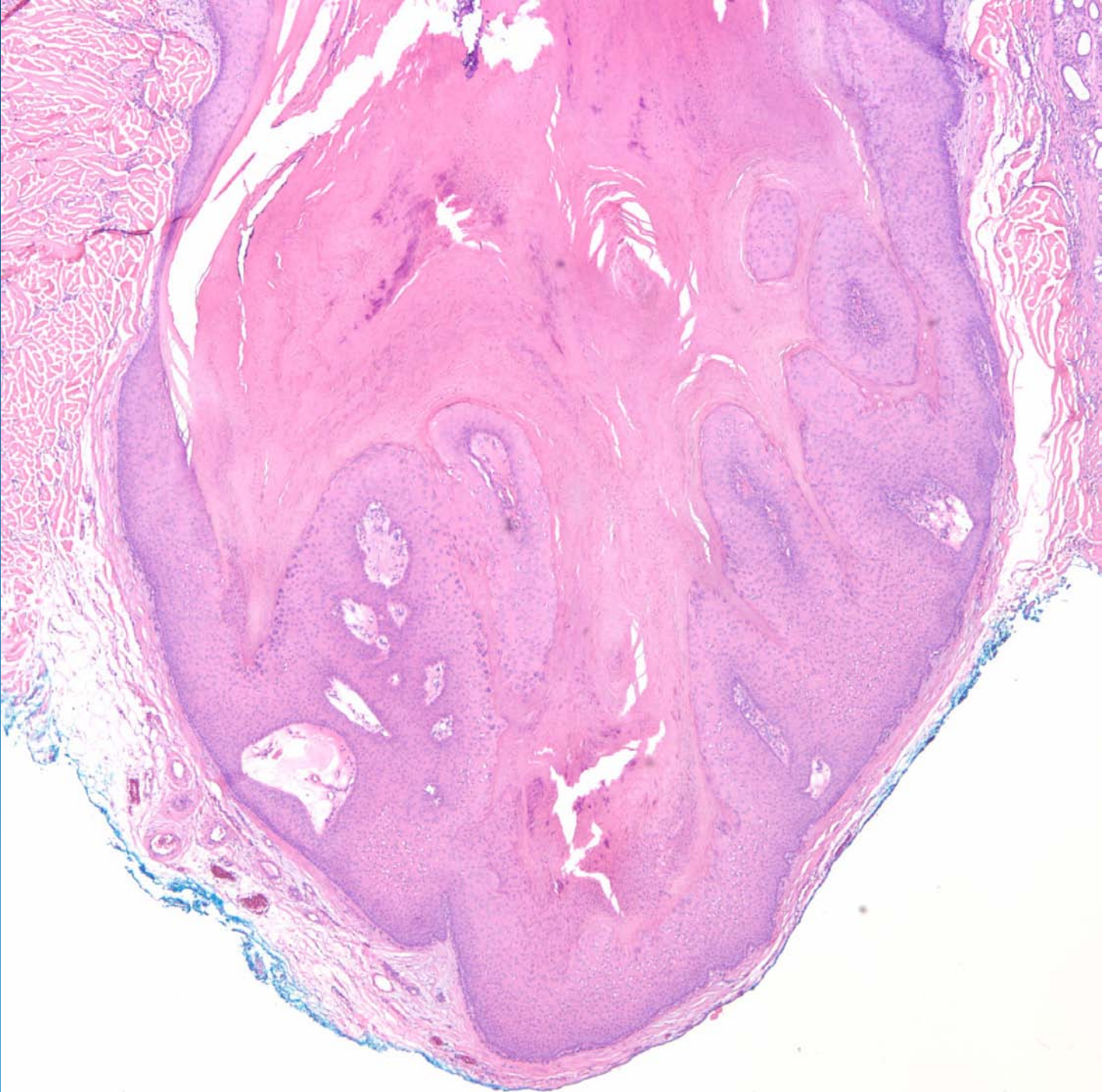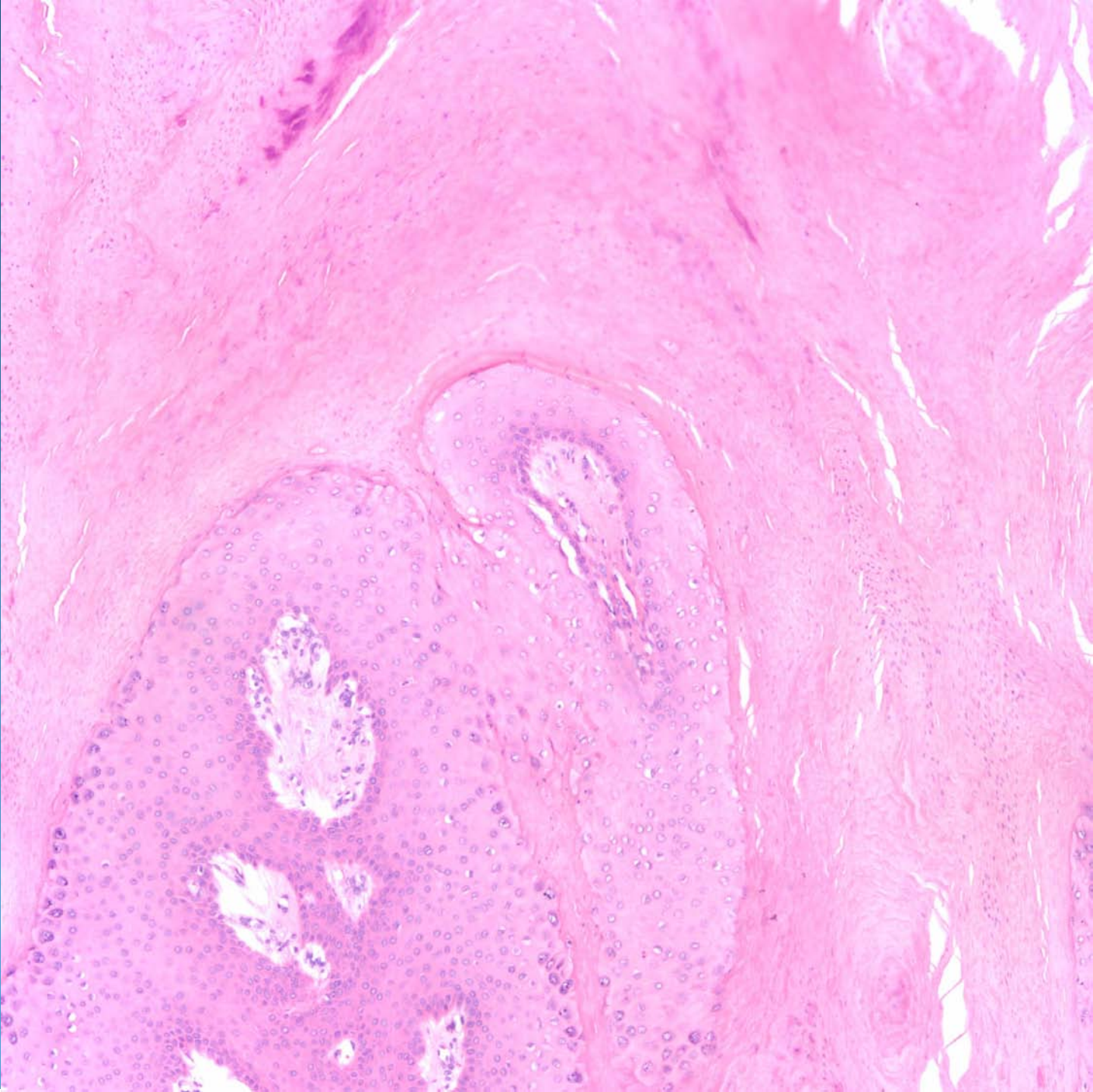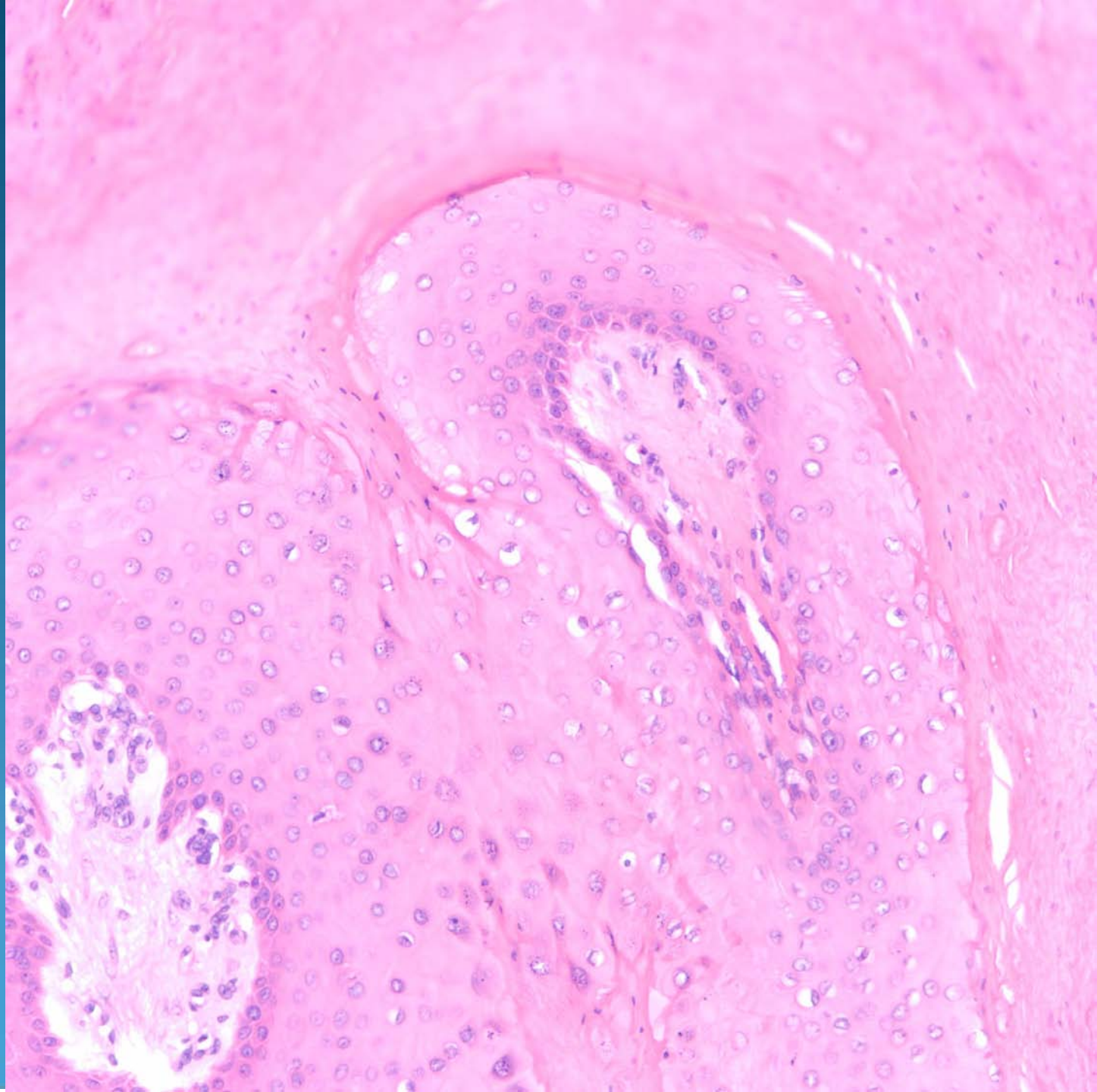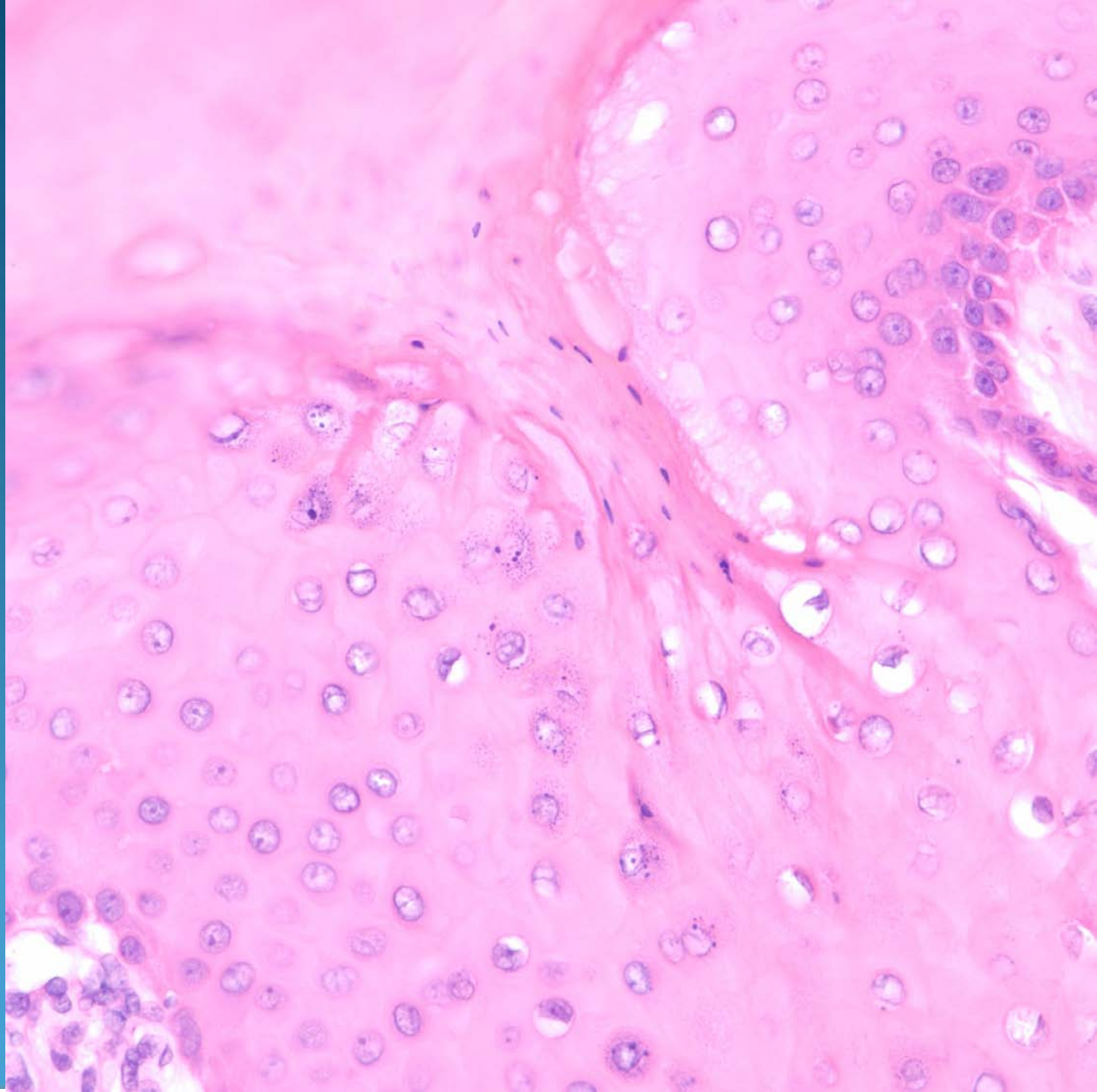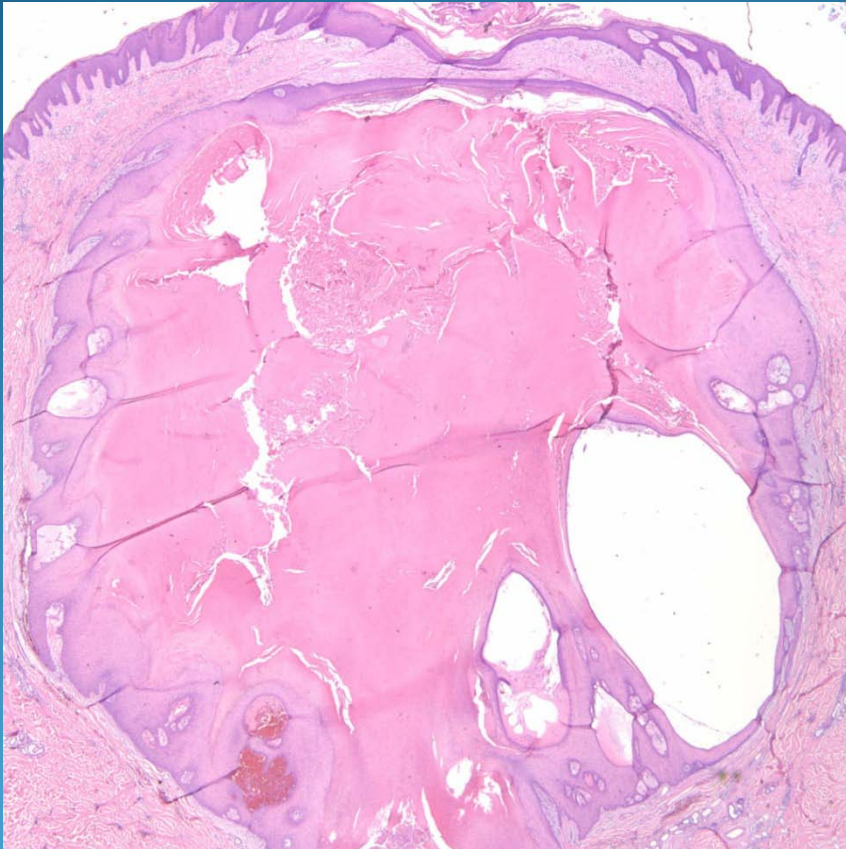


Verrucous Epidermal Cyst

Pearls



- Circumscribed epithelial cyst
- Verruciform epidermal projections into cyst lumen
- Look for viral cytopathic changes of koilocytes and hypergranulosis