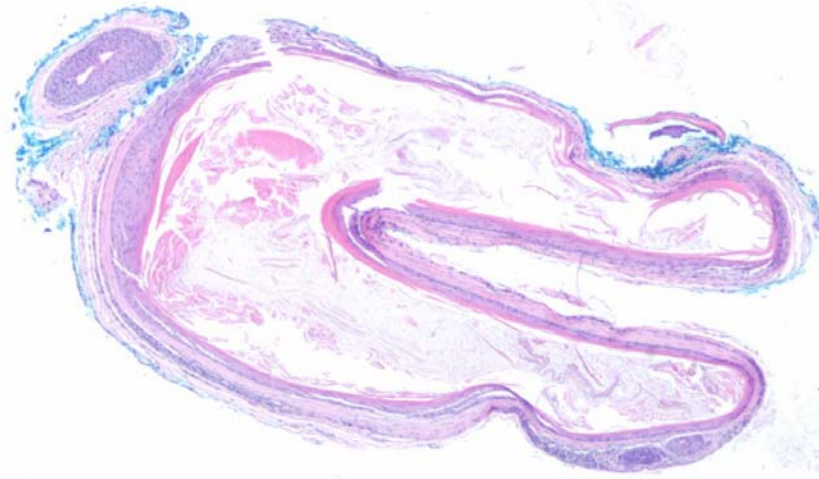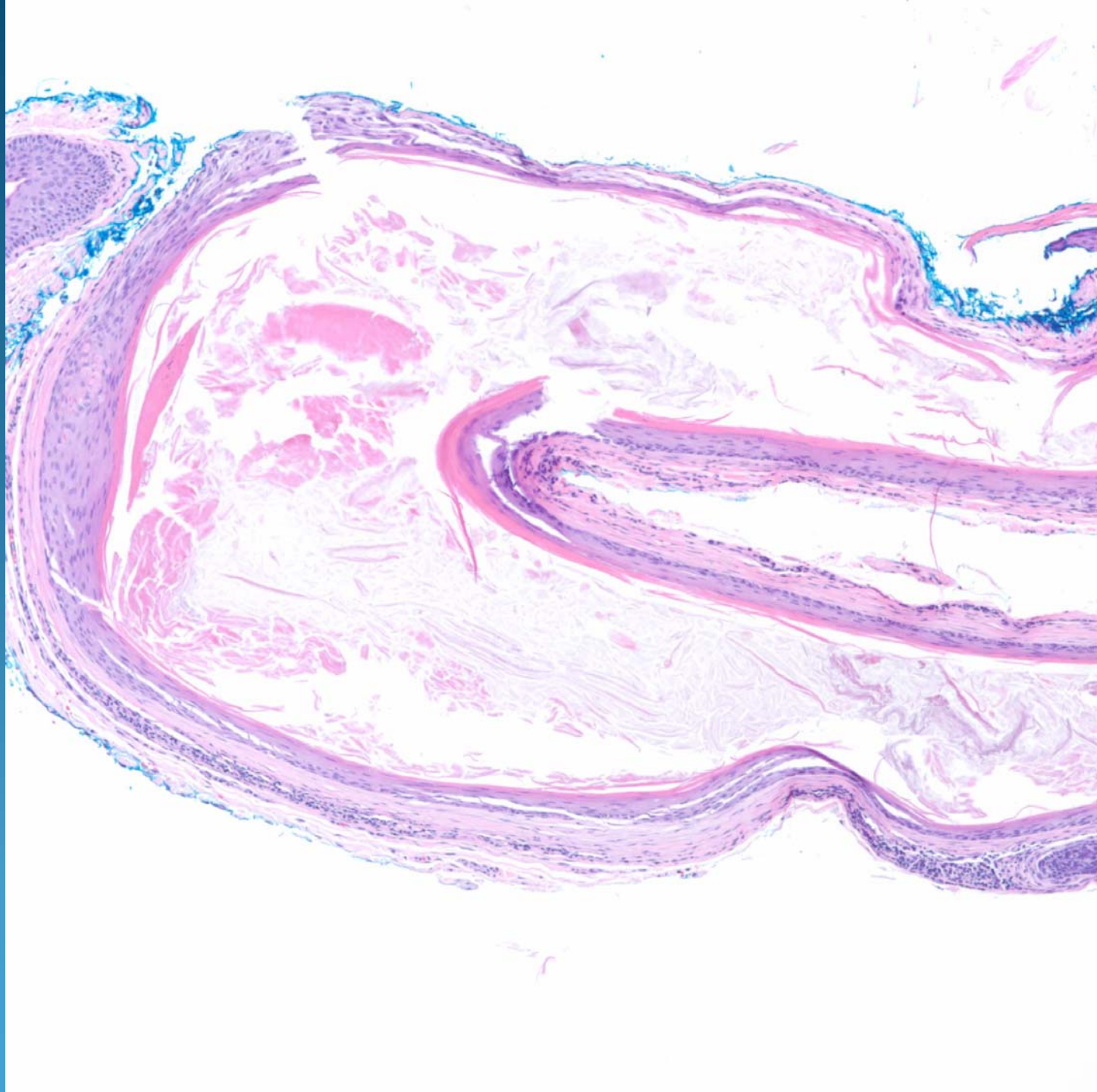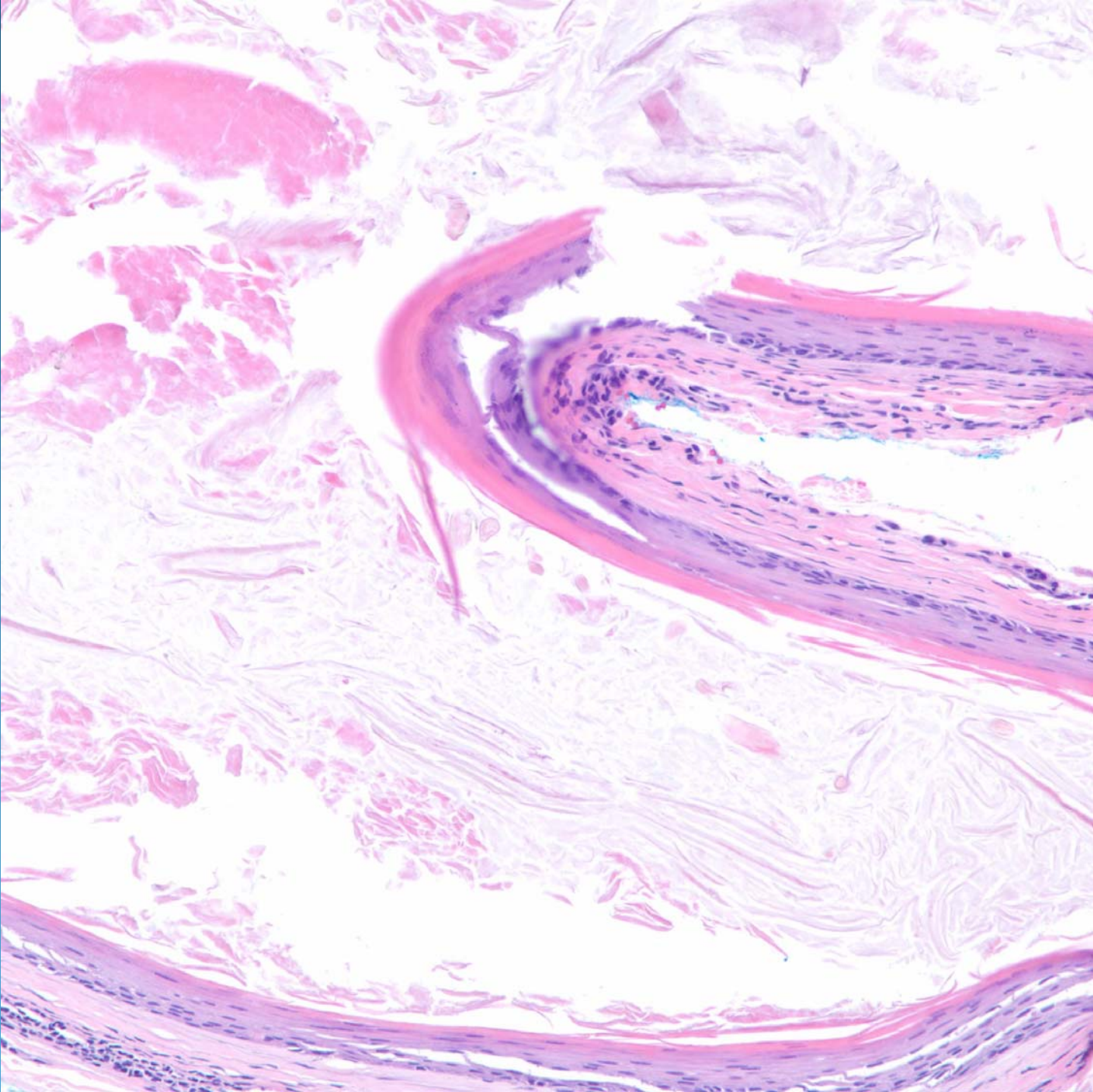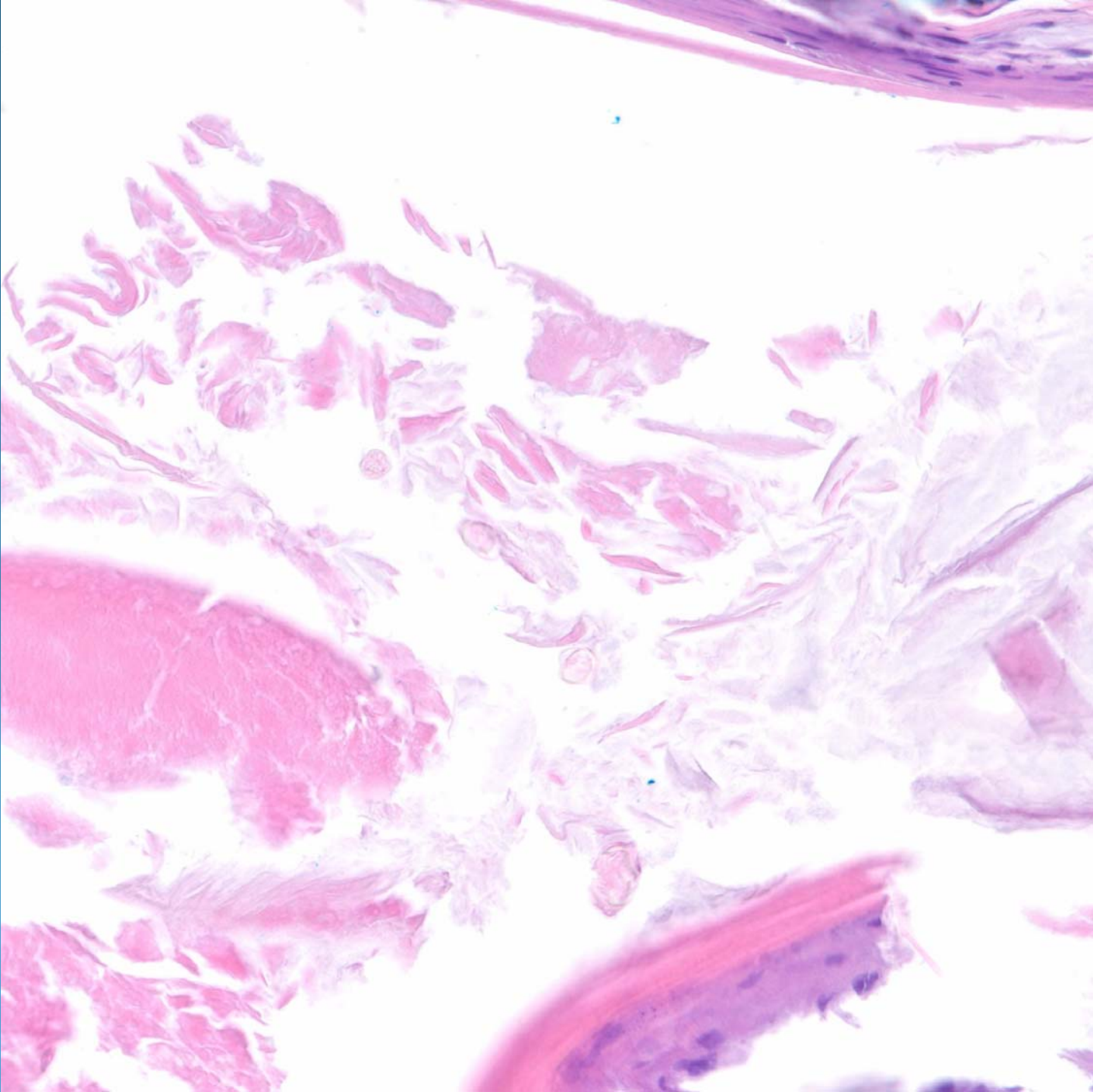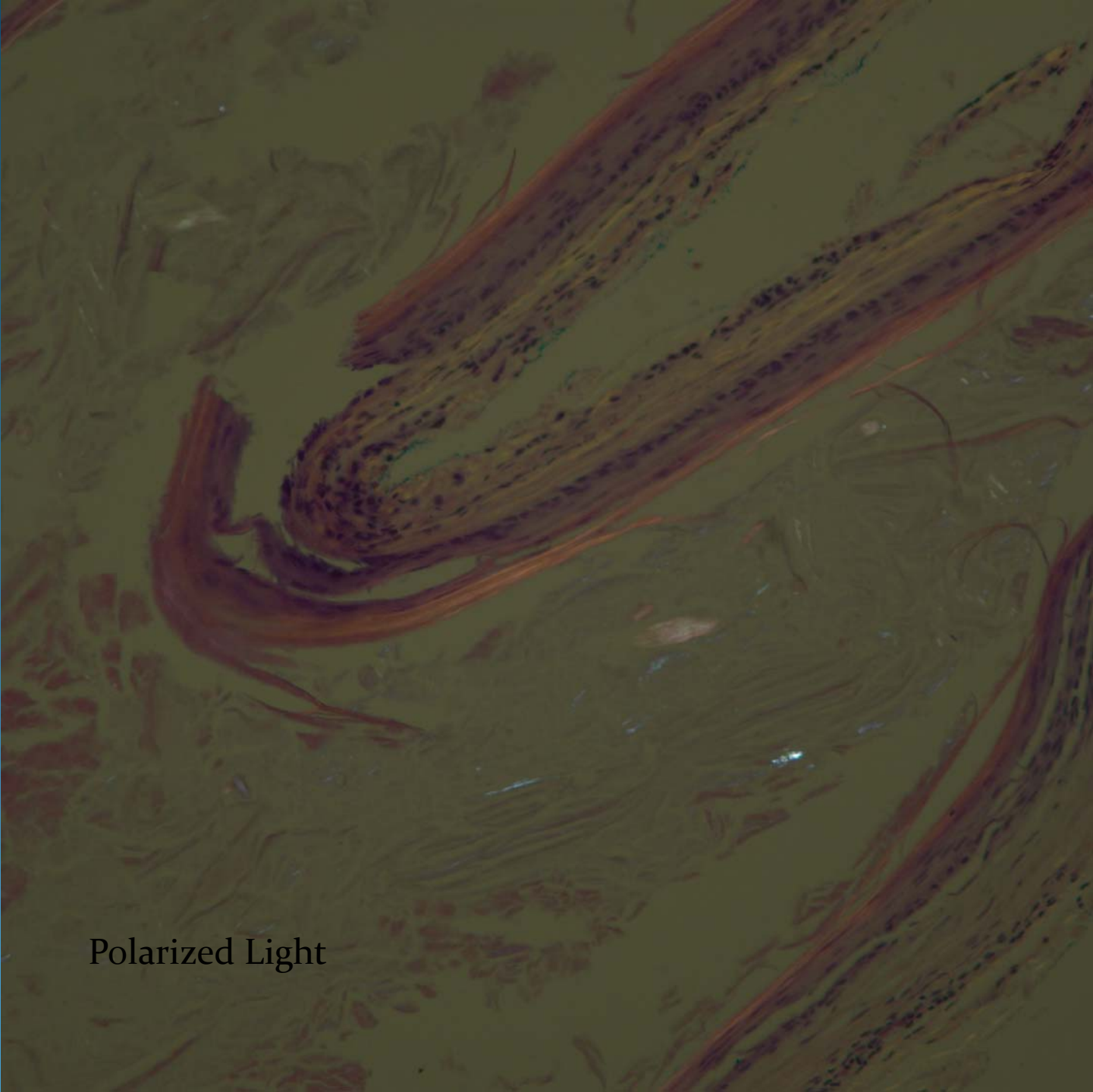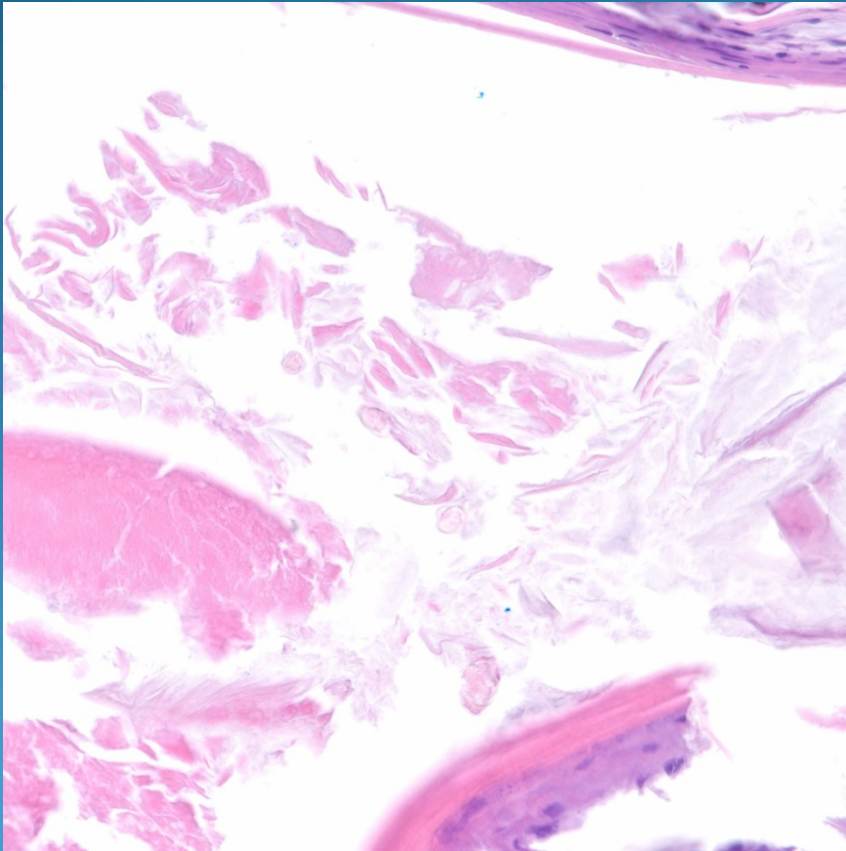


Polarized Light

Vellus Hair Cyst

Pearls



- Epithelial cyst surrounding laminated keratin
- Look for vellus hairs, may need to examine with polarized light
- Lacks sebaceous lobules in the wall, rule out steatocystoma