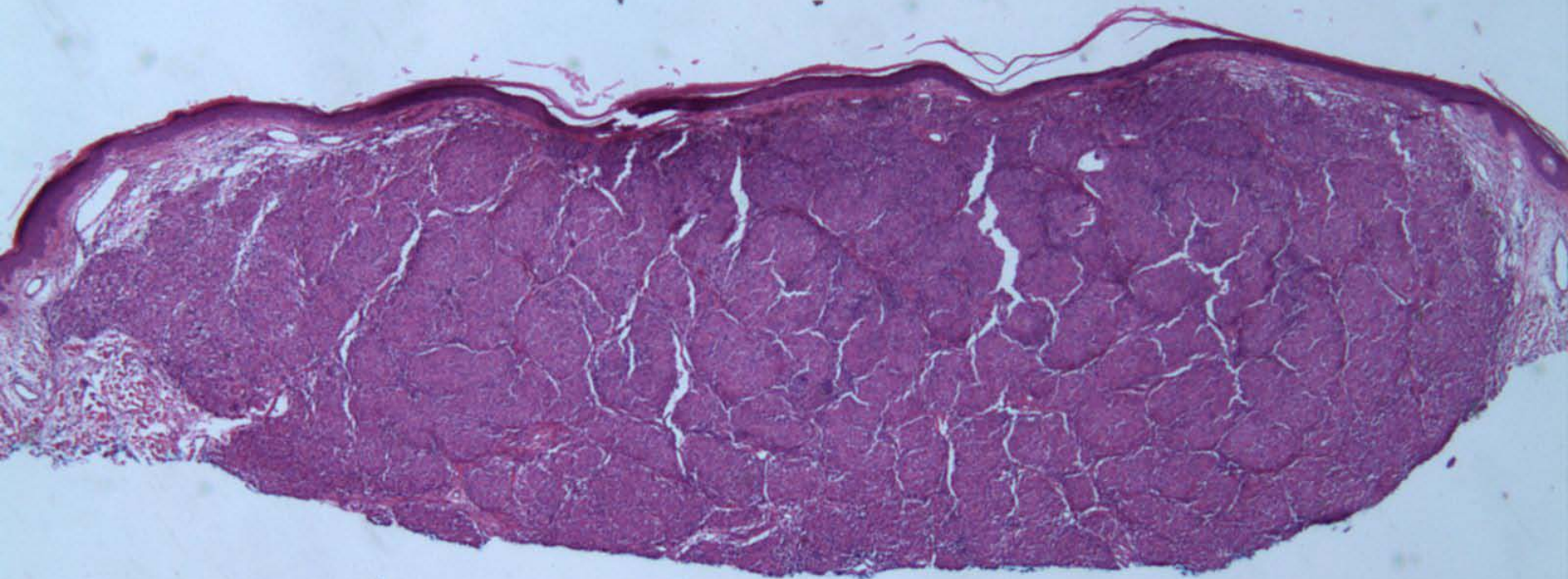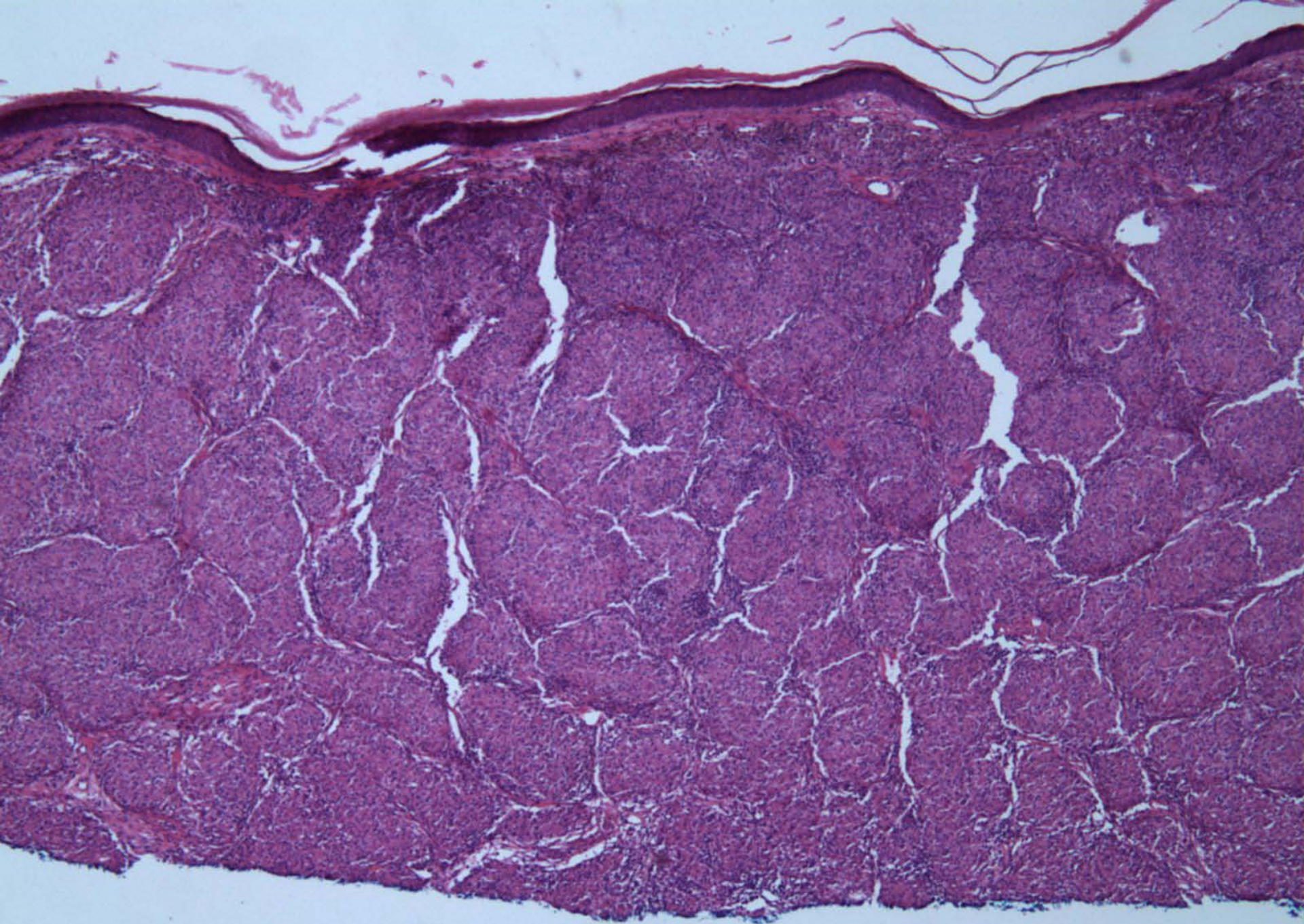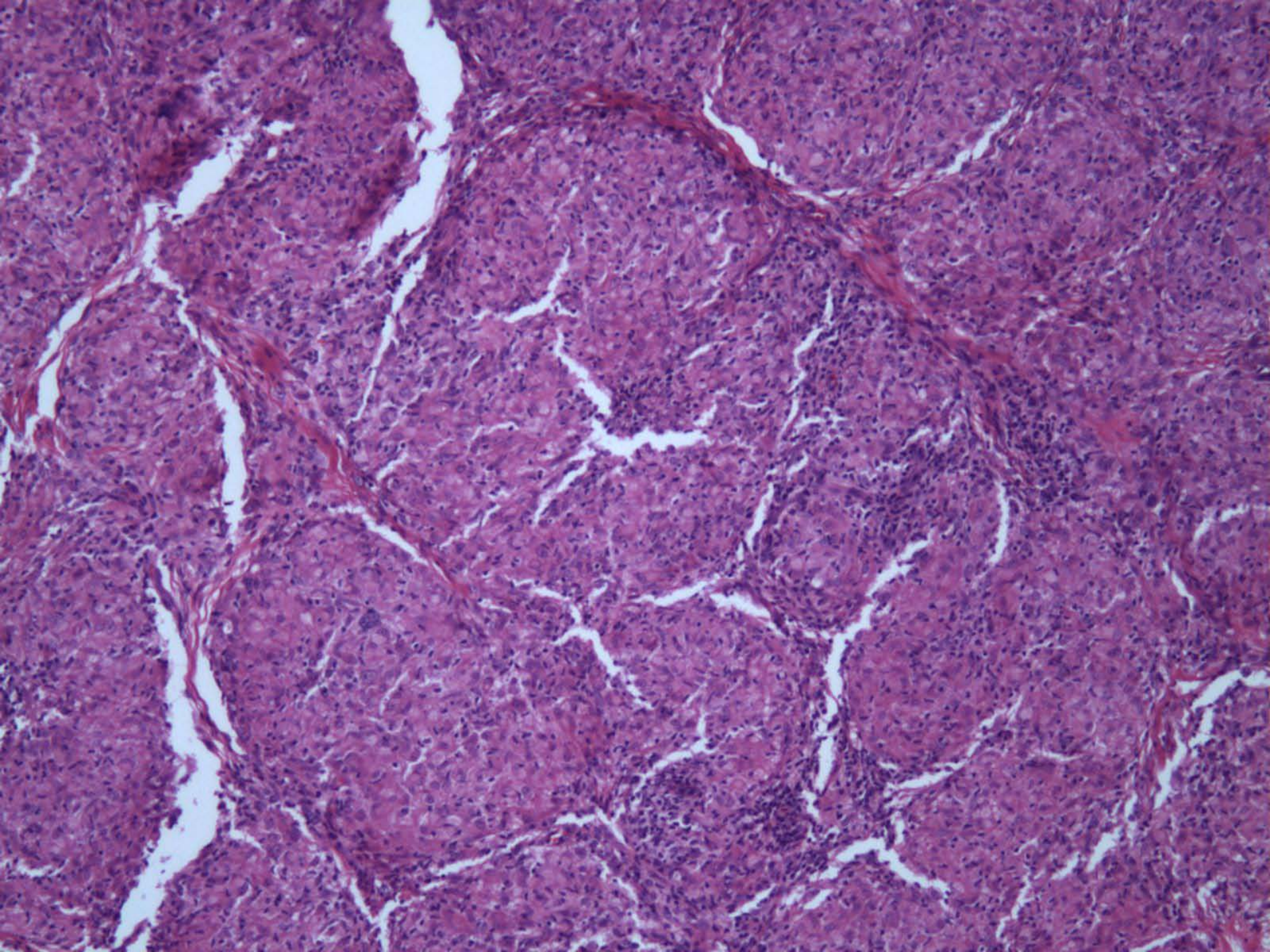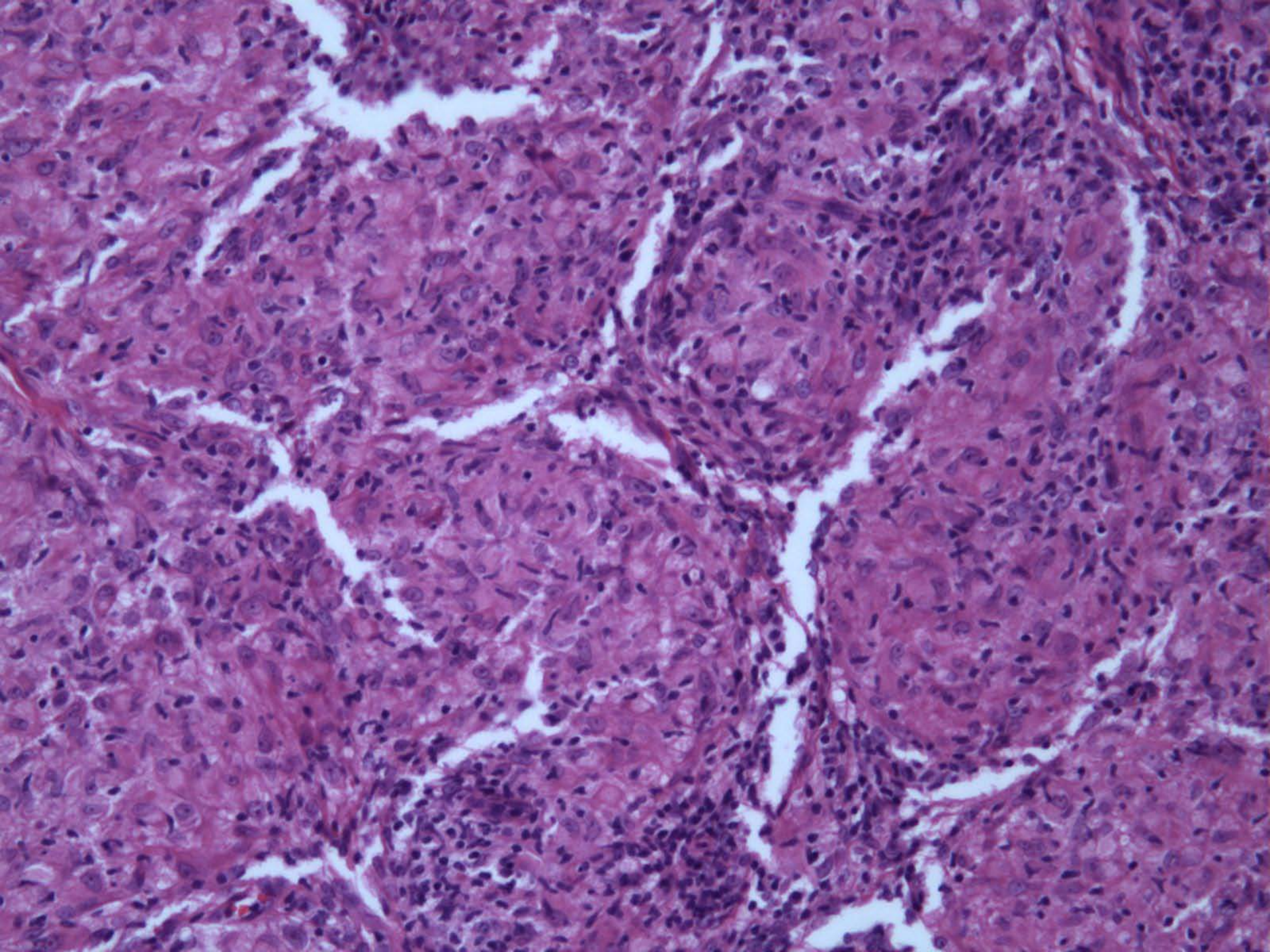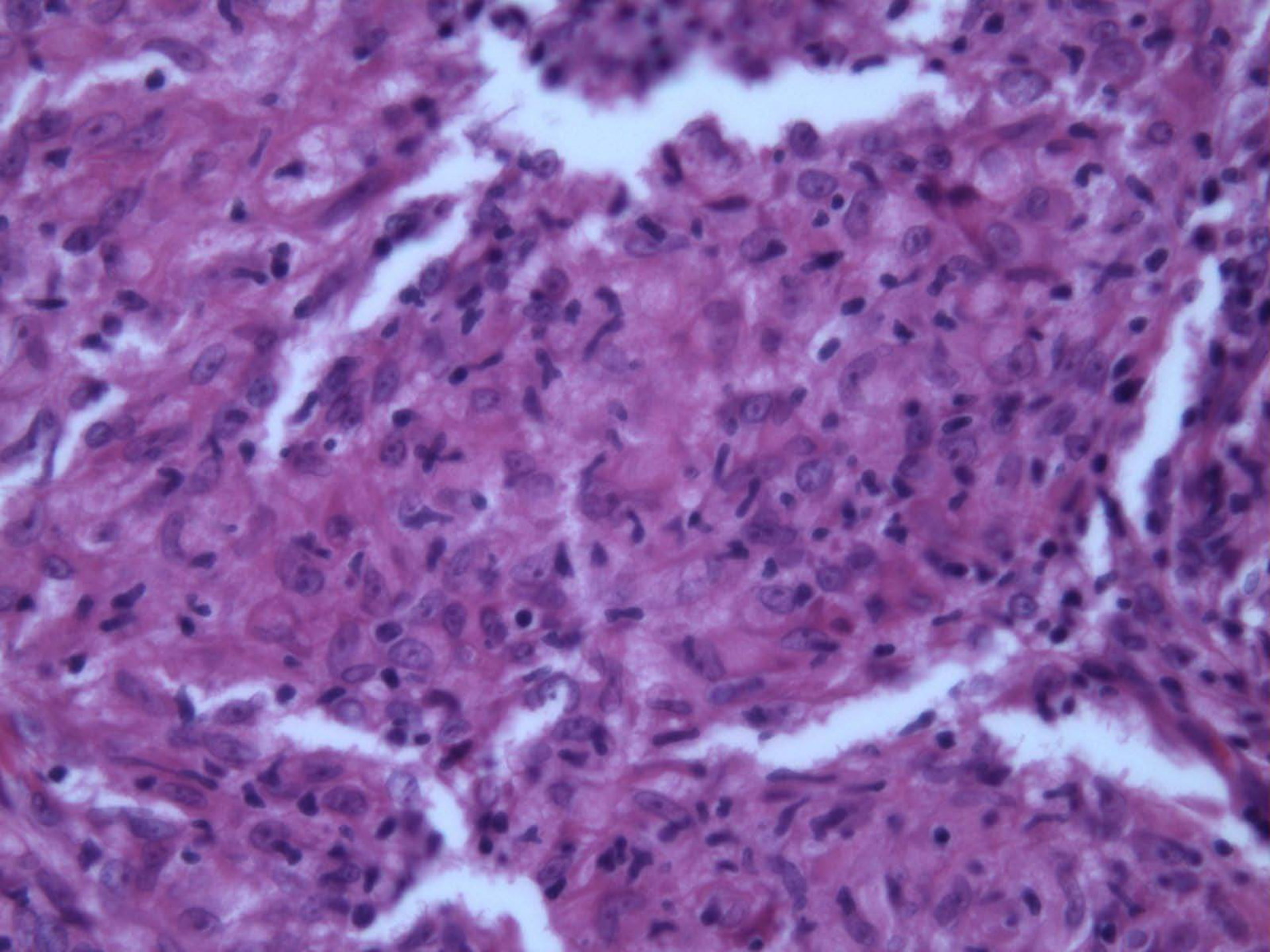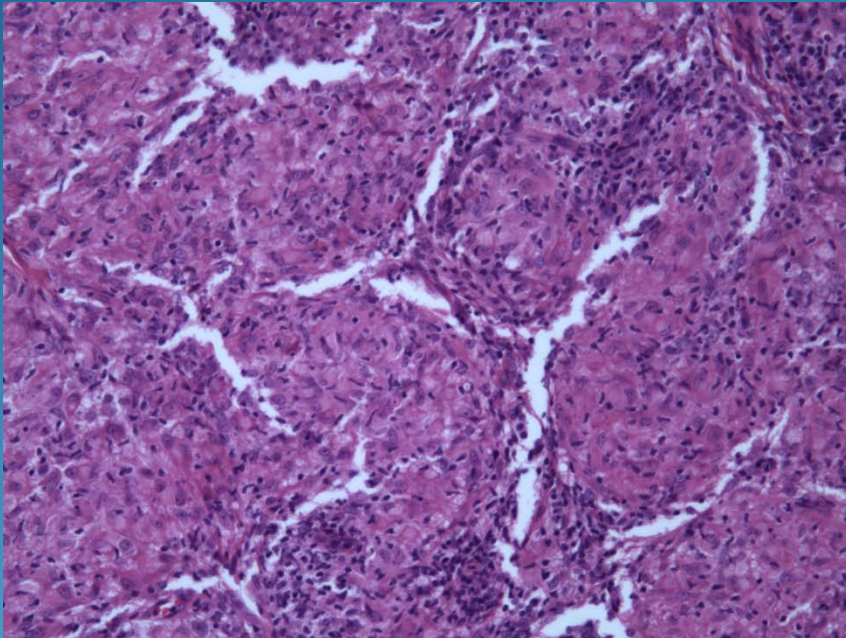


Tuberculoid Leprosy

Pearls



- Sarcoidal-like granulomas
- May follow cutaneous nerves
- Rule out Sarcoidosis, foreign body granuloma, Zirconium/Beryllium/Silica granulomas