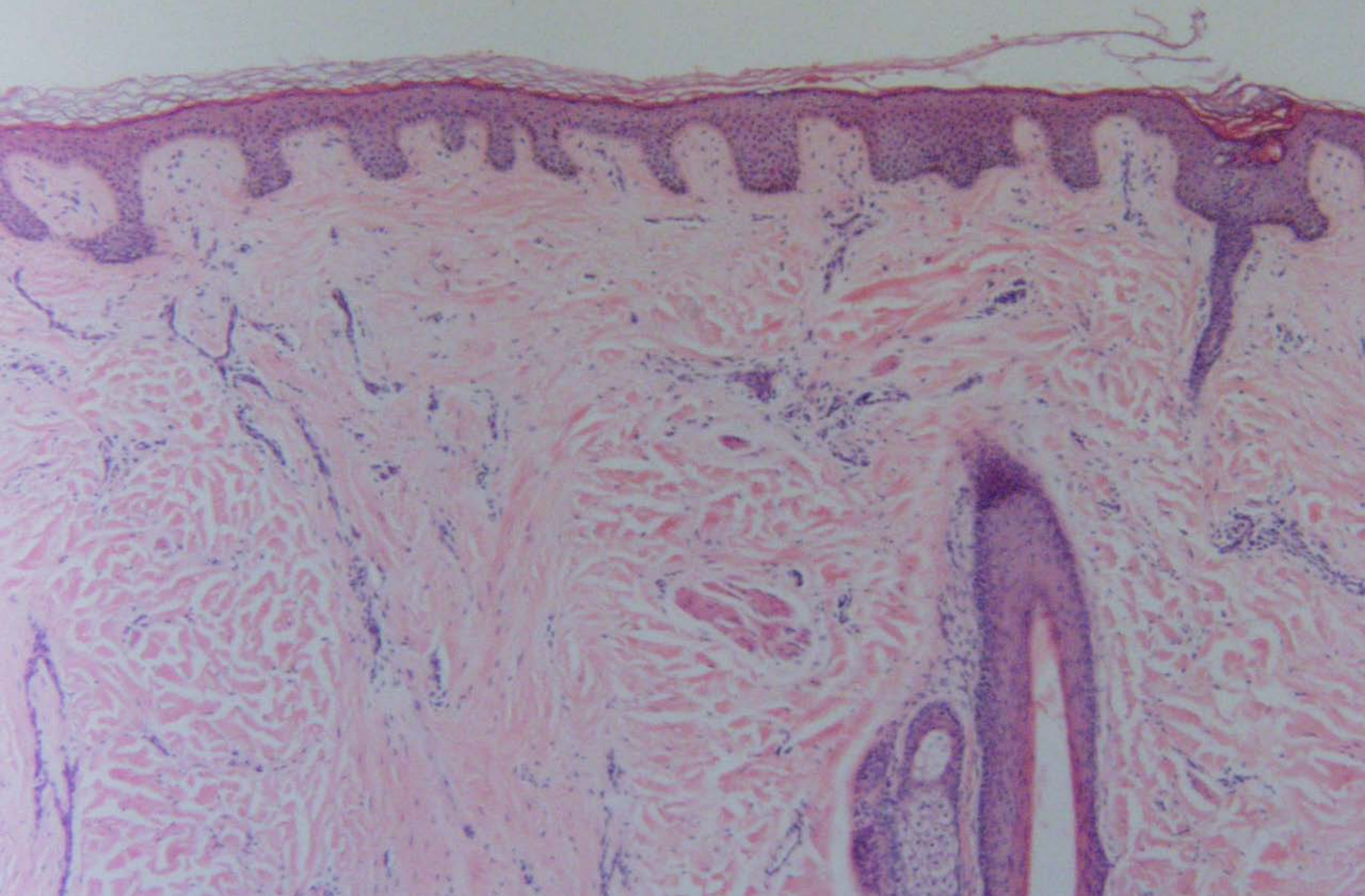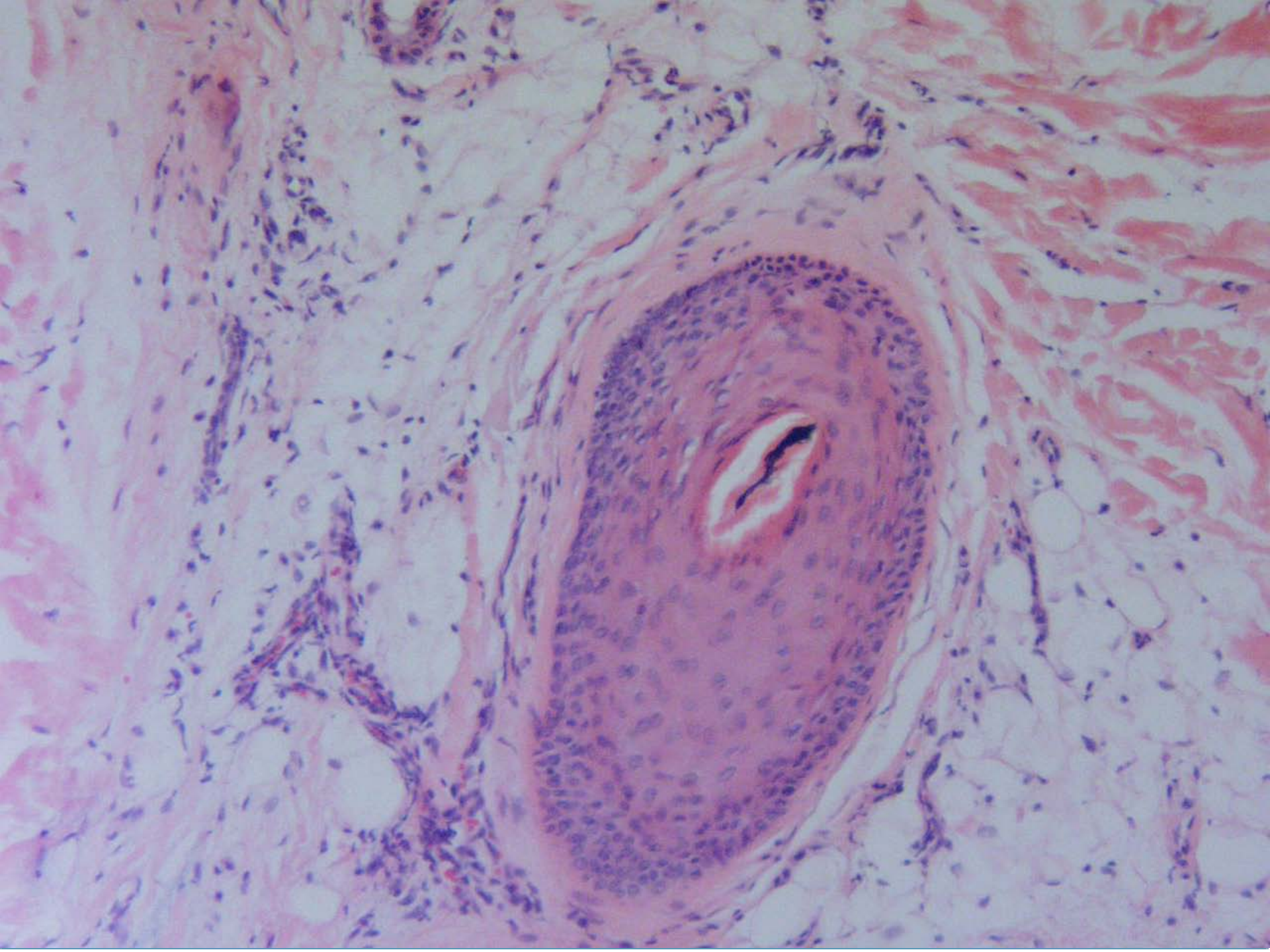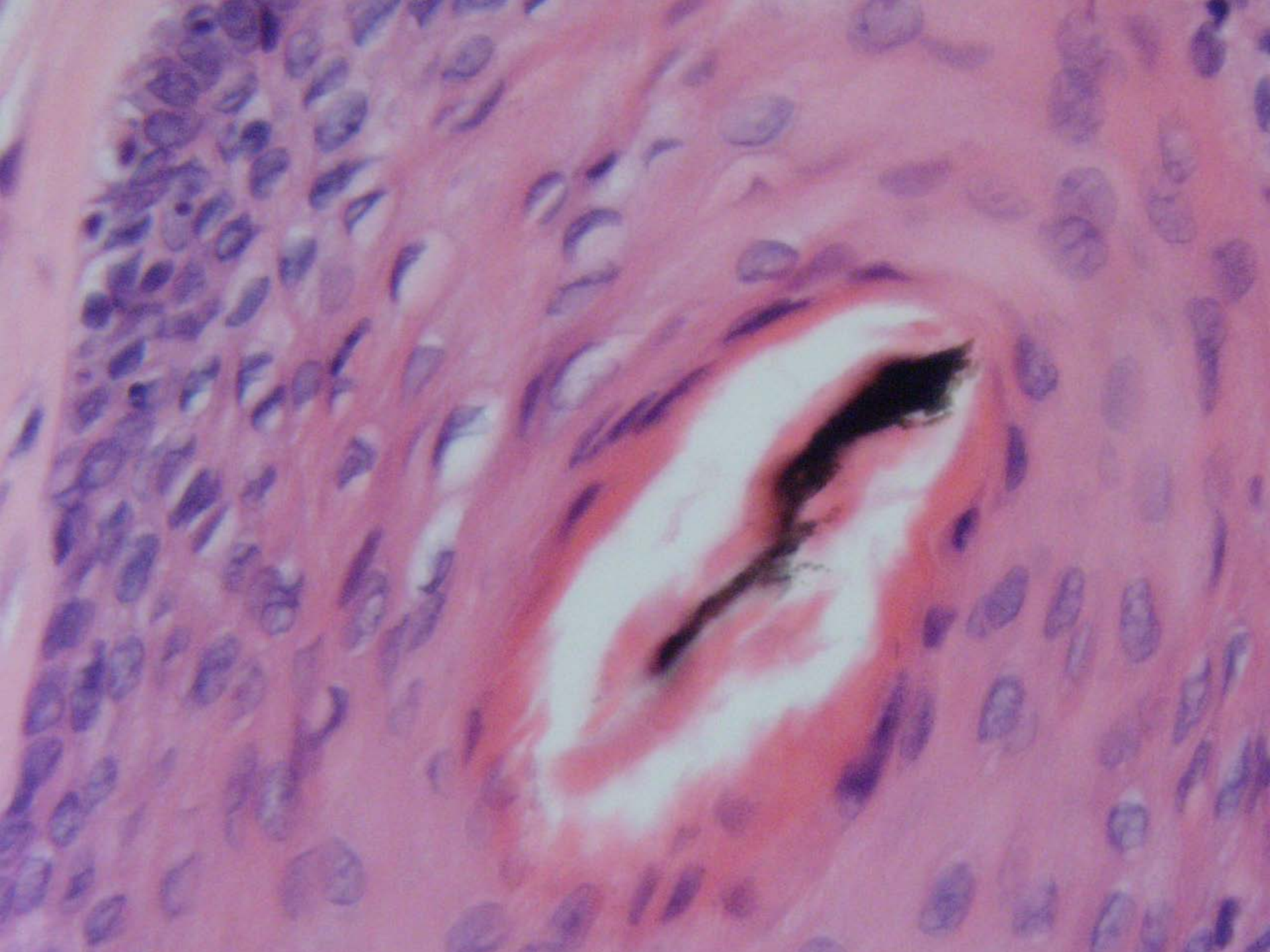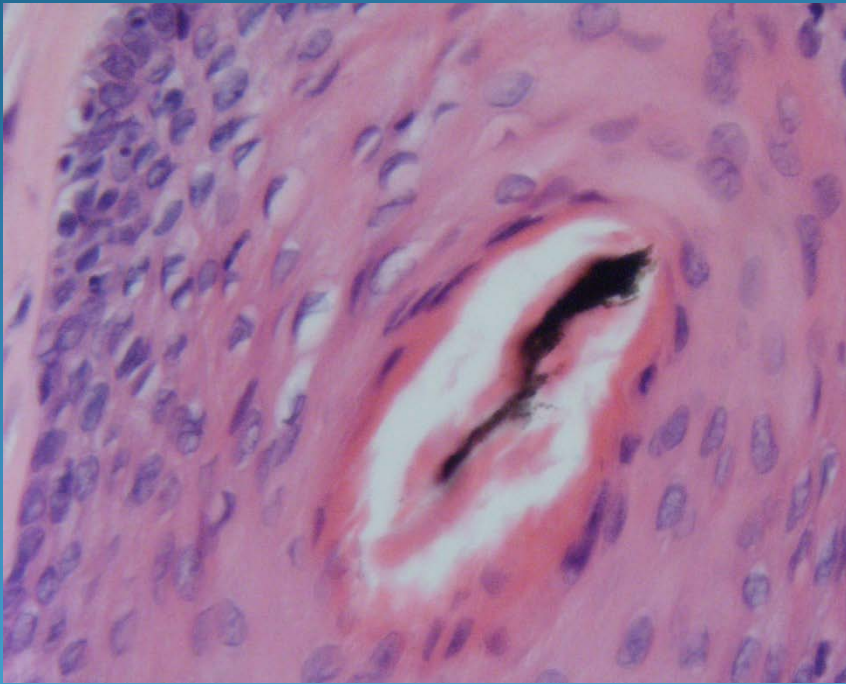


Trichotillomania/ Traction Alopecia

Pearls



- Melanin clumps/casts in the follicle are diagnostic
- Keratin plugs in the follicle
- Differentiate the clumps from normal streaks of pigment