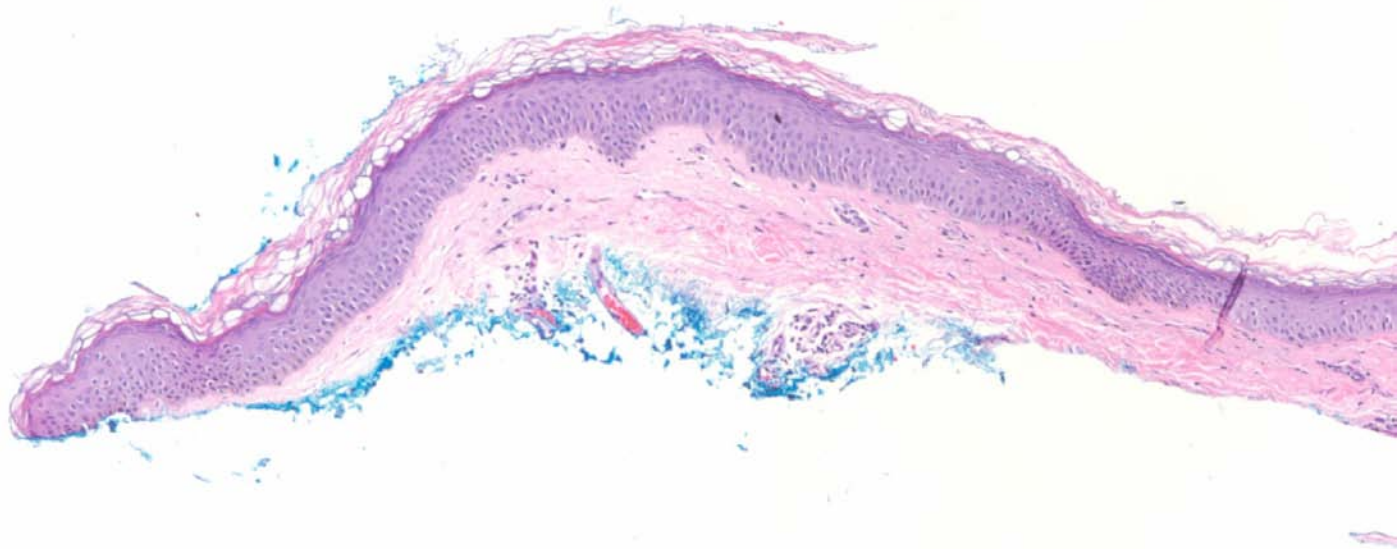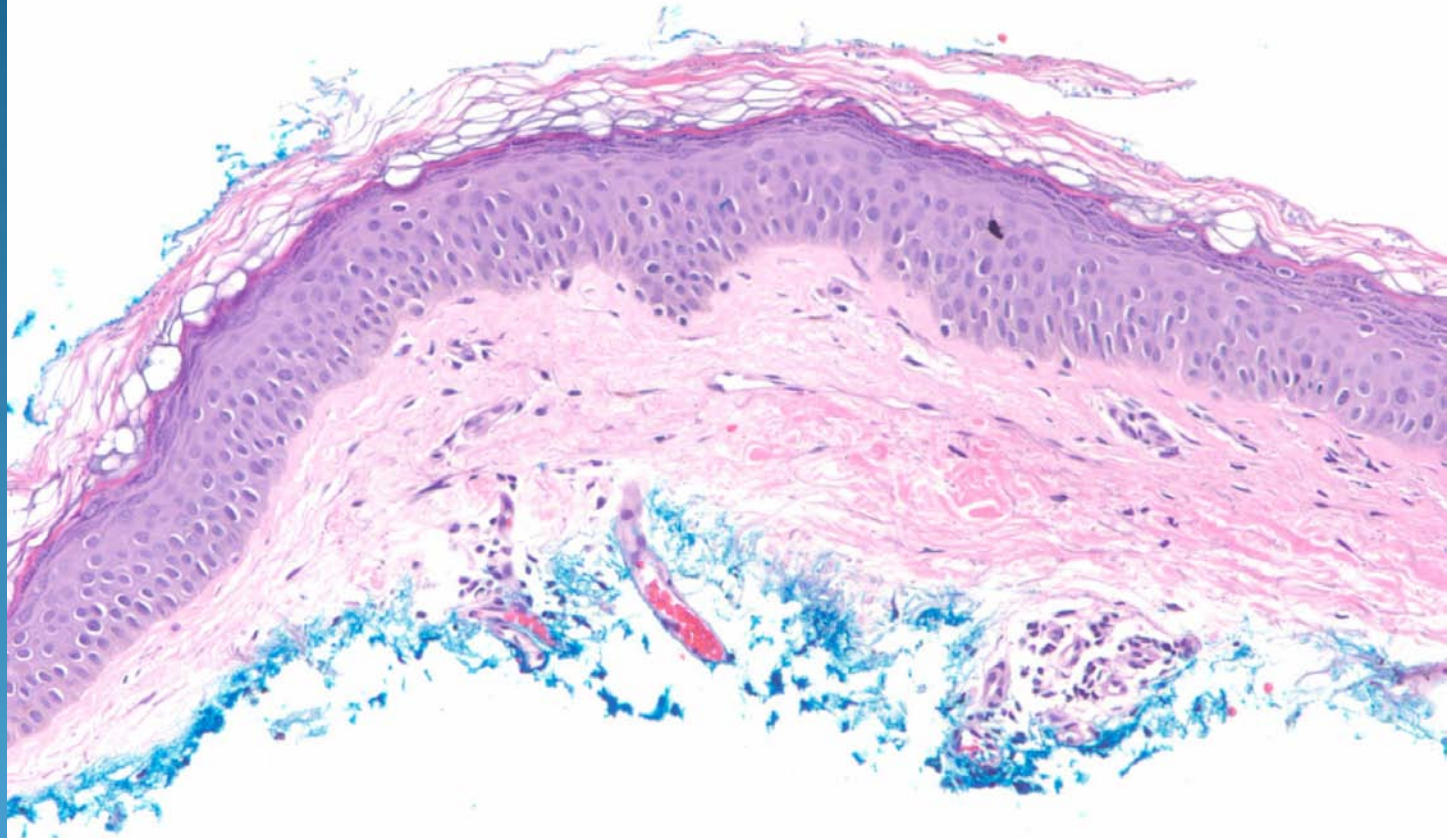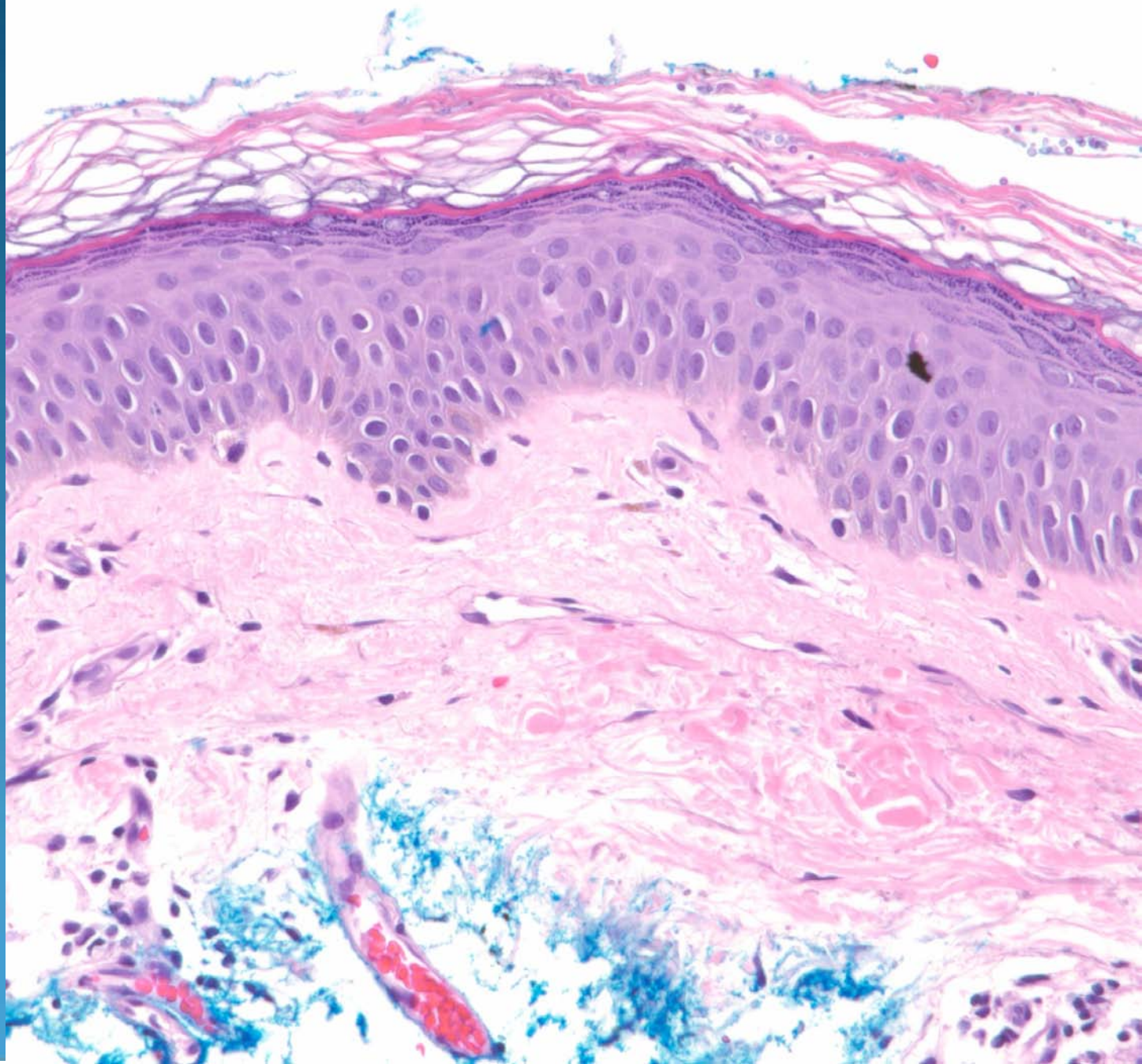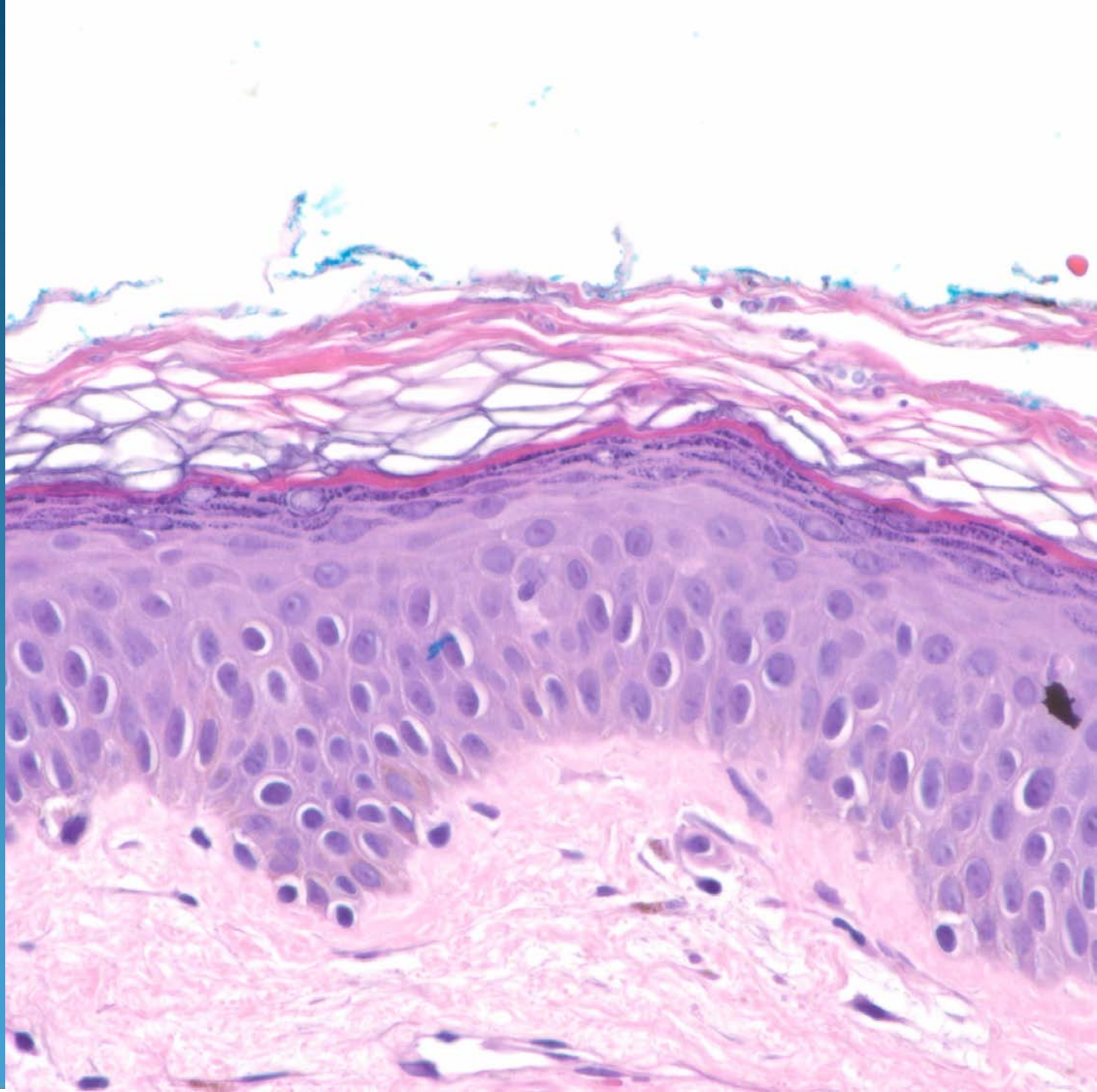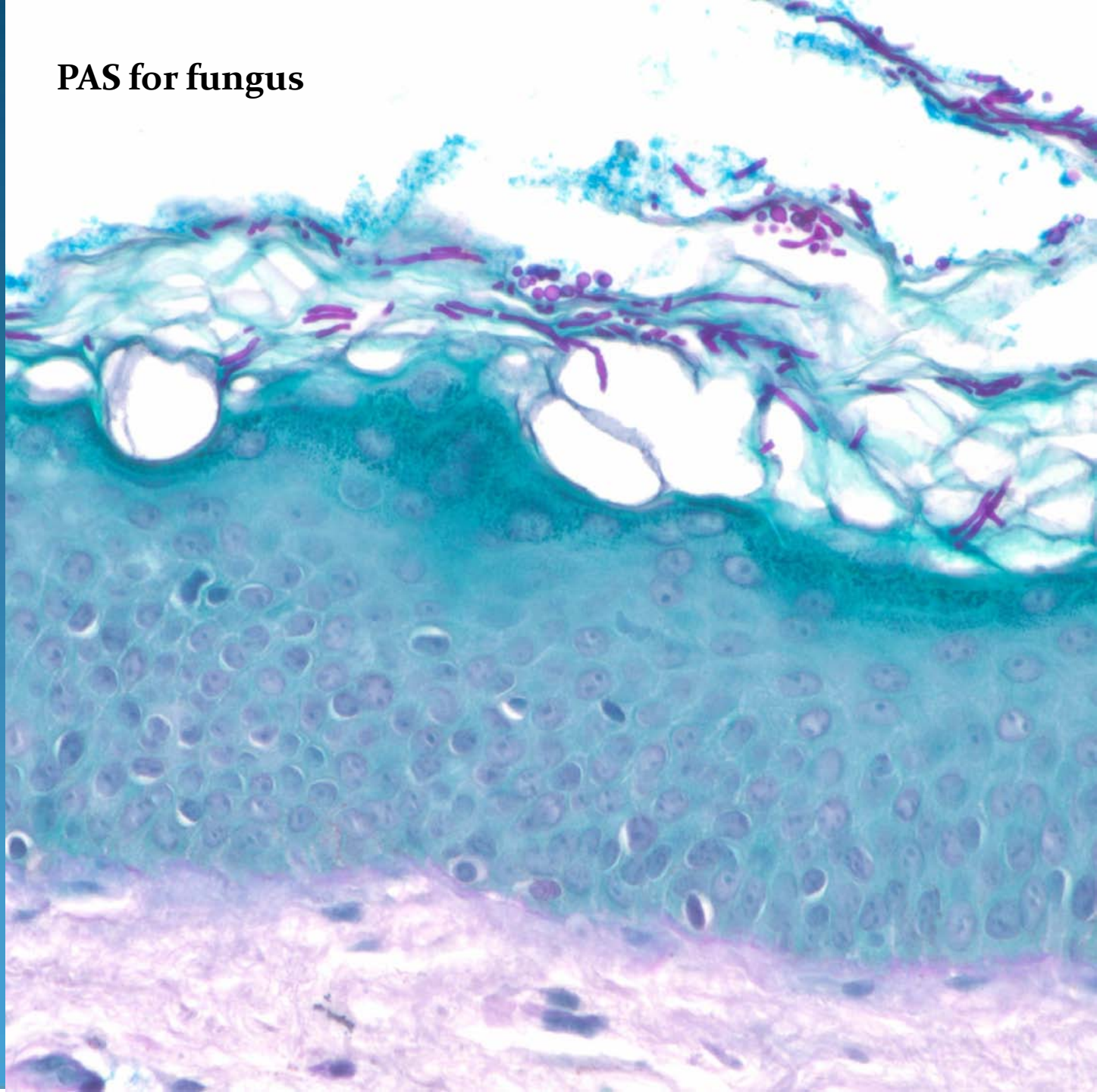
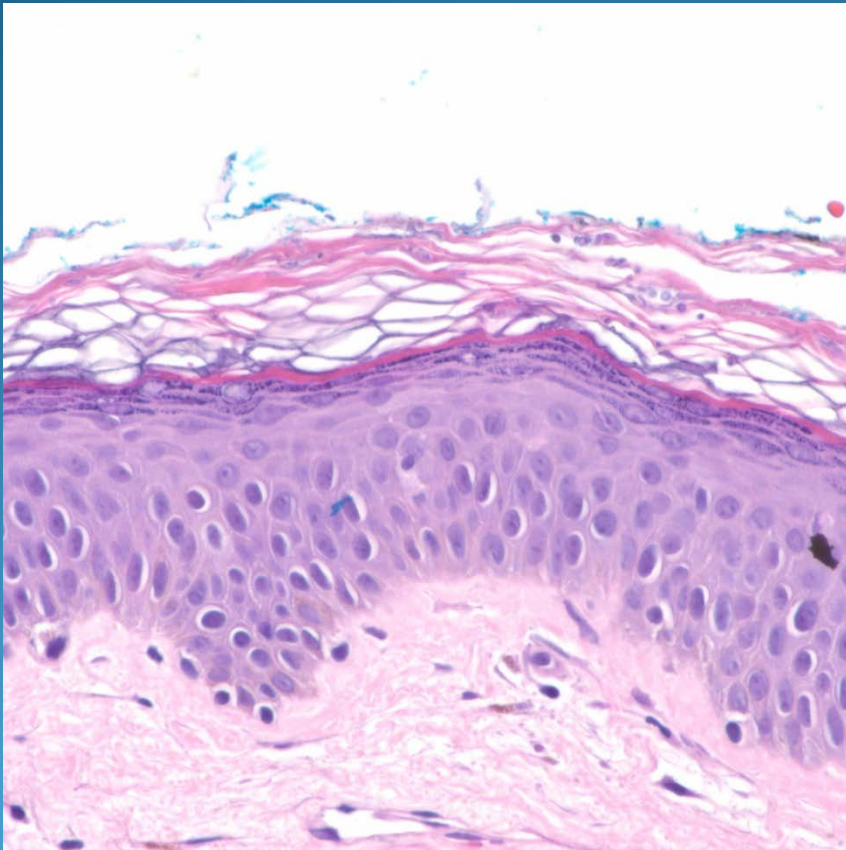


Tinea versicolor

PAS for fungus



Pearls



- Invisible dermatosis-may show minimal structural or inflammatory changes
- Look in stratum corneum for “spaghetti and meatballs” of fungus
- Confirm with PAS-fungus or GMS stains