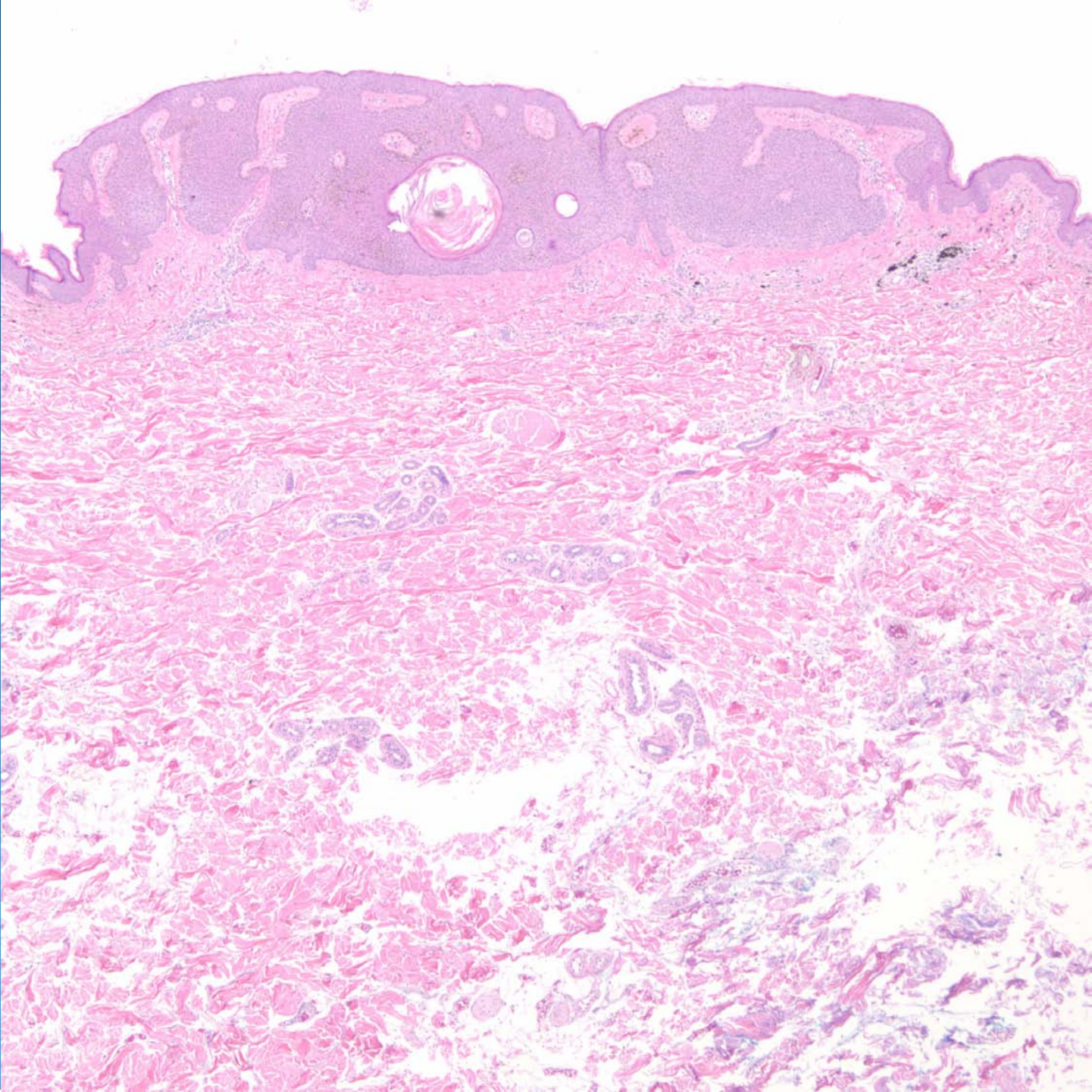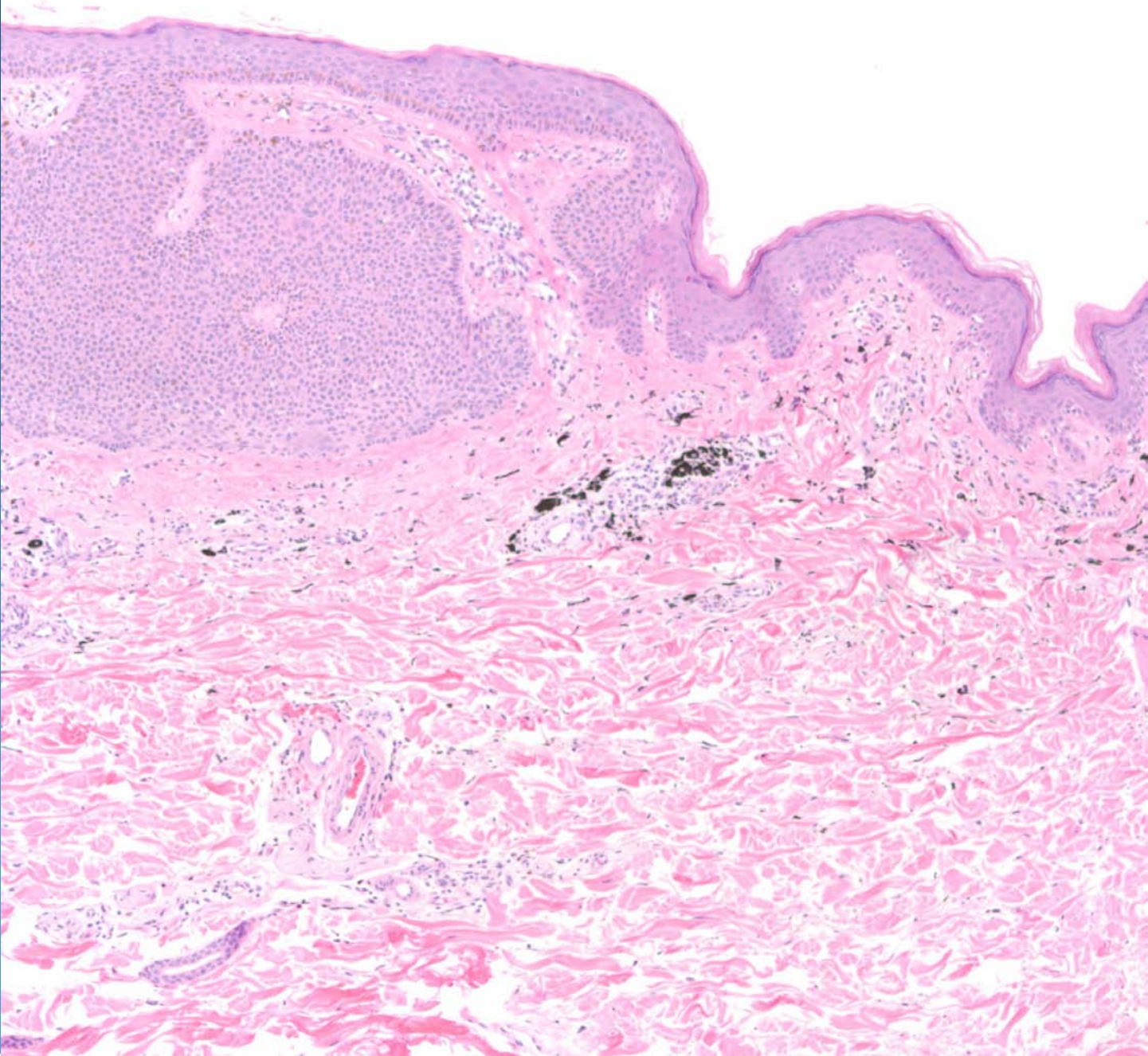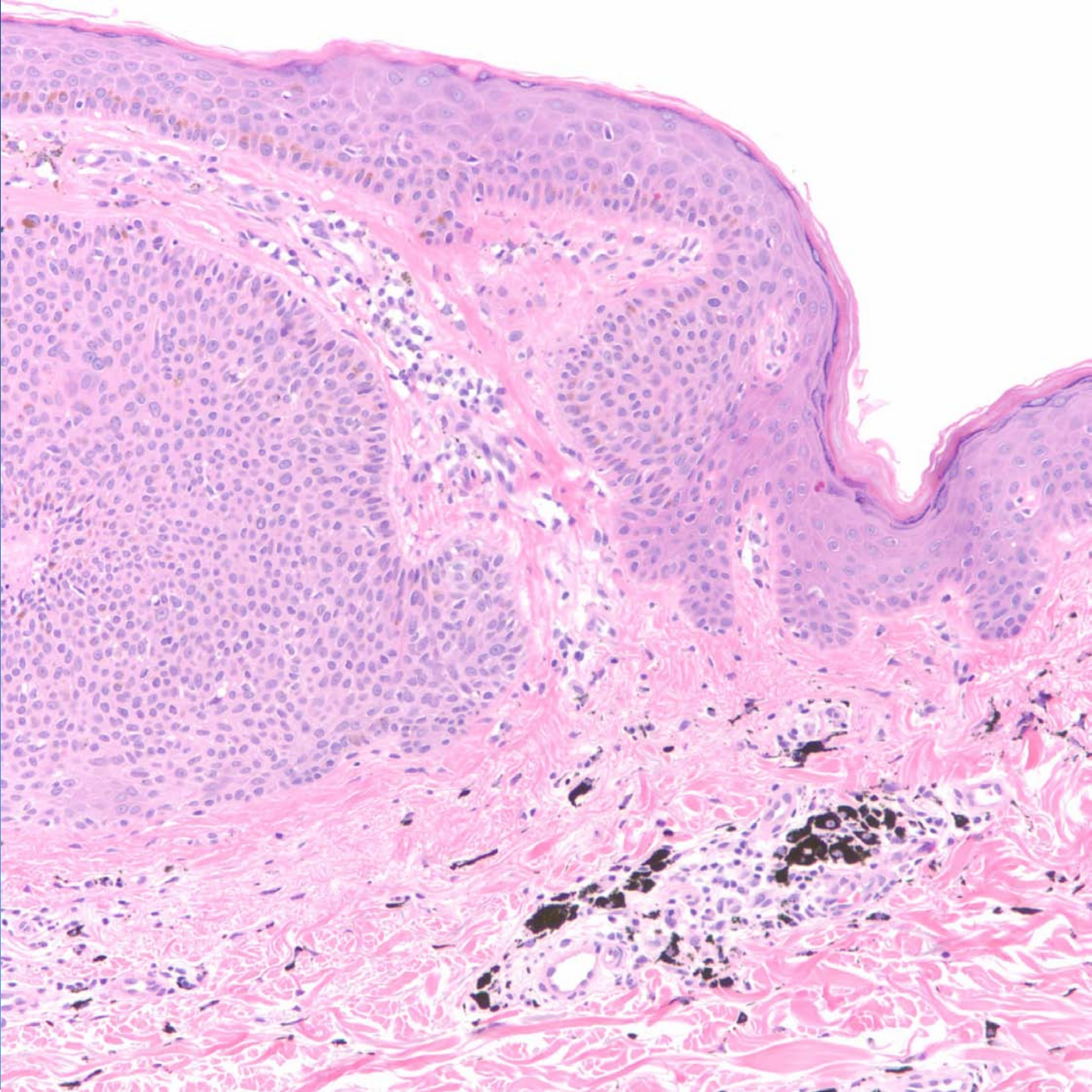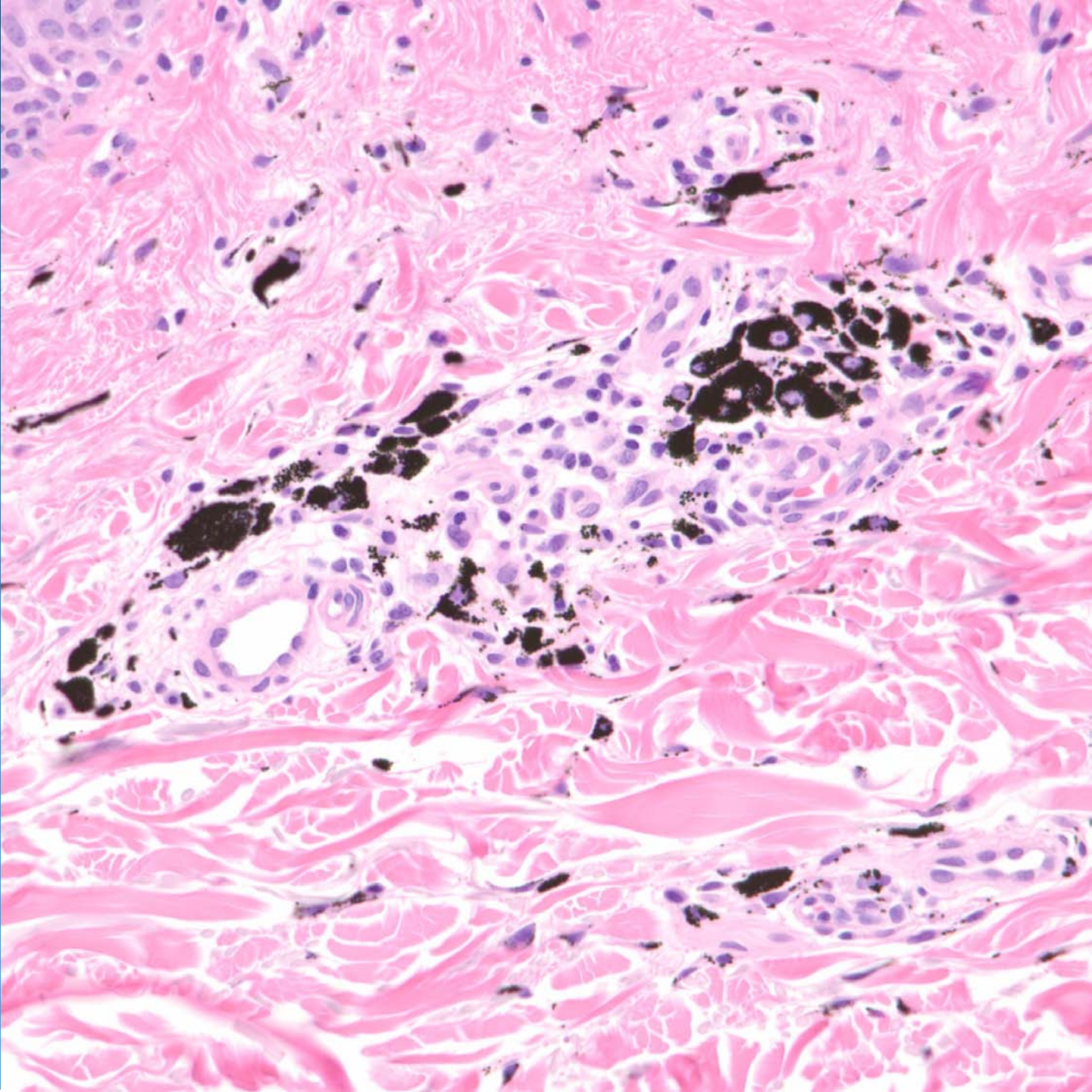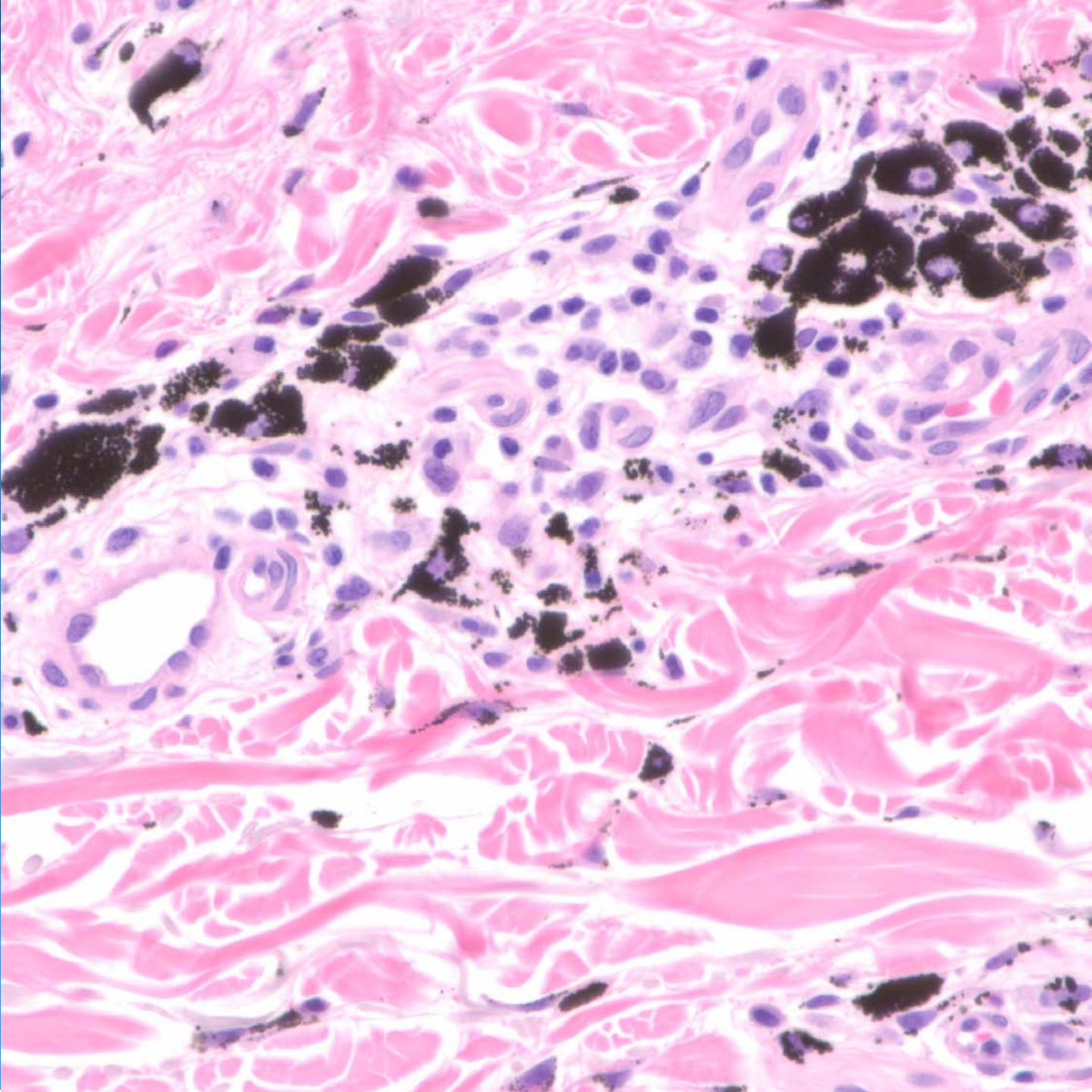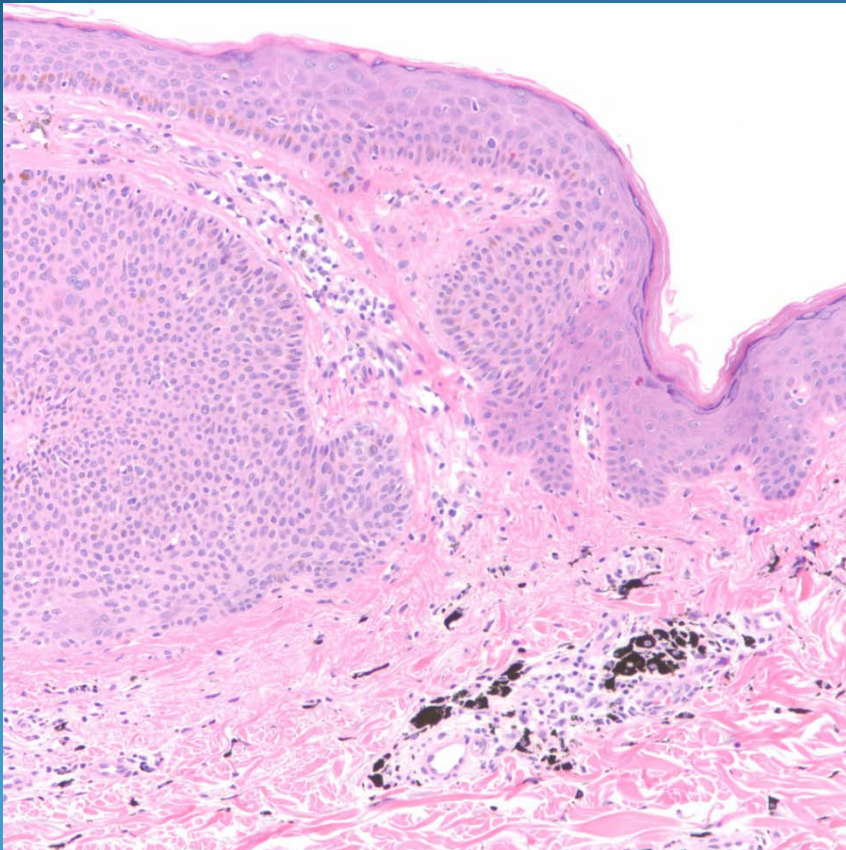


# What is the best diagnosis?

- A. Blue nevus
- B. Mongolian spot
- C. Tattoo
- D. Desmoplastic melanoma
- E. Combined melanocytic nevus

Tattoo arising with a seborrheic  
keratosis

# Pearls



- Tattoo pigment identified by coarse granules both intra-and extra-cellular
- Occasionally other tissue reactions including granulomas, foreign body giant cells
- Rarely epithelial proliferations may be associated-may be coincidental