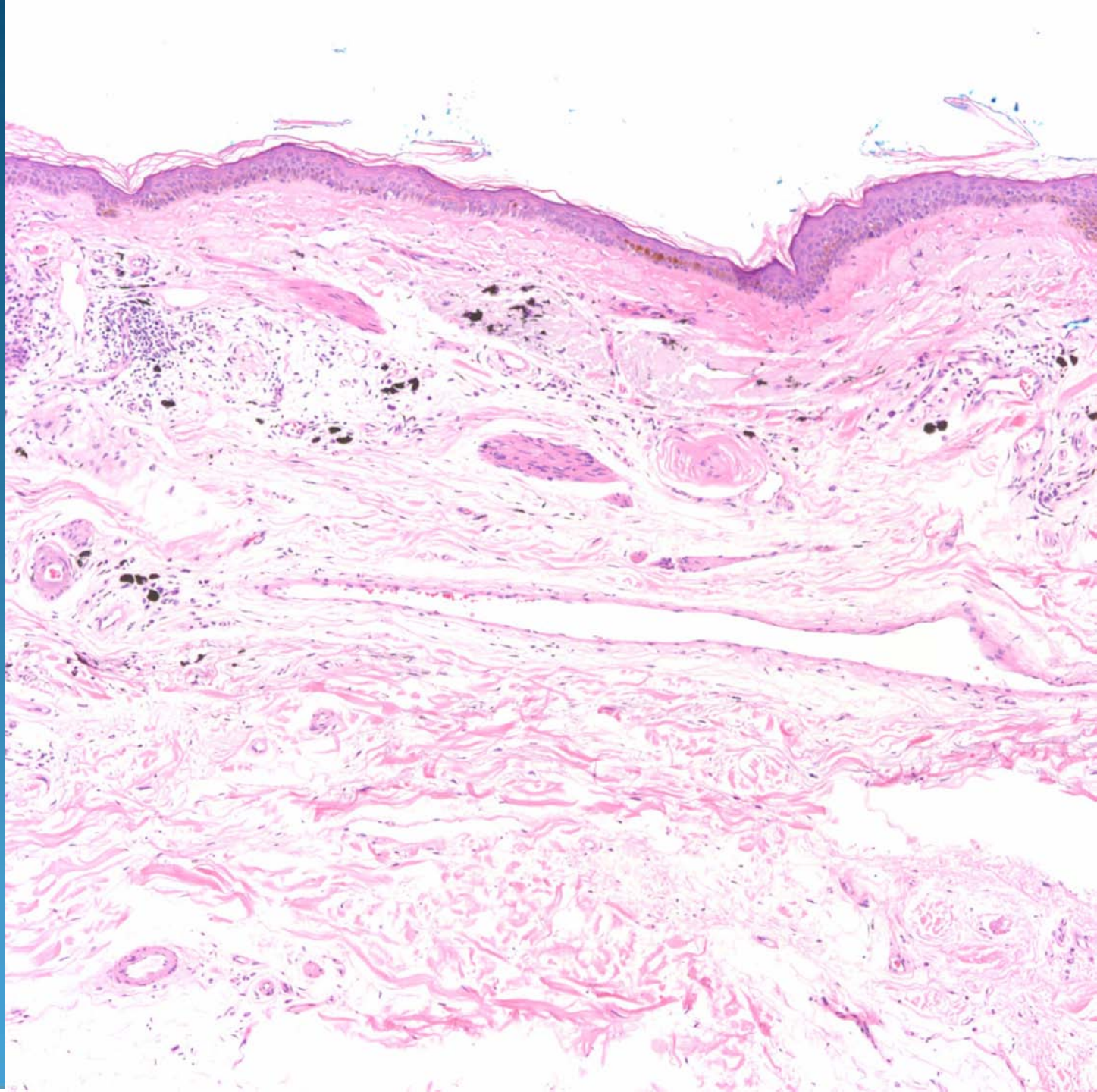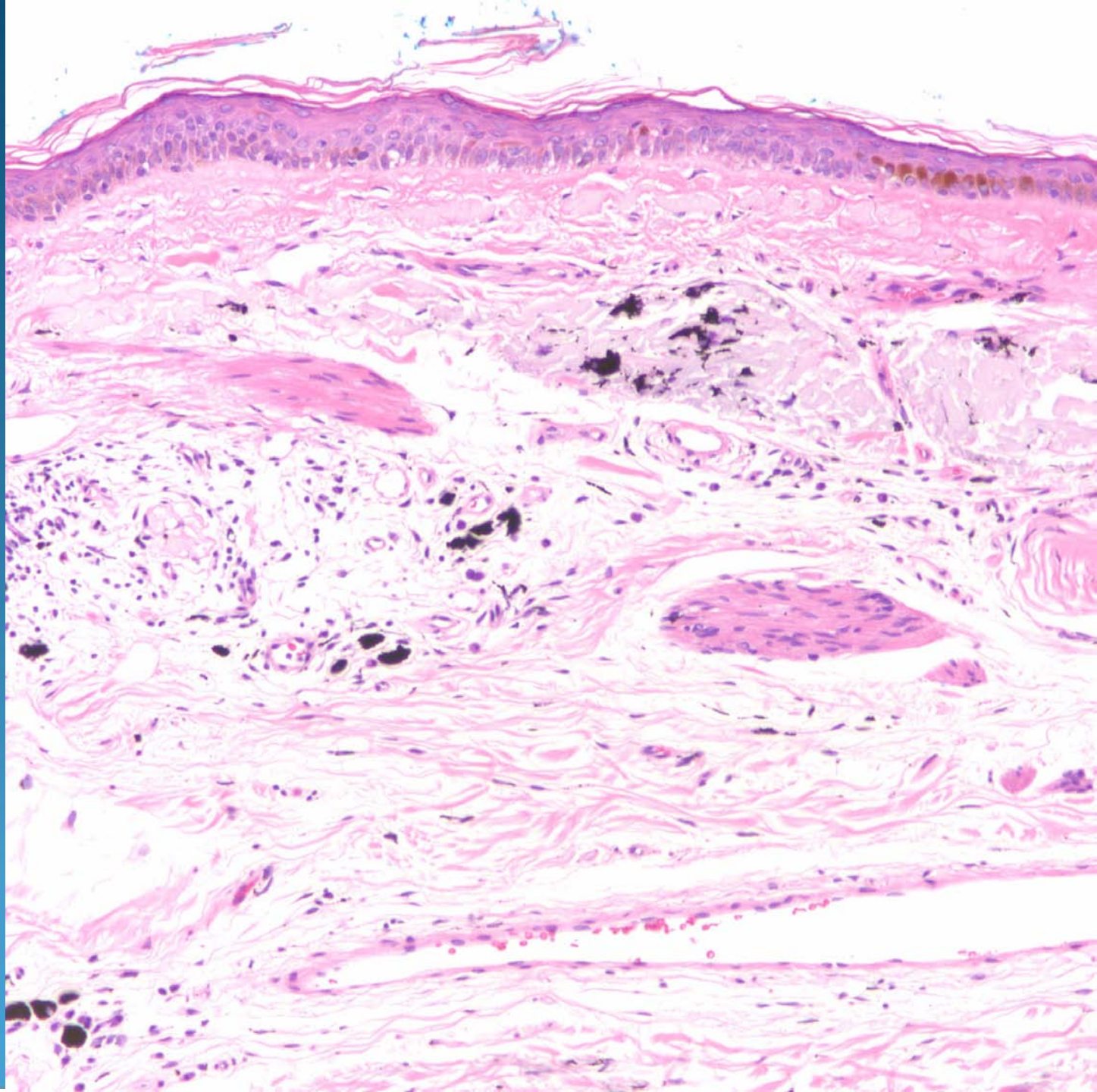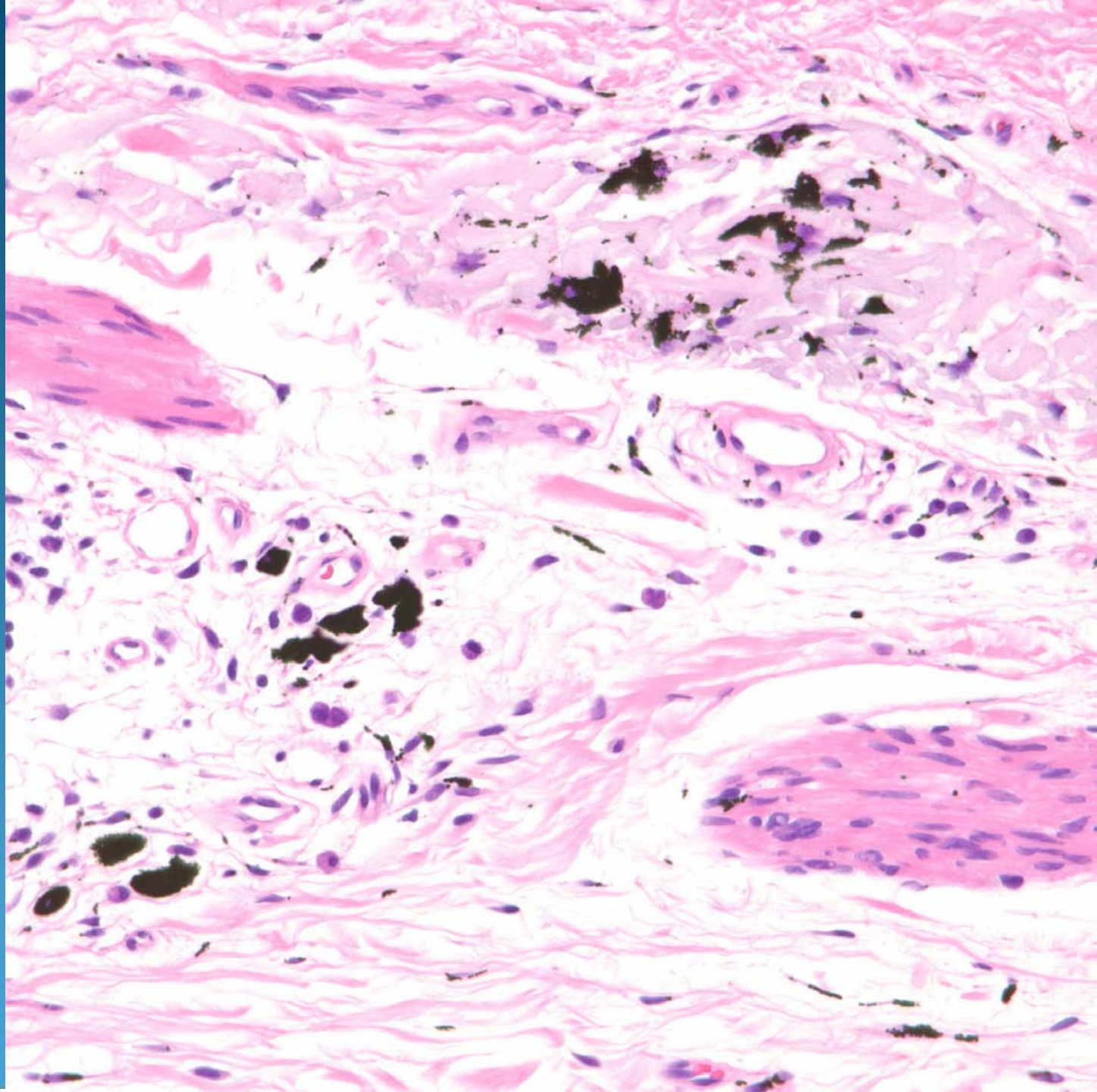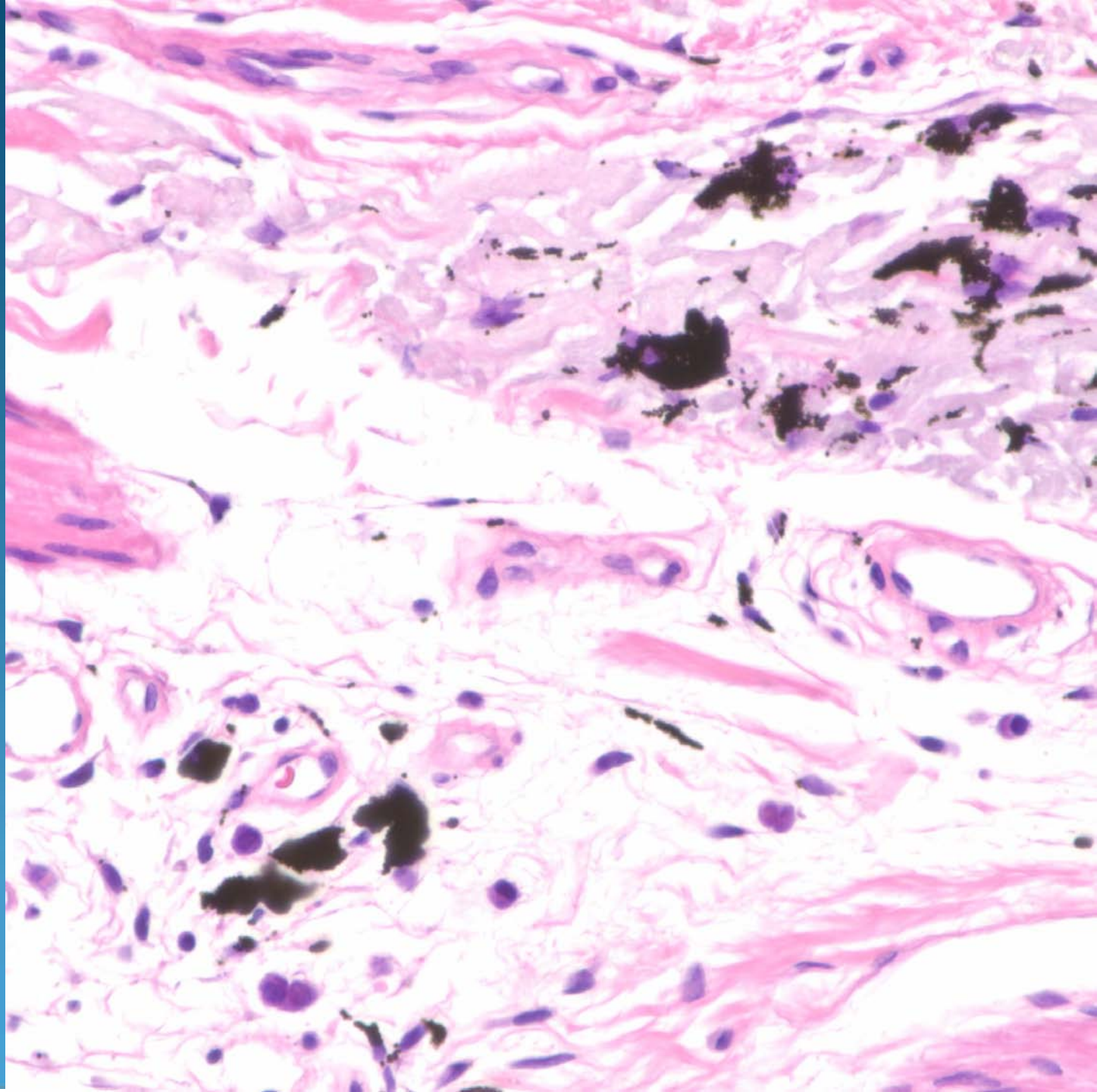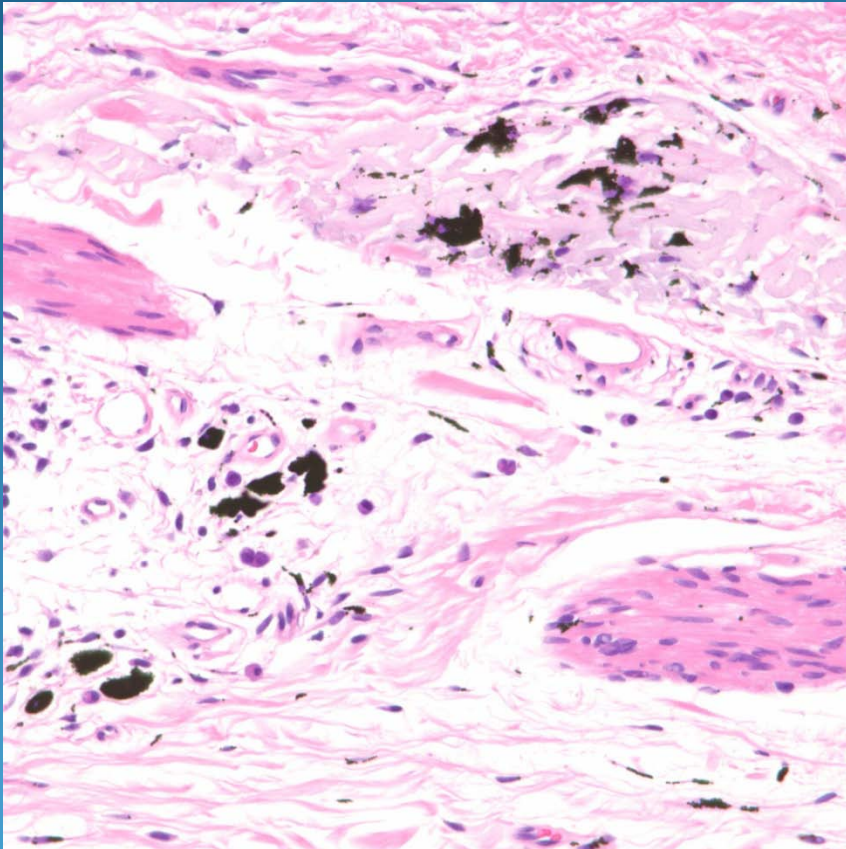


Tattoo

Pearls



- Pigment in histiocytes and dermis
- Color dependent upon pigment utilized
- May have granulomatous reaction, including sarcoidal granulomas
- DDX: Nevus of Ota/Ito, Mongolian Spot, Blue nevus