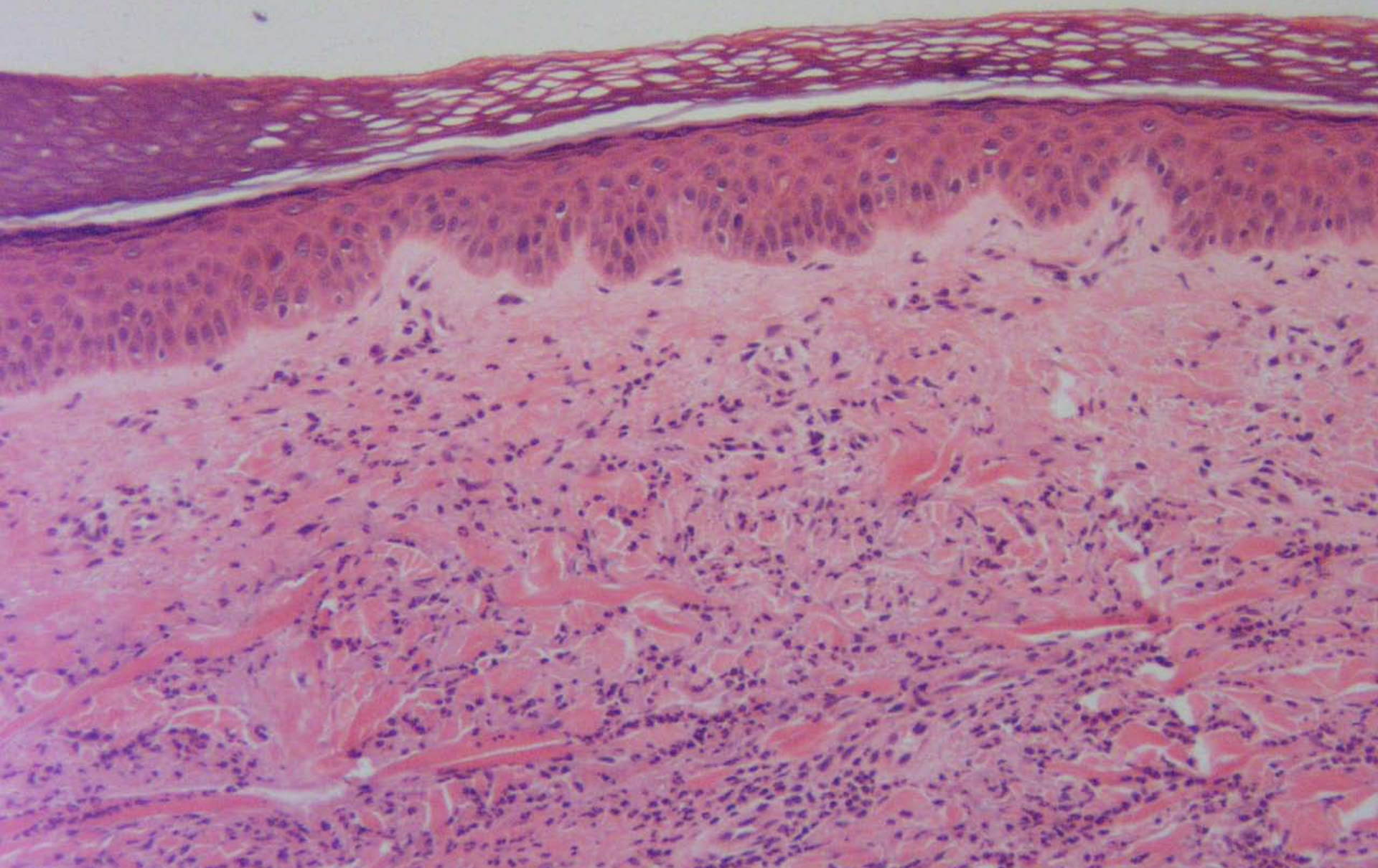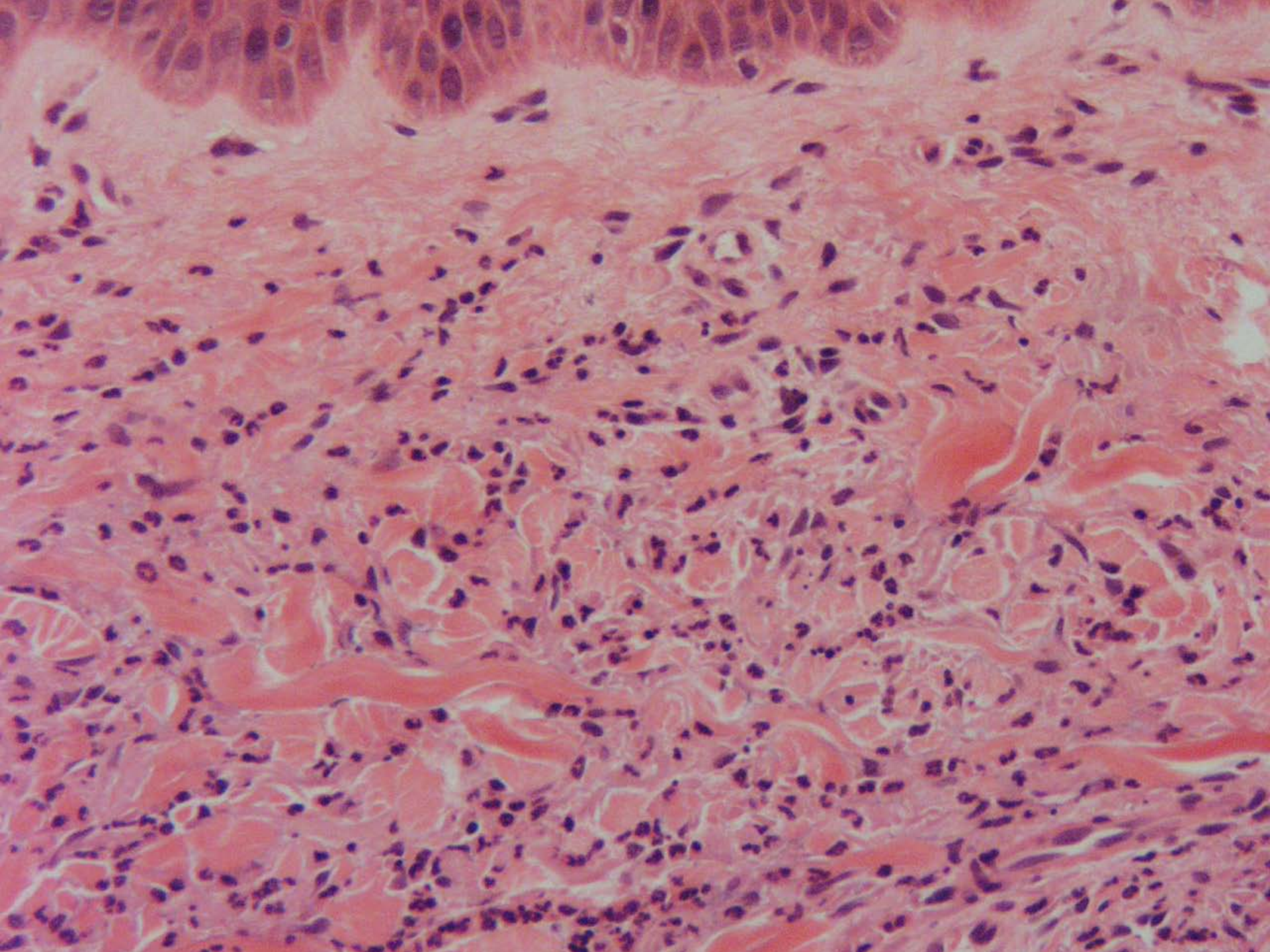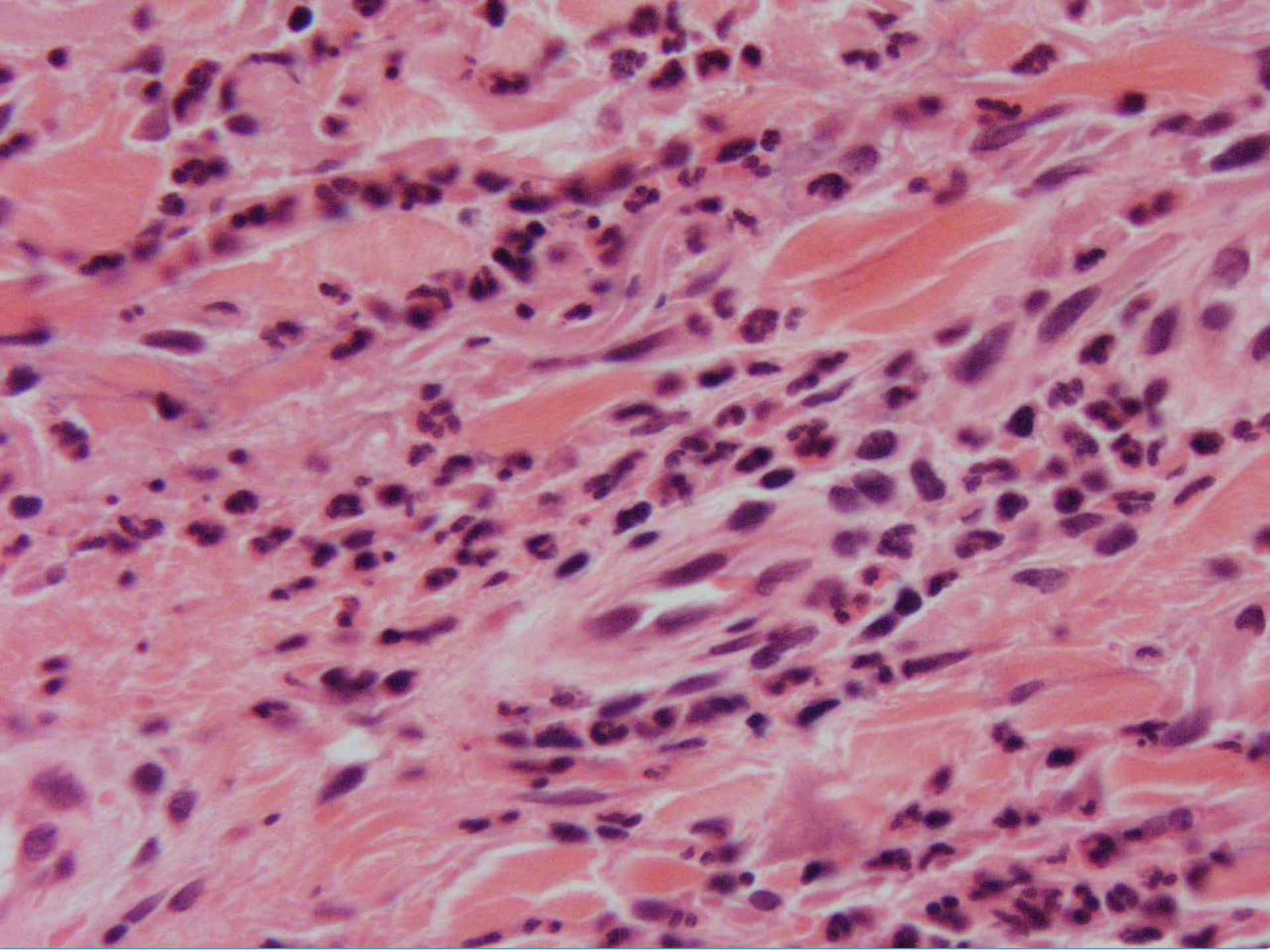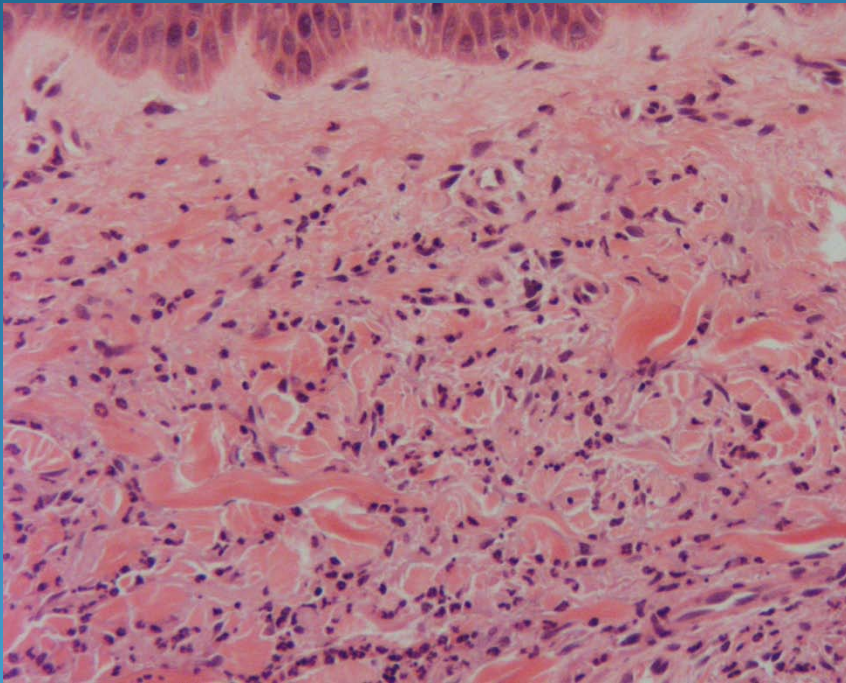


# Sweet's Syndrome

# Pearls



- Upper dermal edema (pseudo-bullae)
- Nuclear debris > intact neutrophils
- No vasculitis, not angiocentric, but diffuse