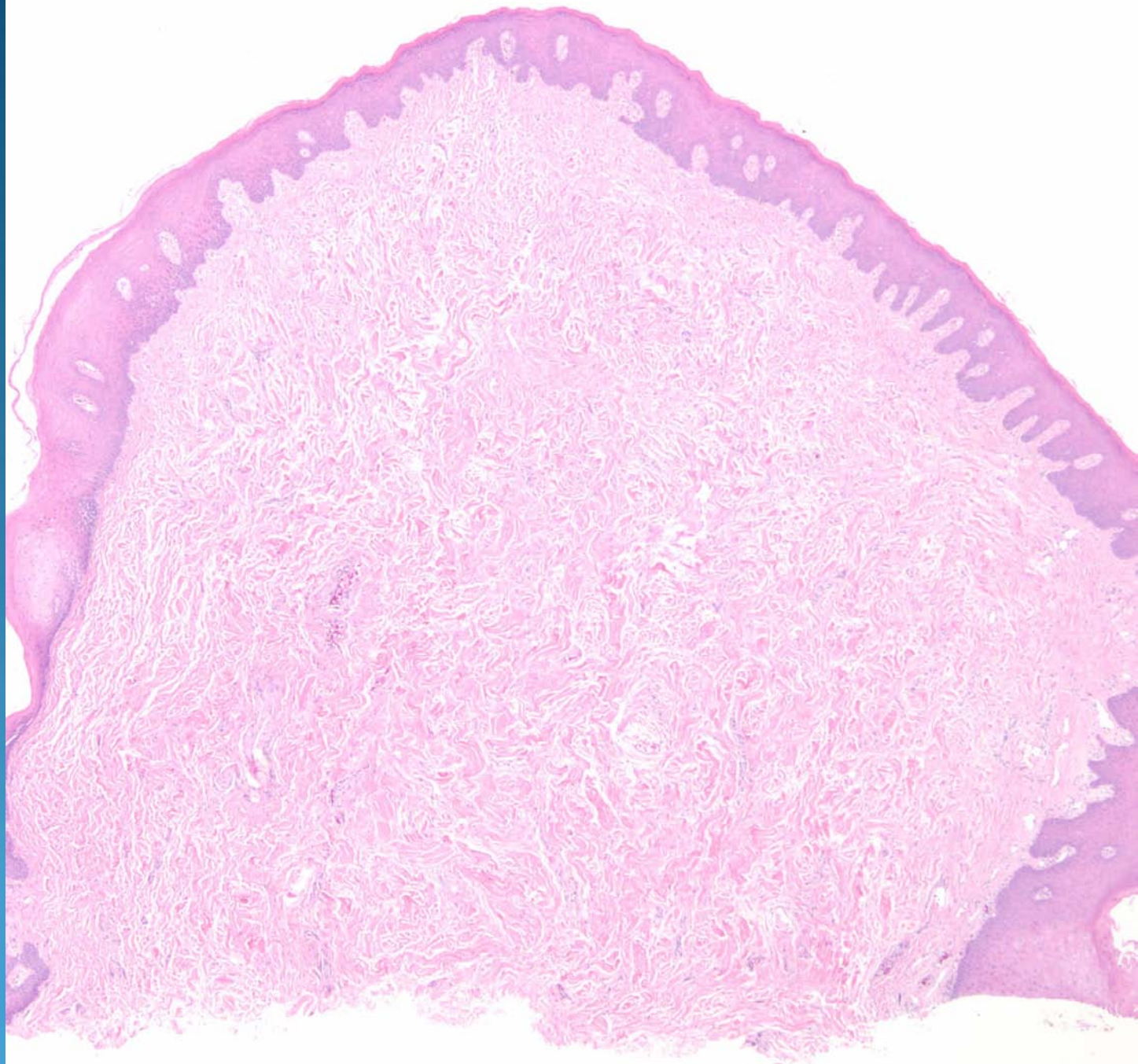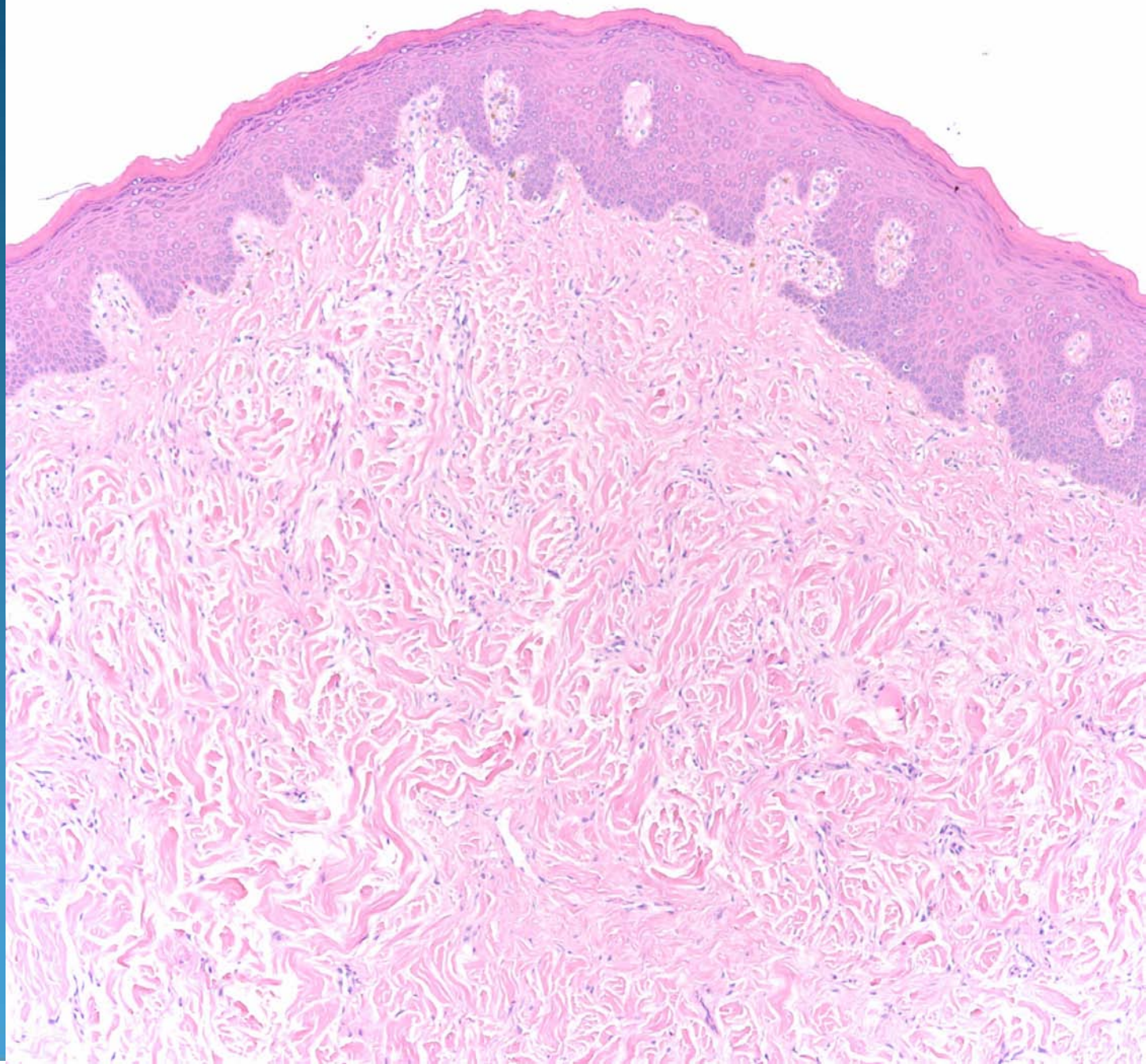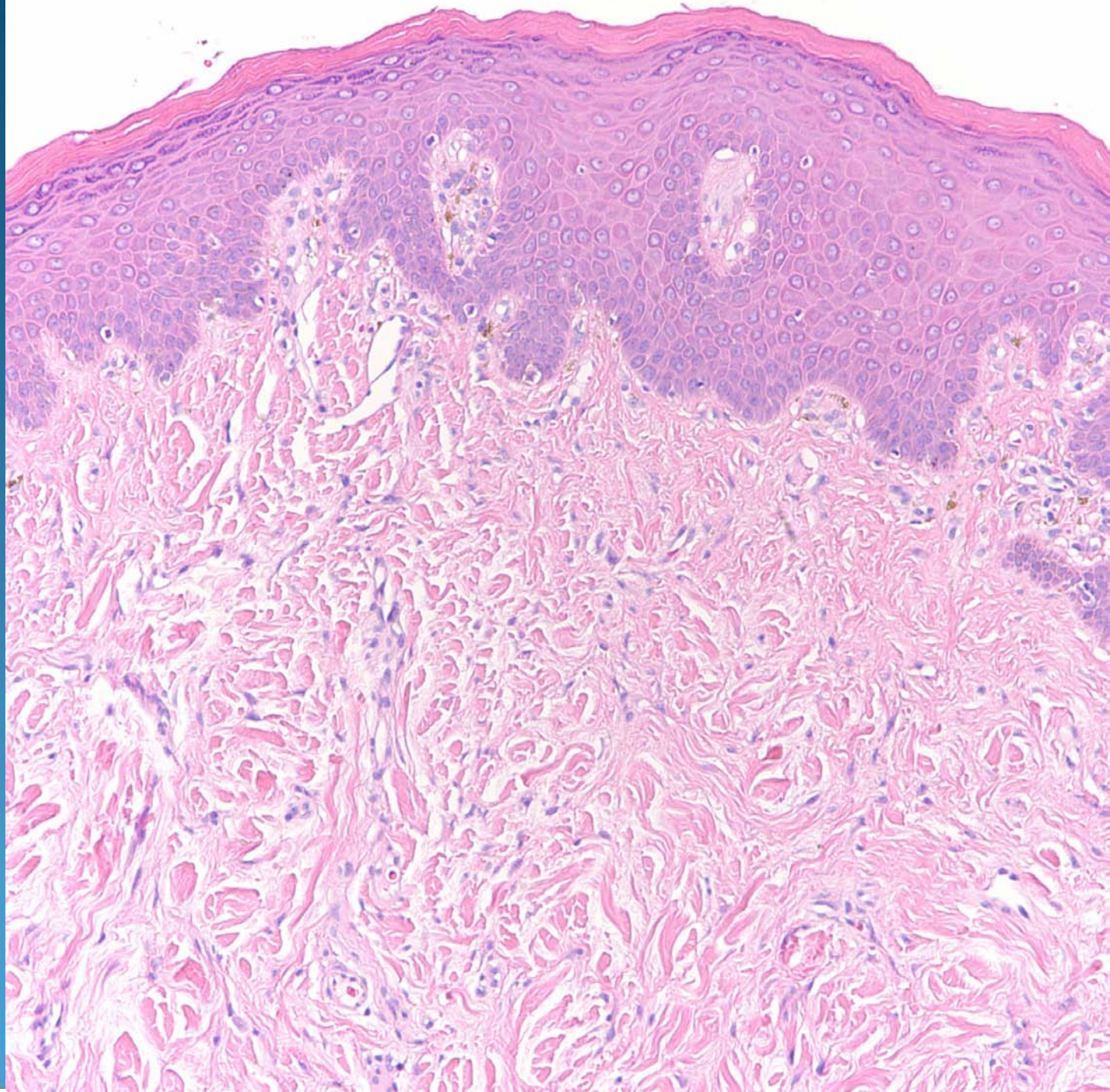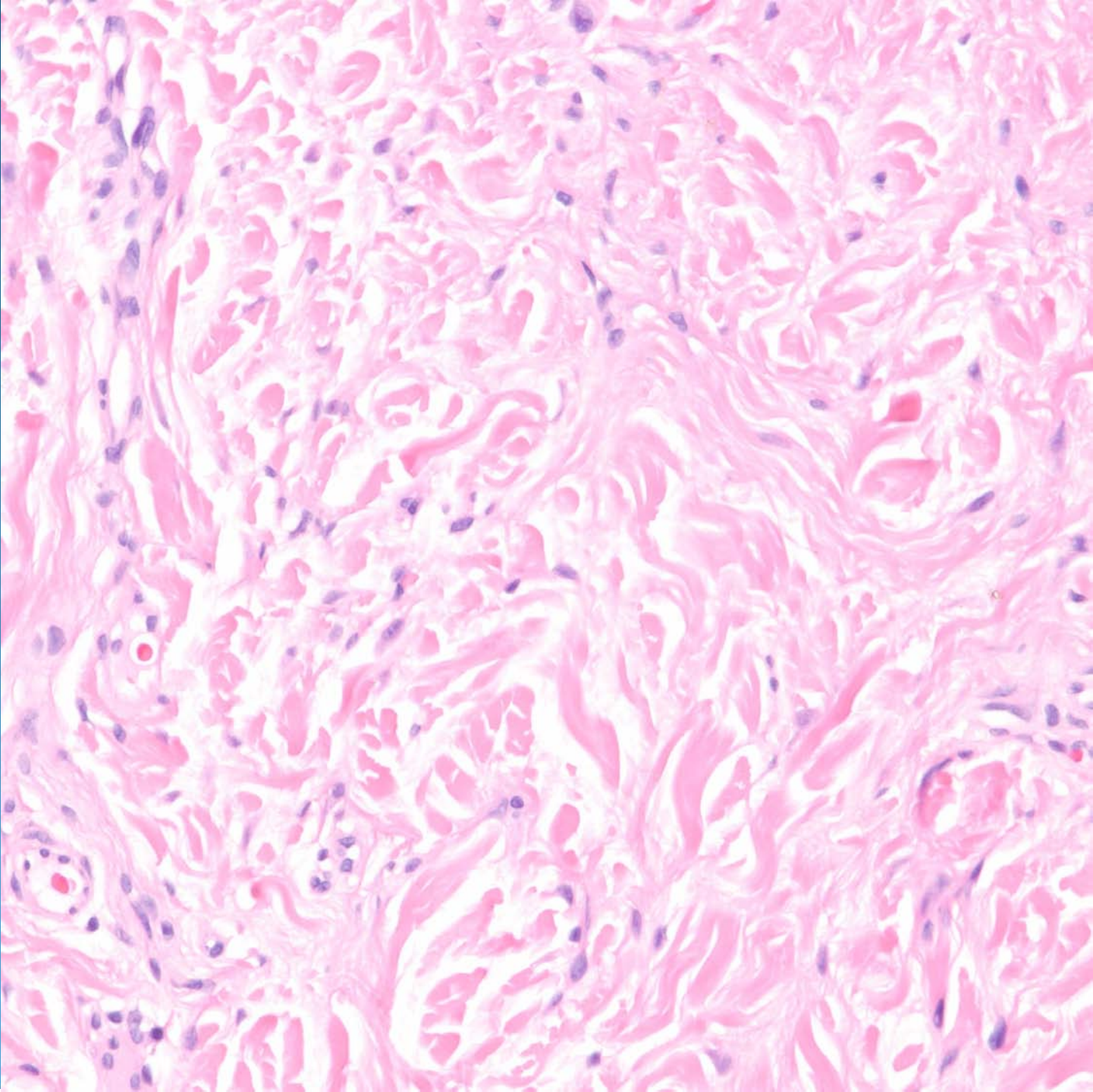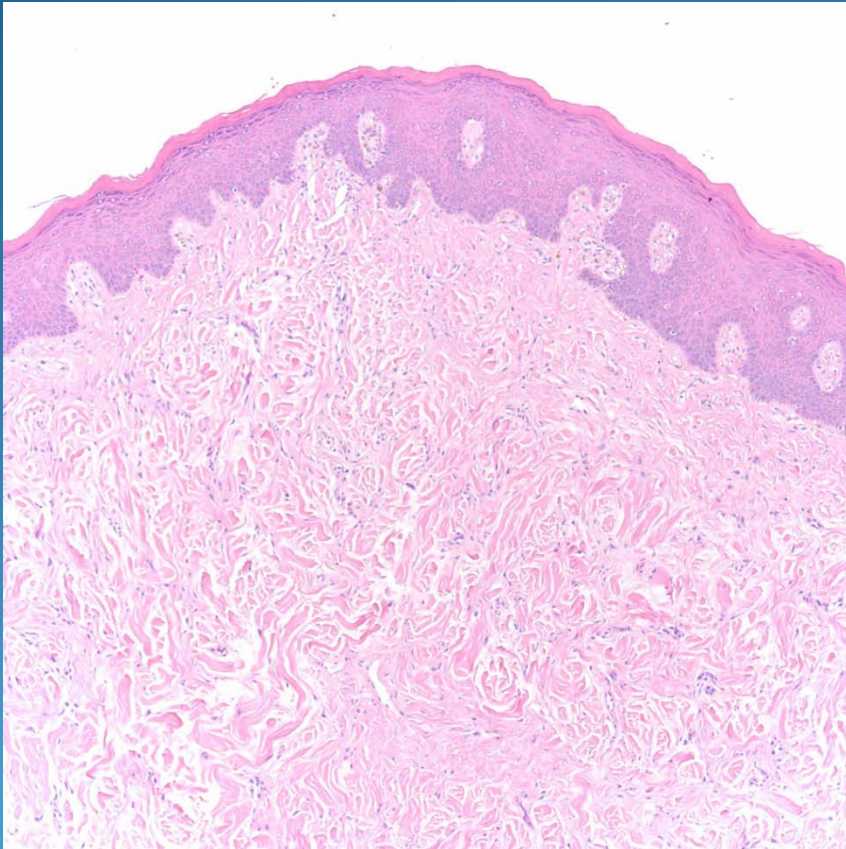


Submucosal Fibroma of the Oral Cavity

Pearls



- Recognize non-keratinizing oral mucosa
- Dome shaped nodule
- Variable mucosal thickness
- Proliferation of bland fibroblasts within submucosa
- DDX: Hypopigmented blue nevus