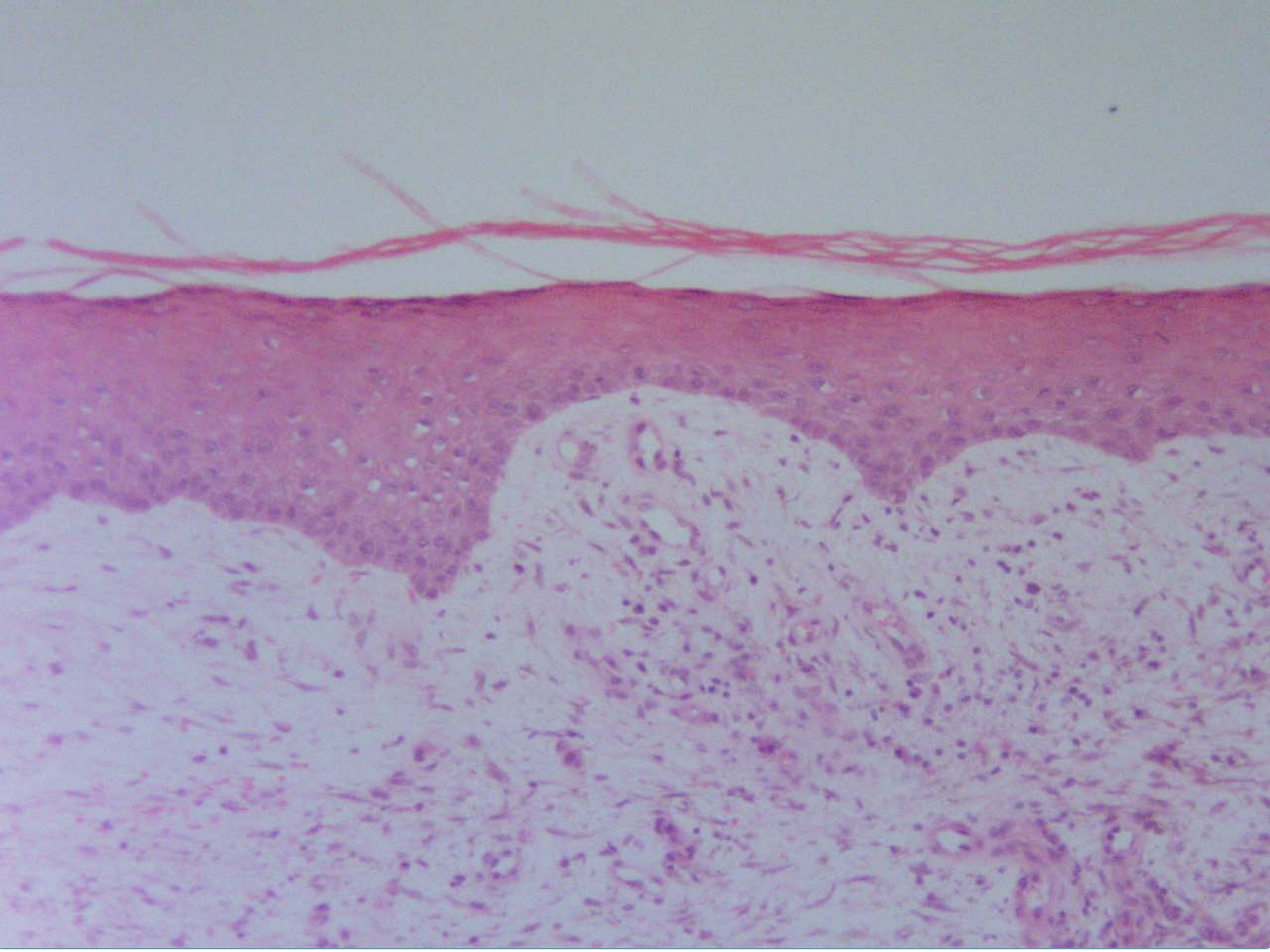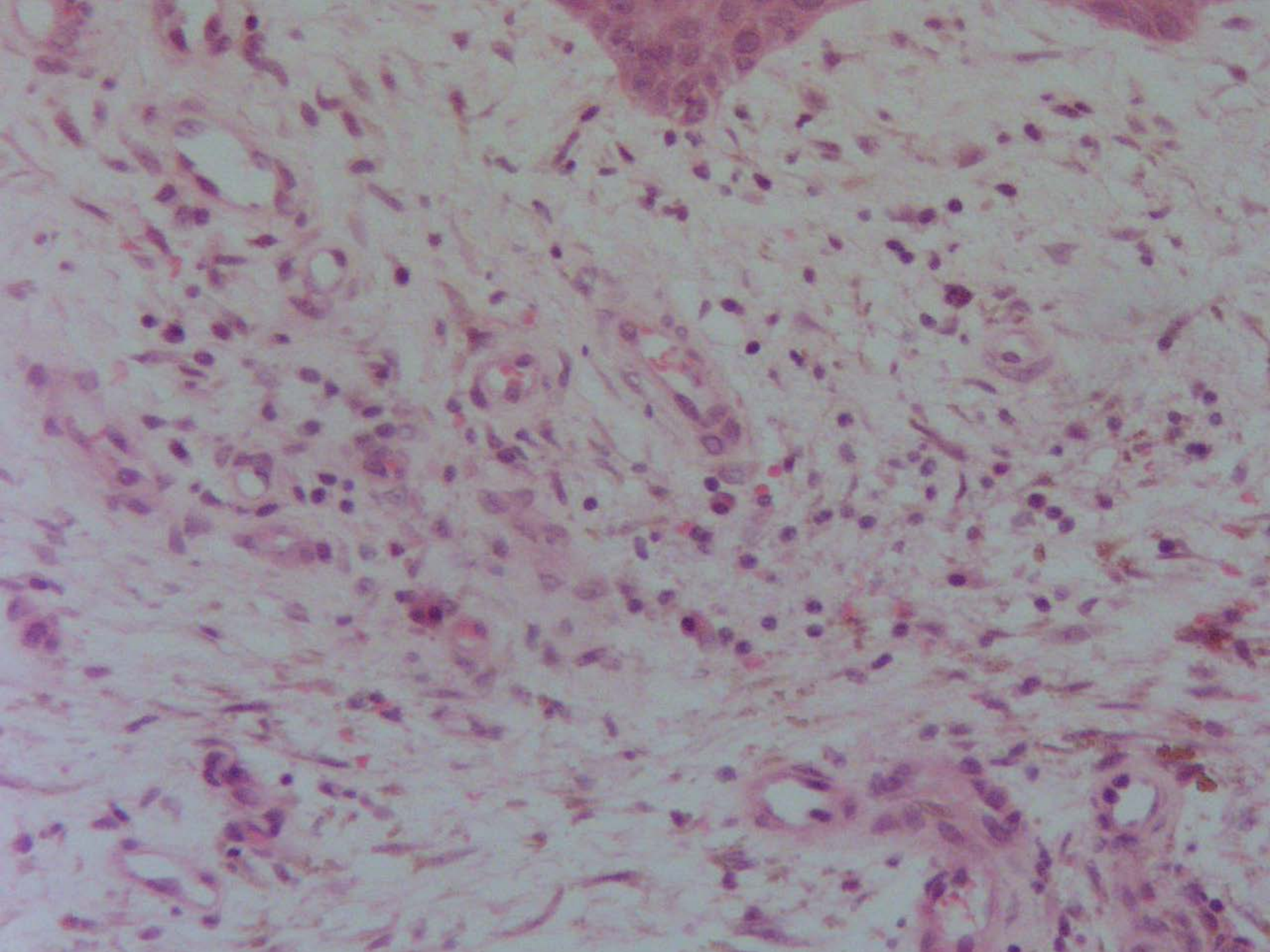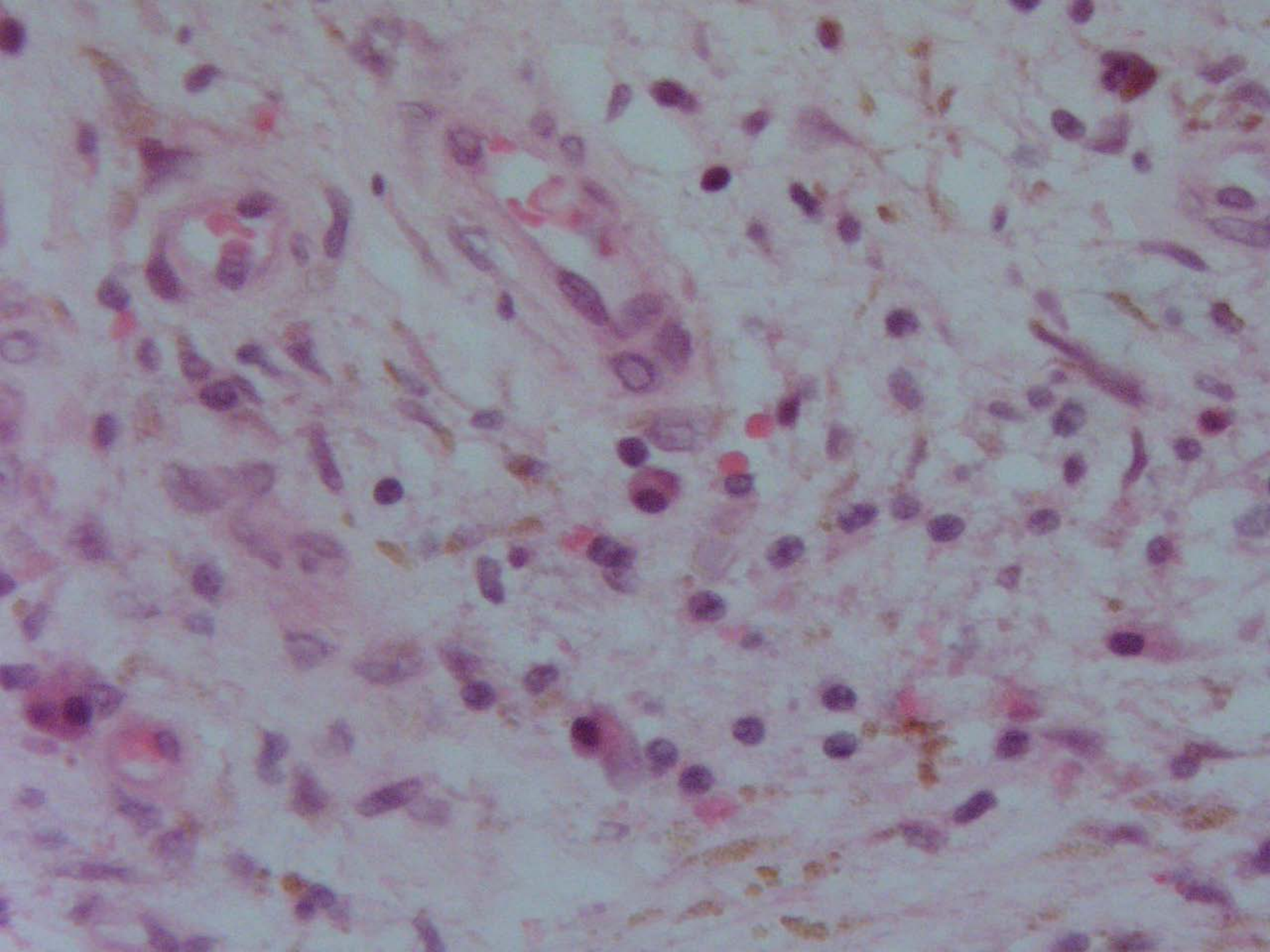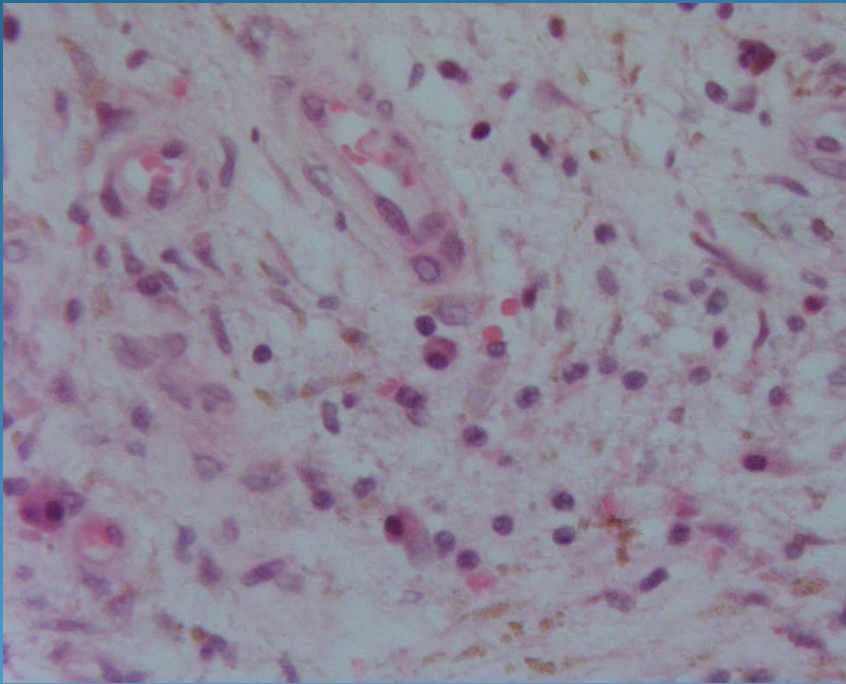


# Stasis Dermatitis

# Pearls



- Proliferation of round, thick walled vessels
- Always hemosiderin with extravasated rbc's
- Spongiosis and scale