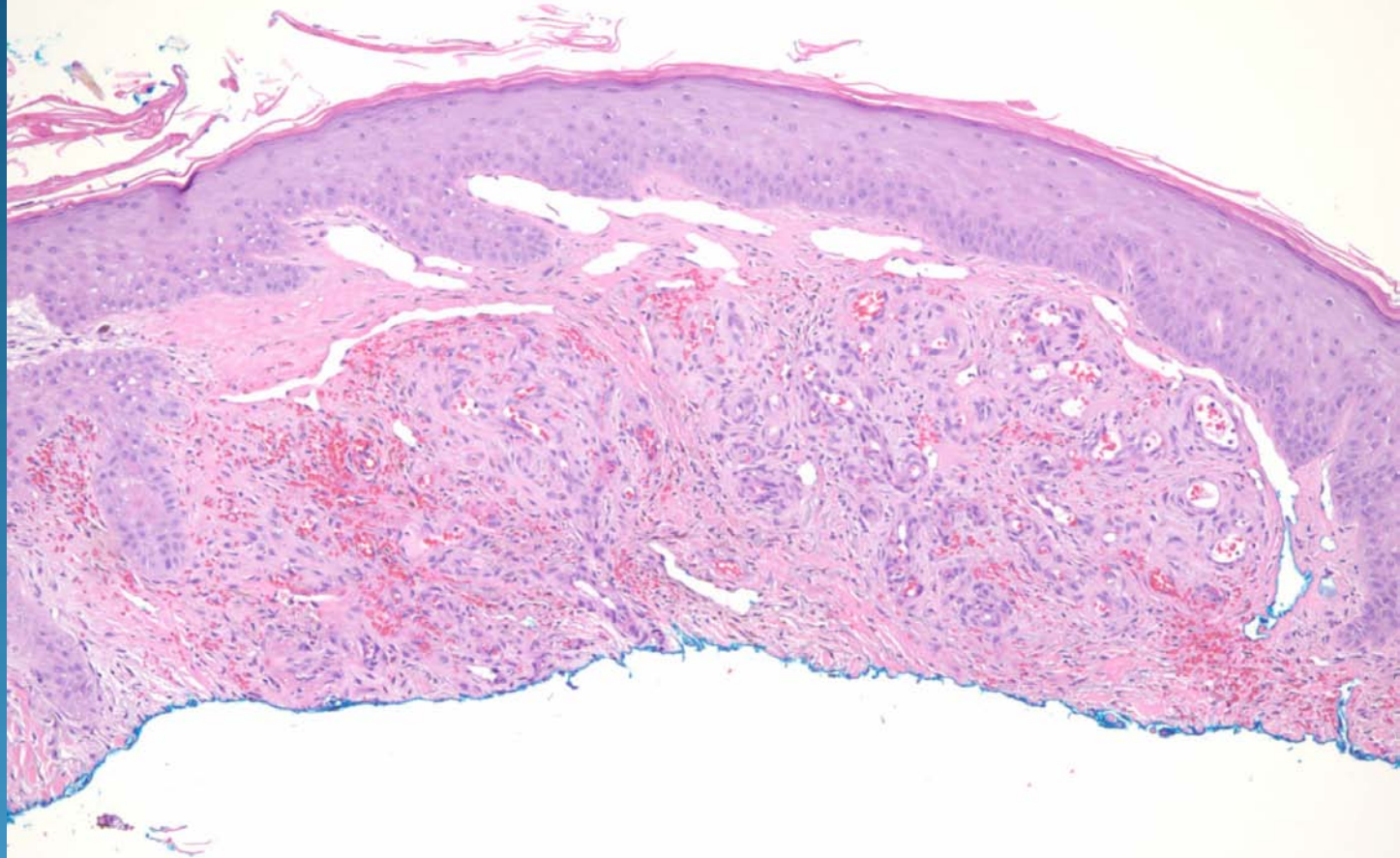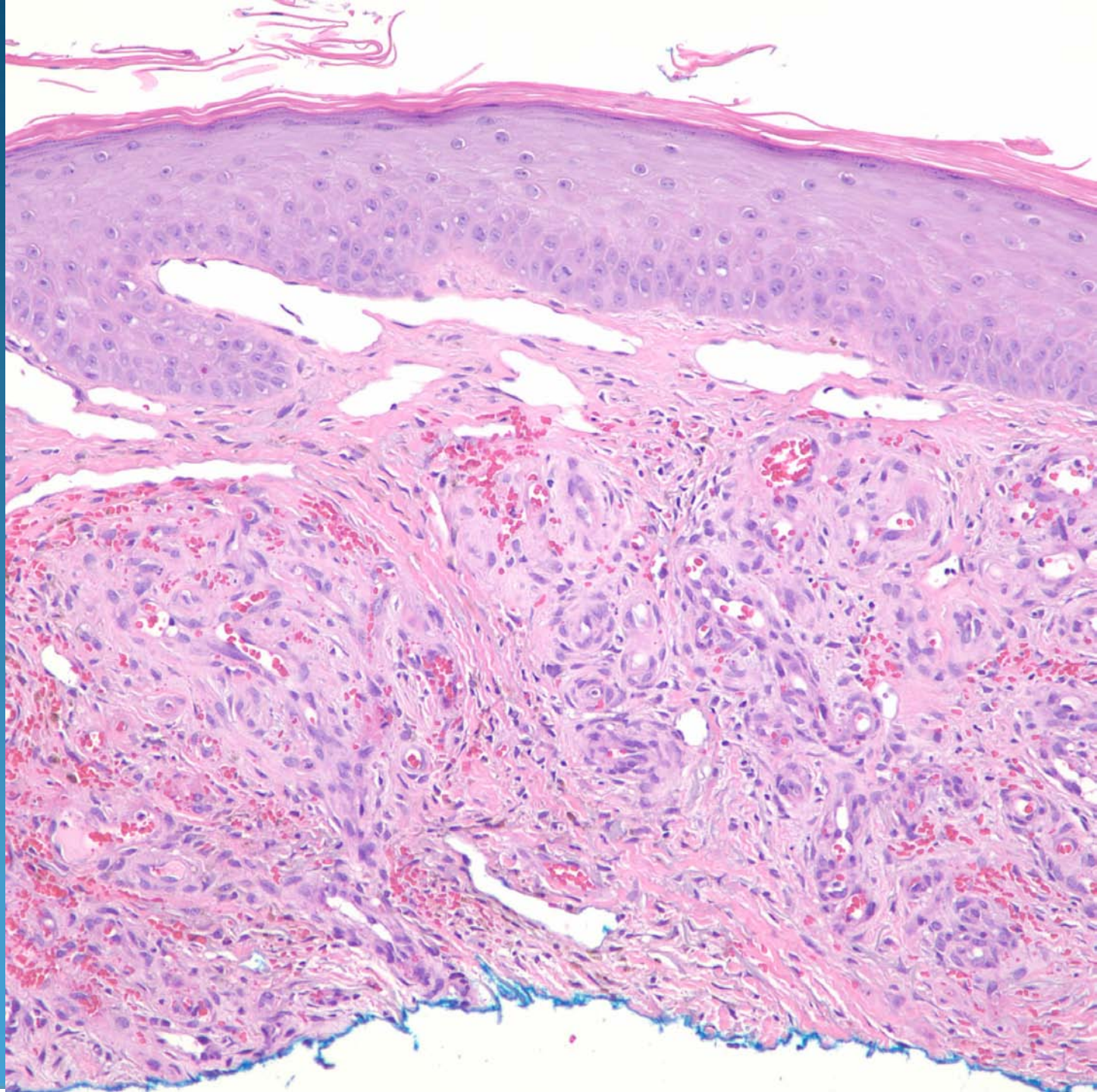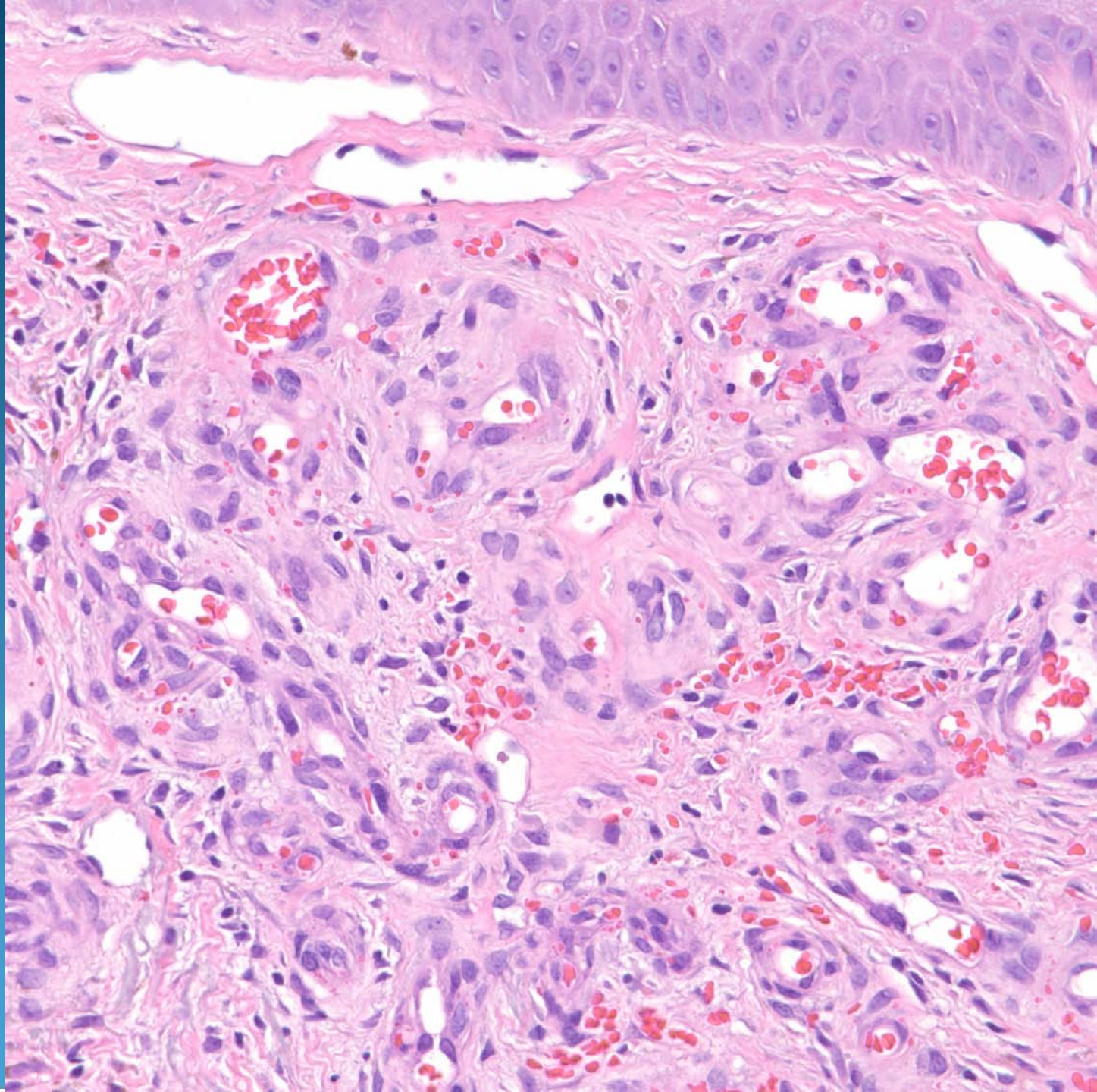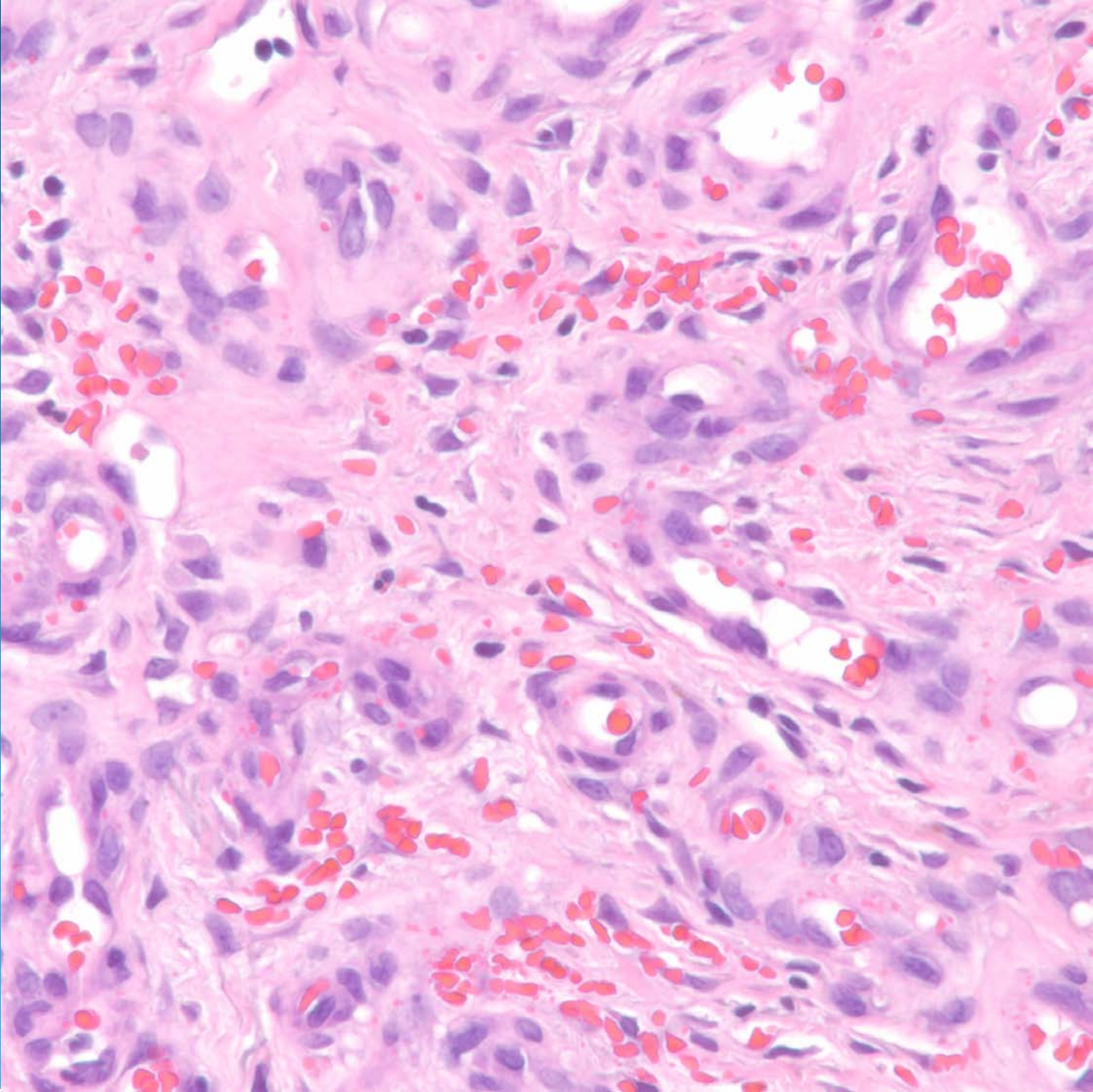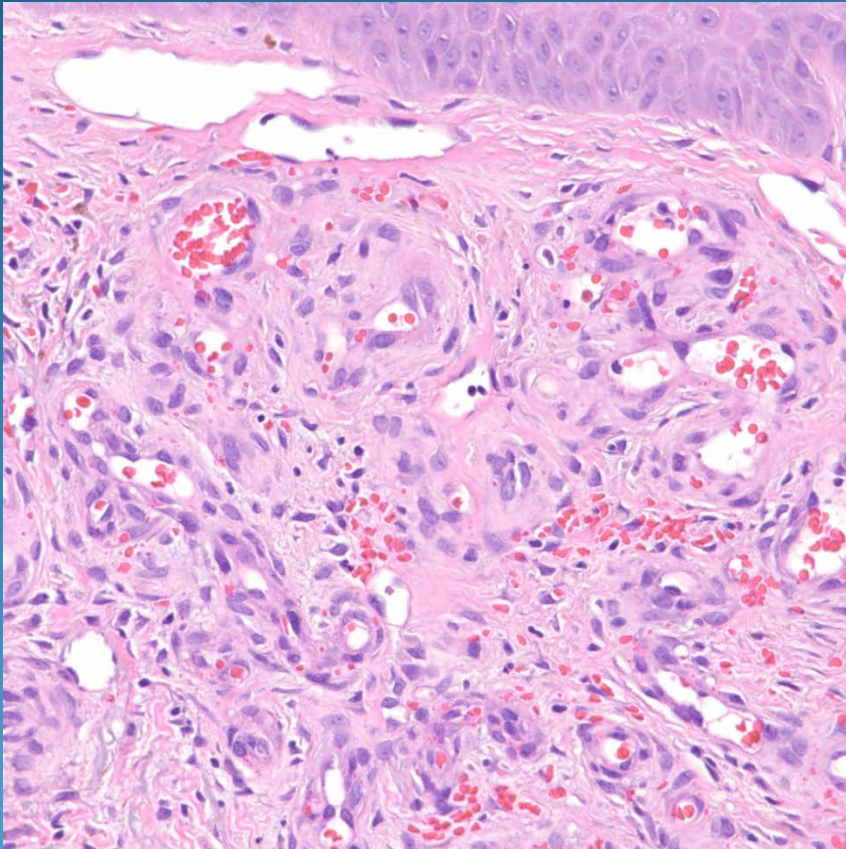


Stasis Dermatitis

Pearls



- Lobular configuration of capillary-sized vessels
- Extravasated red blood cells with hemosiderin-laden macrophages
- Later lesions may show fibroplasia
- R/O Kaposi's sarcoma