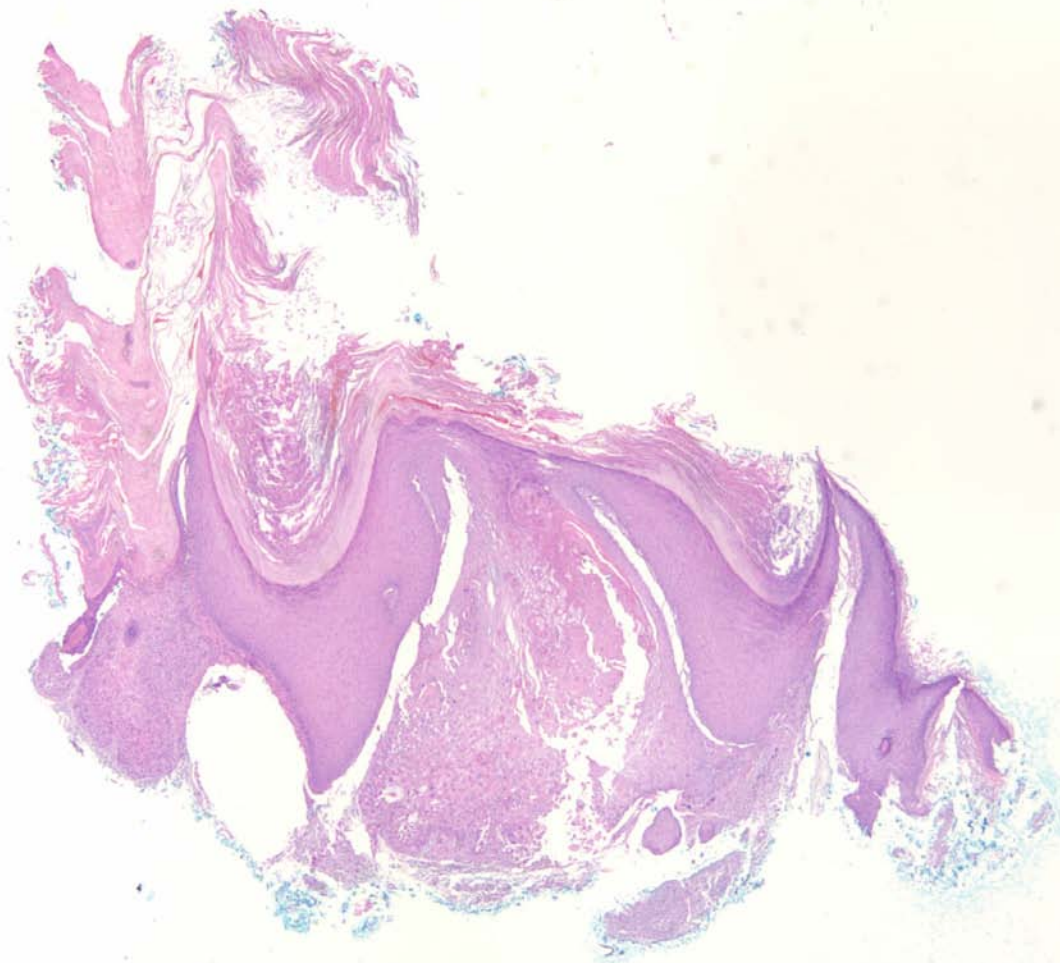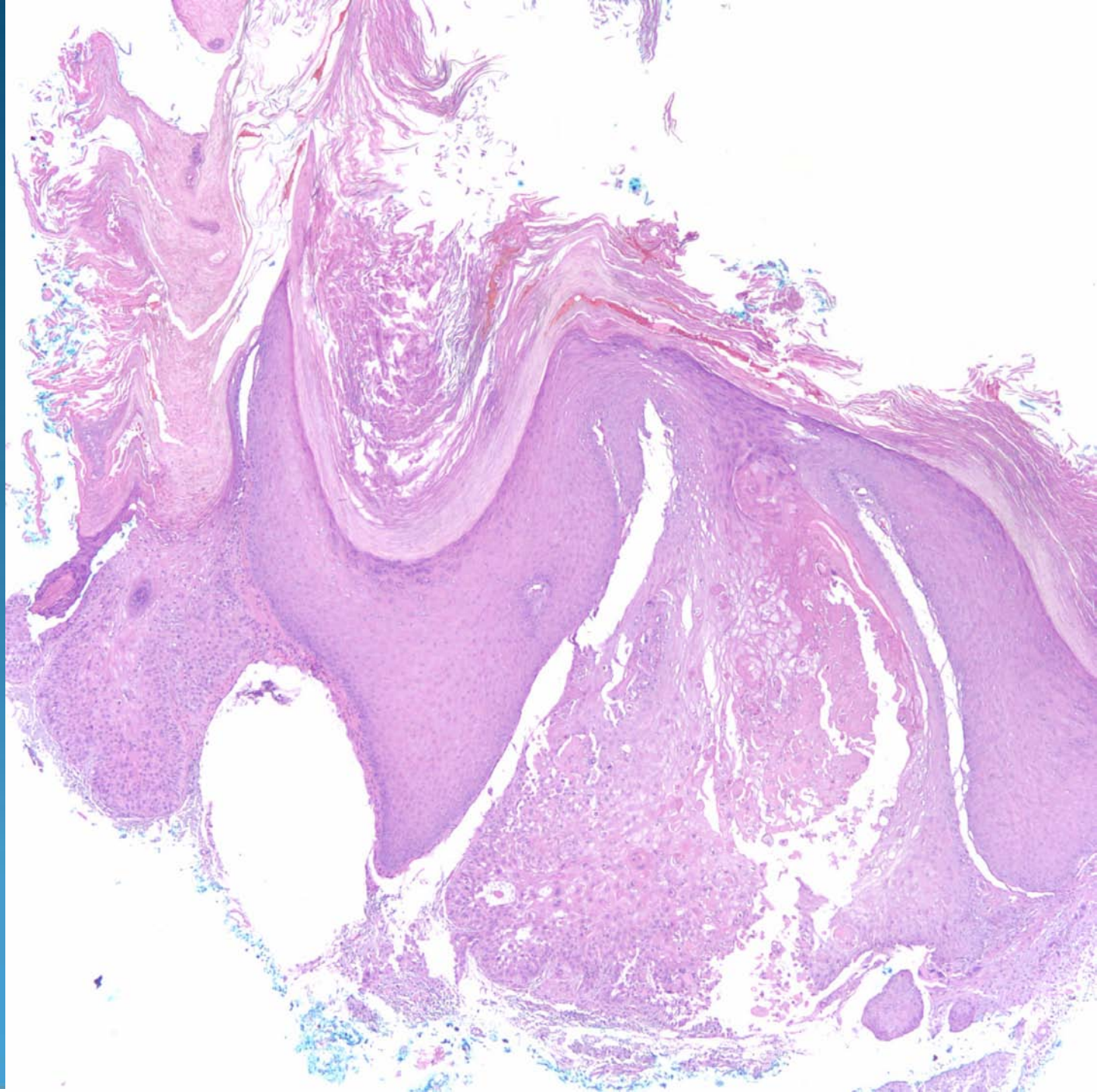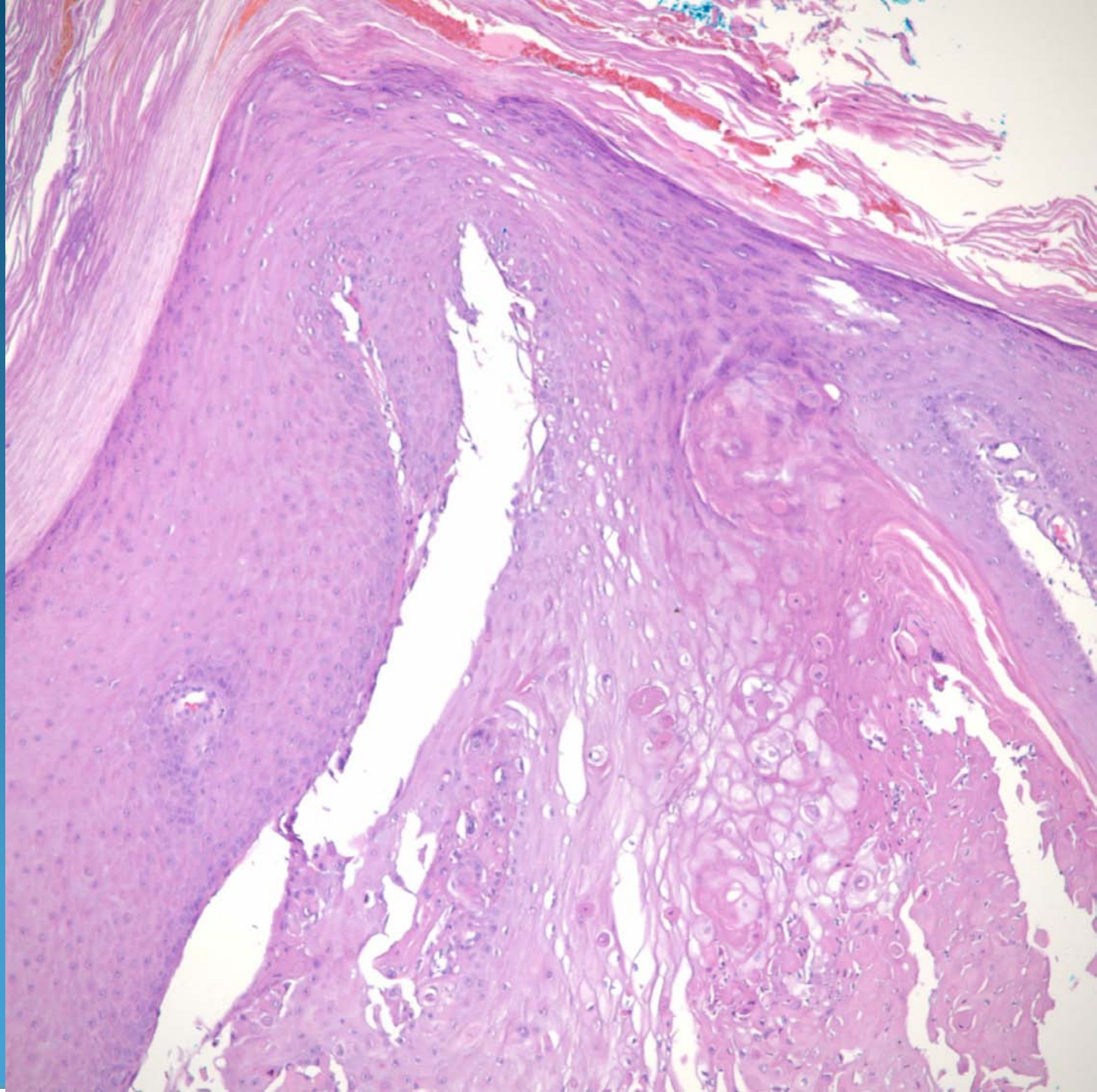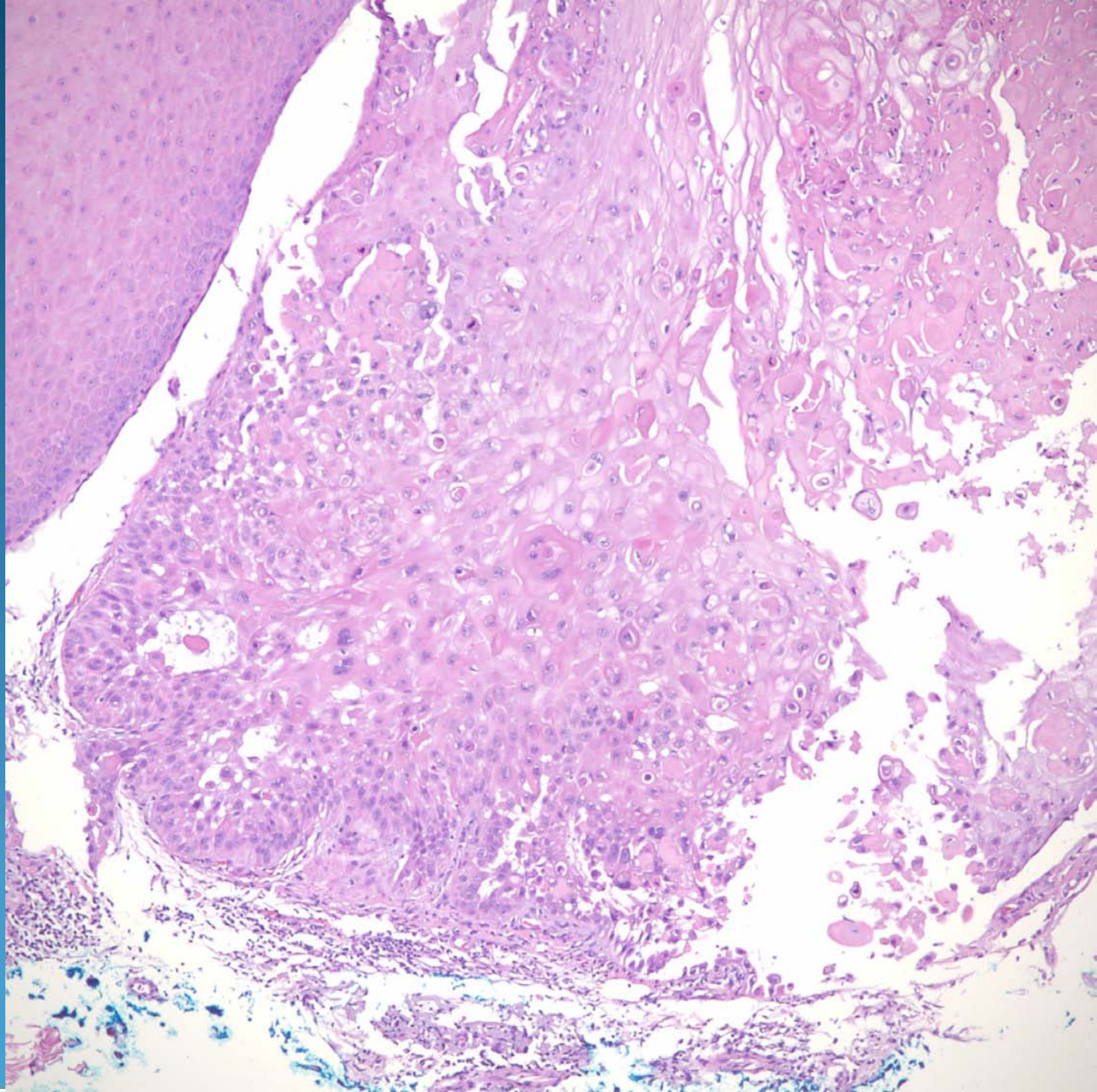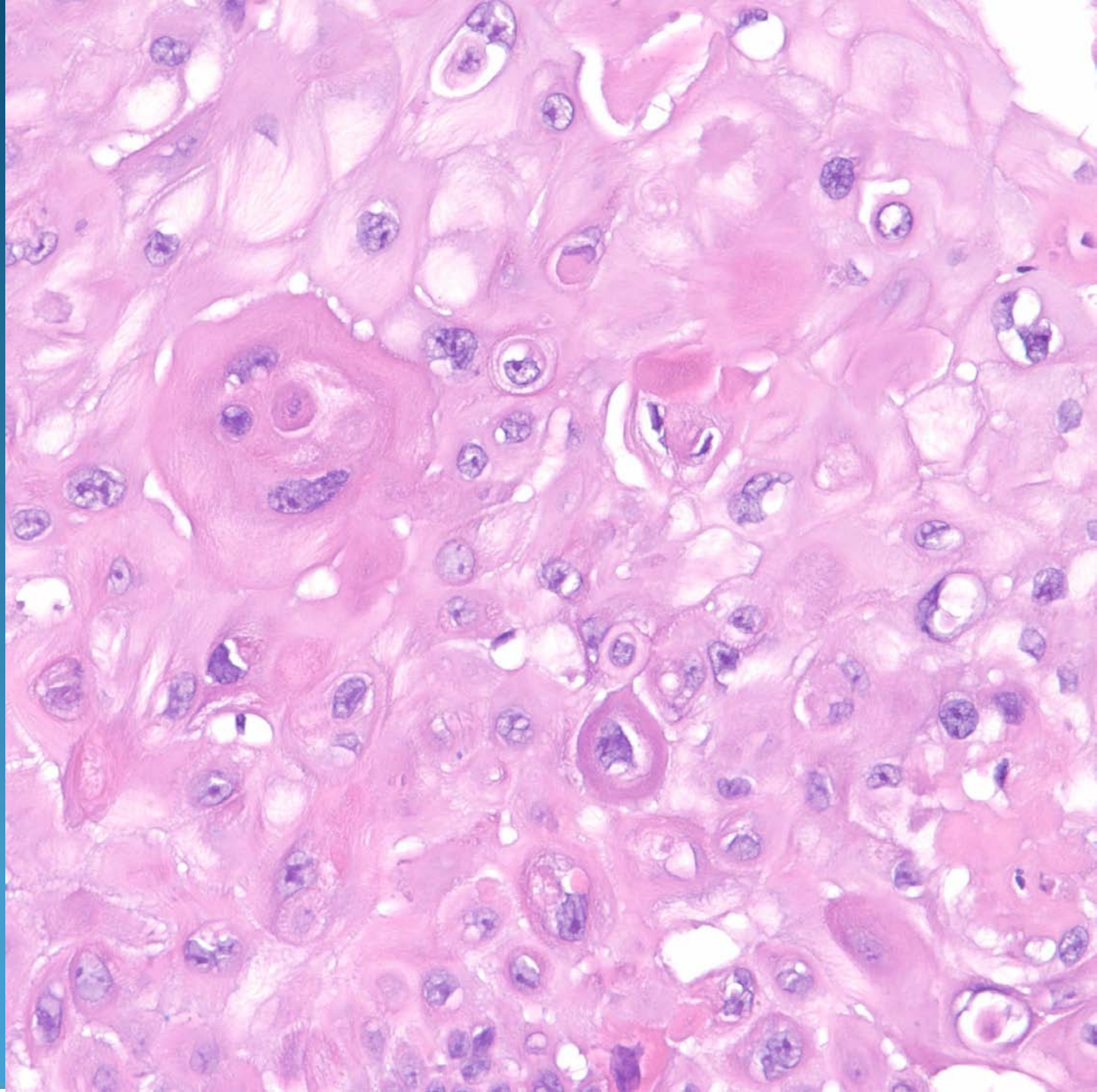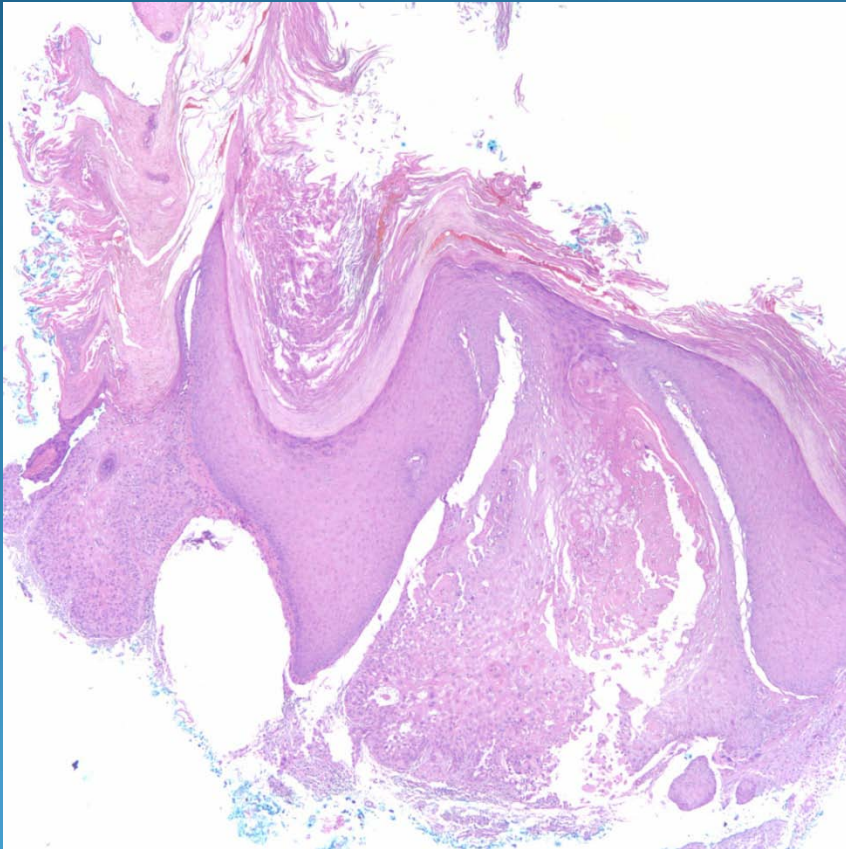


Invasive Squamous Cell Carcinoma arising in association with a Verruca Vulgaris

Pearls



- Beware the diagnostic pitfall of superficial biopsies that only show verruciform changes.
- Section deeper to exclude an underlying invasive squamous cell carcinoma.