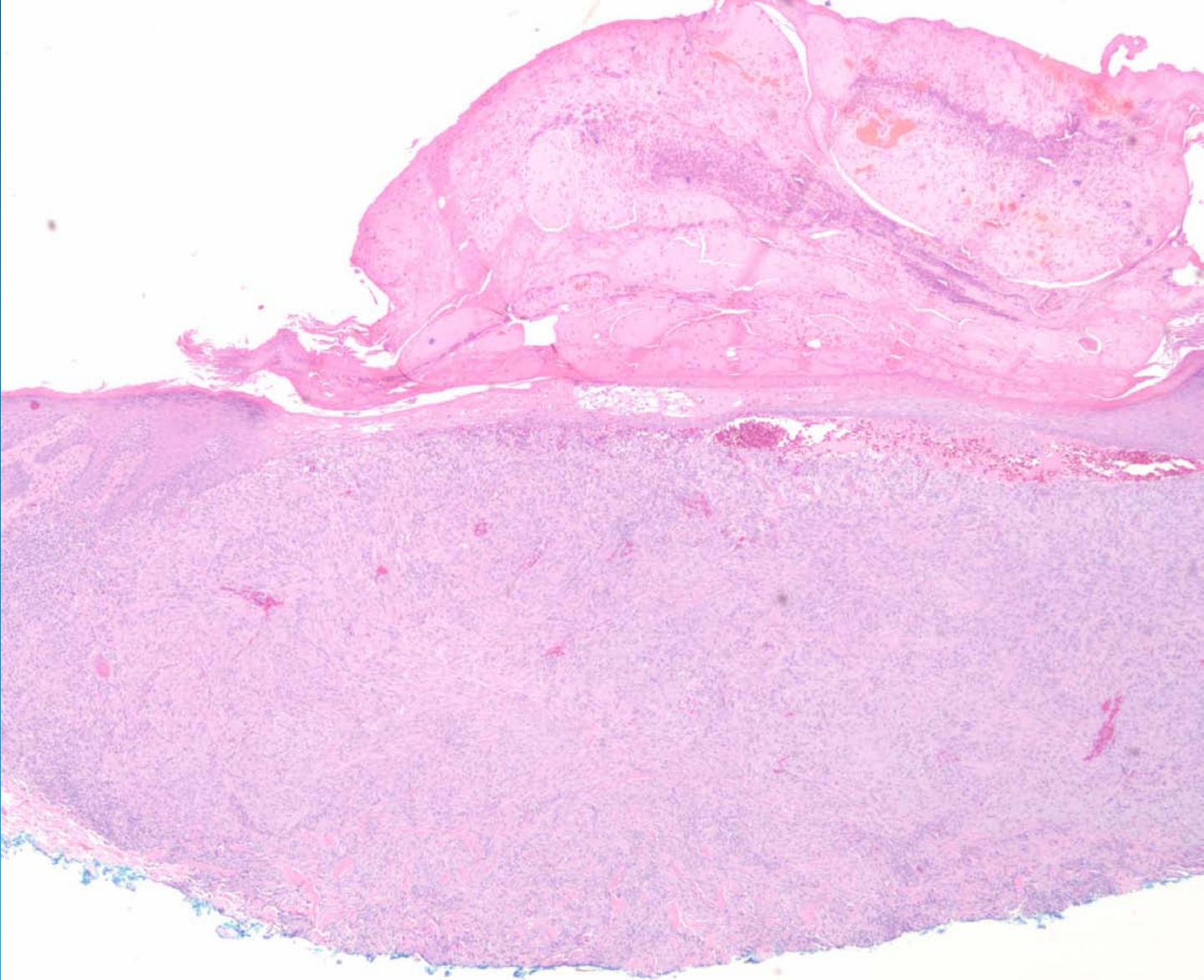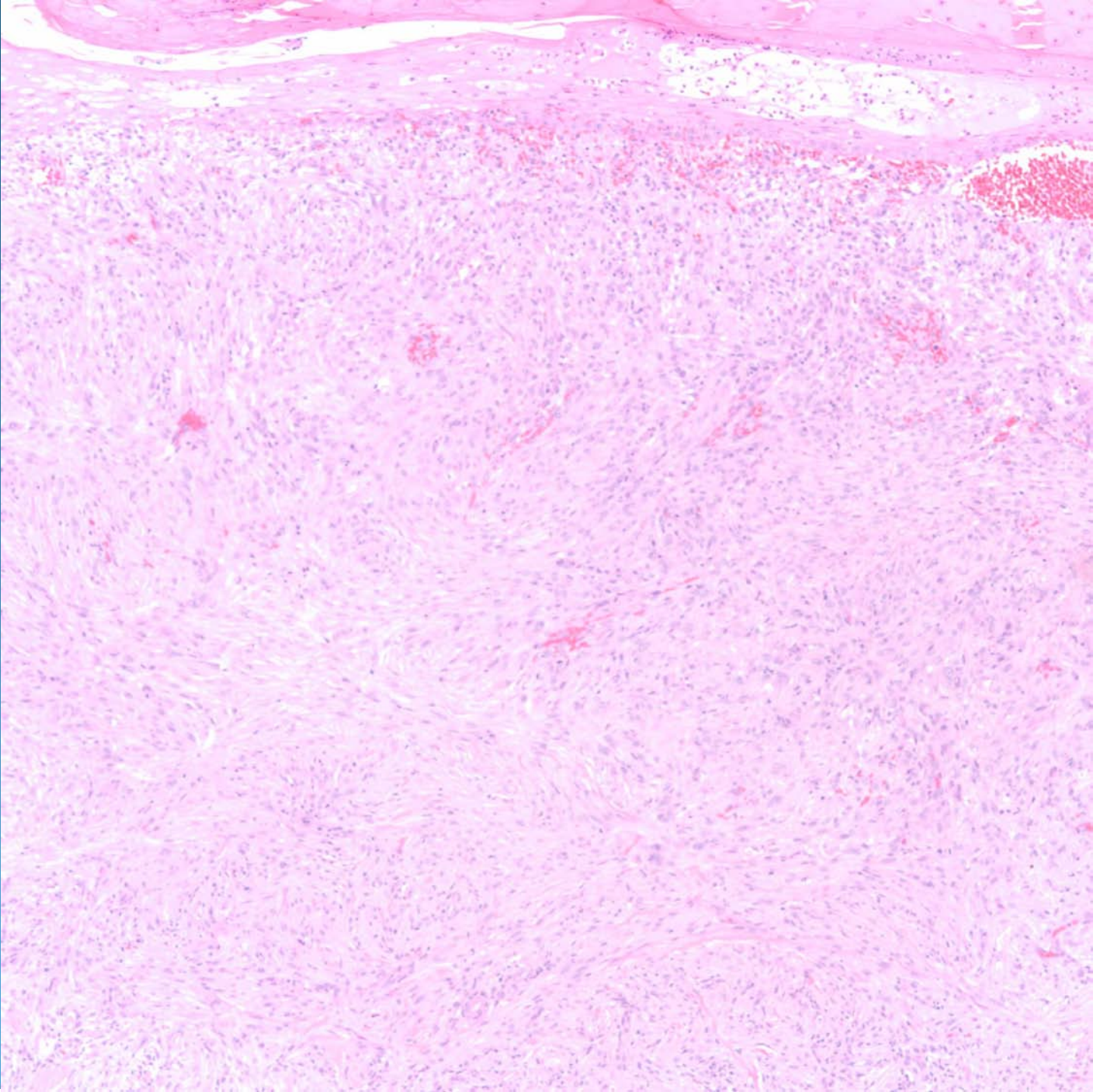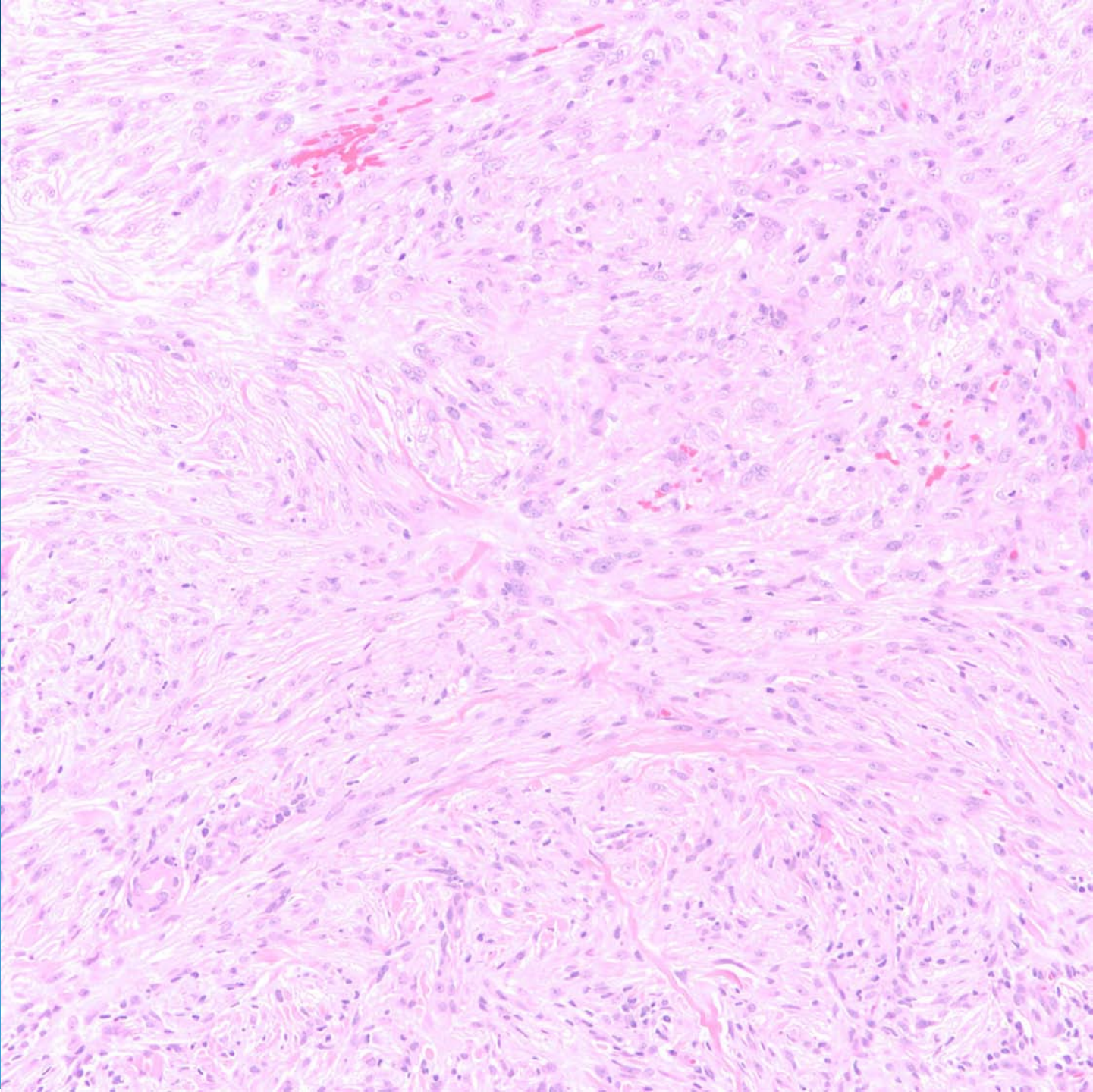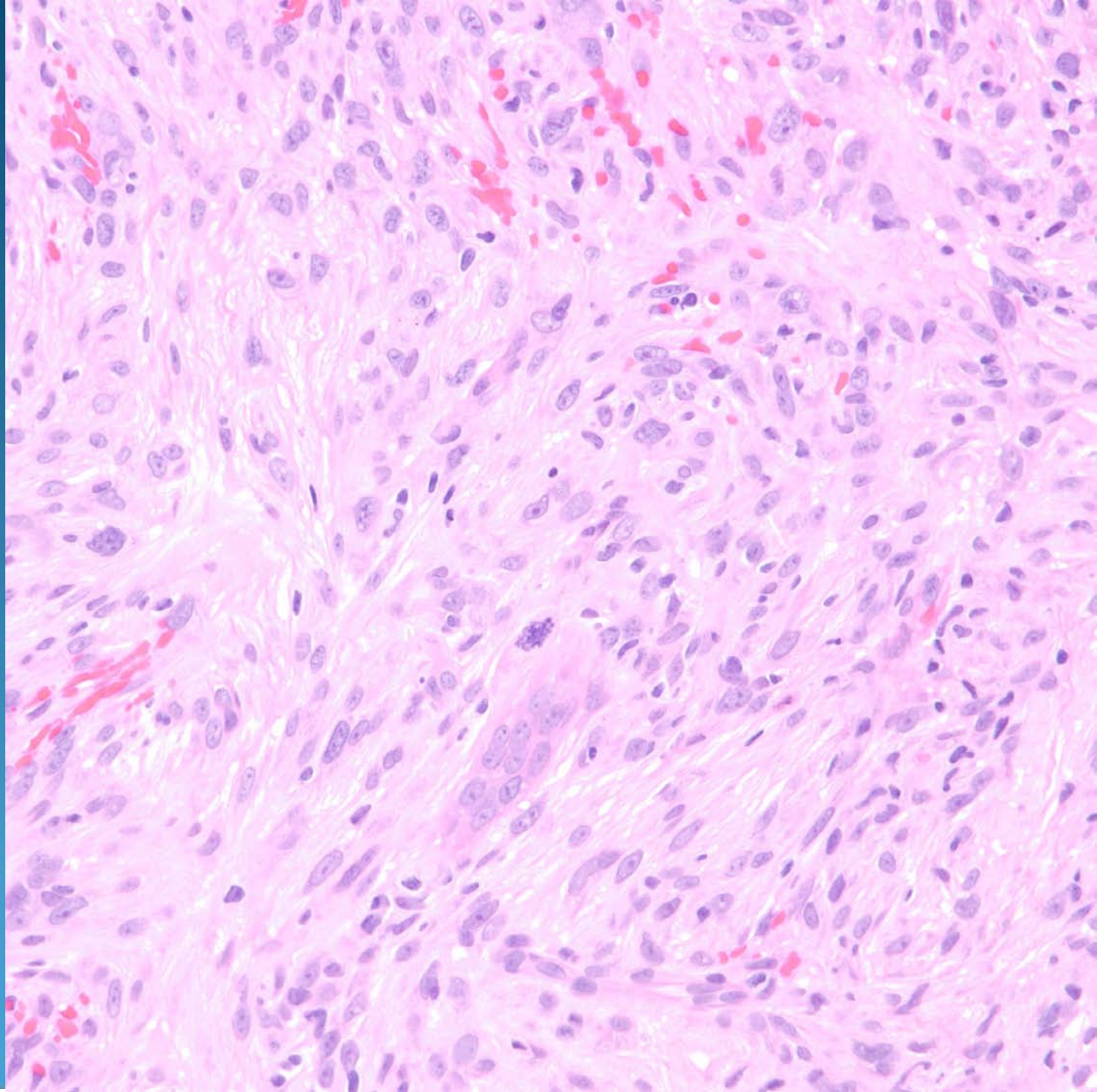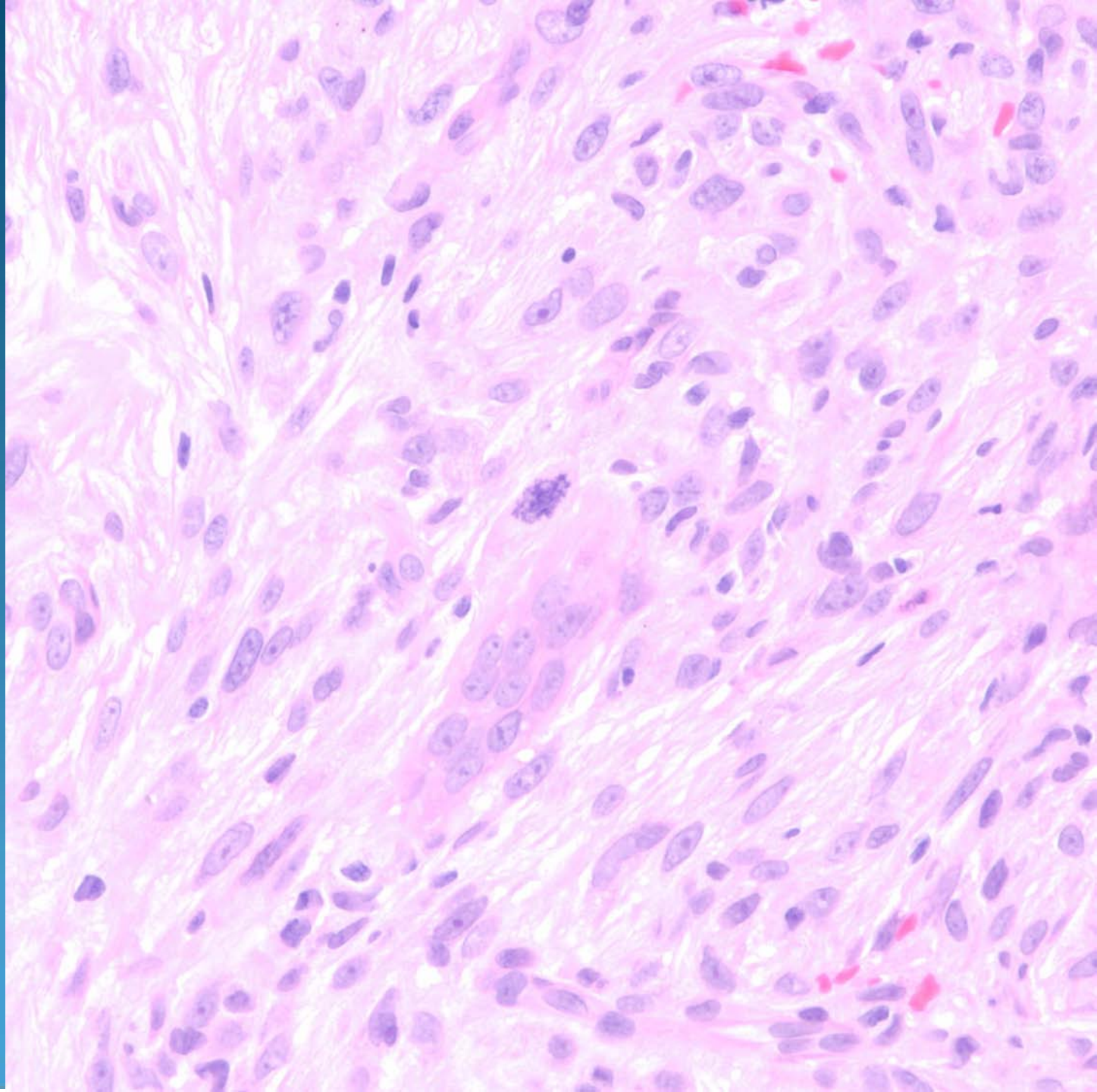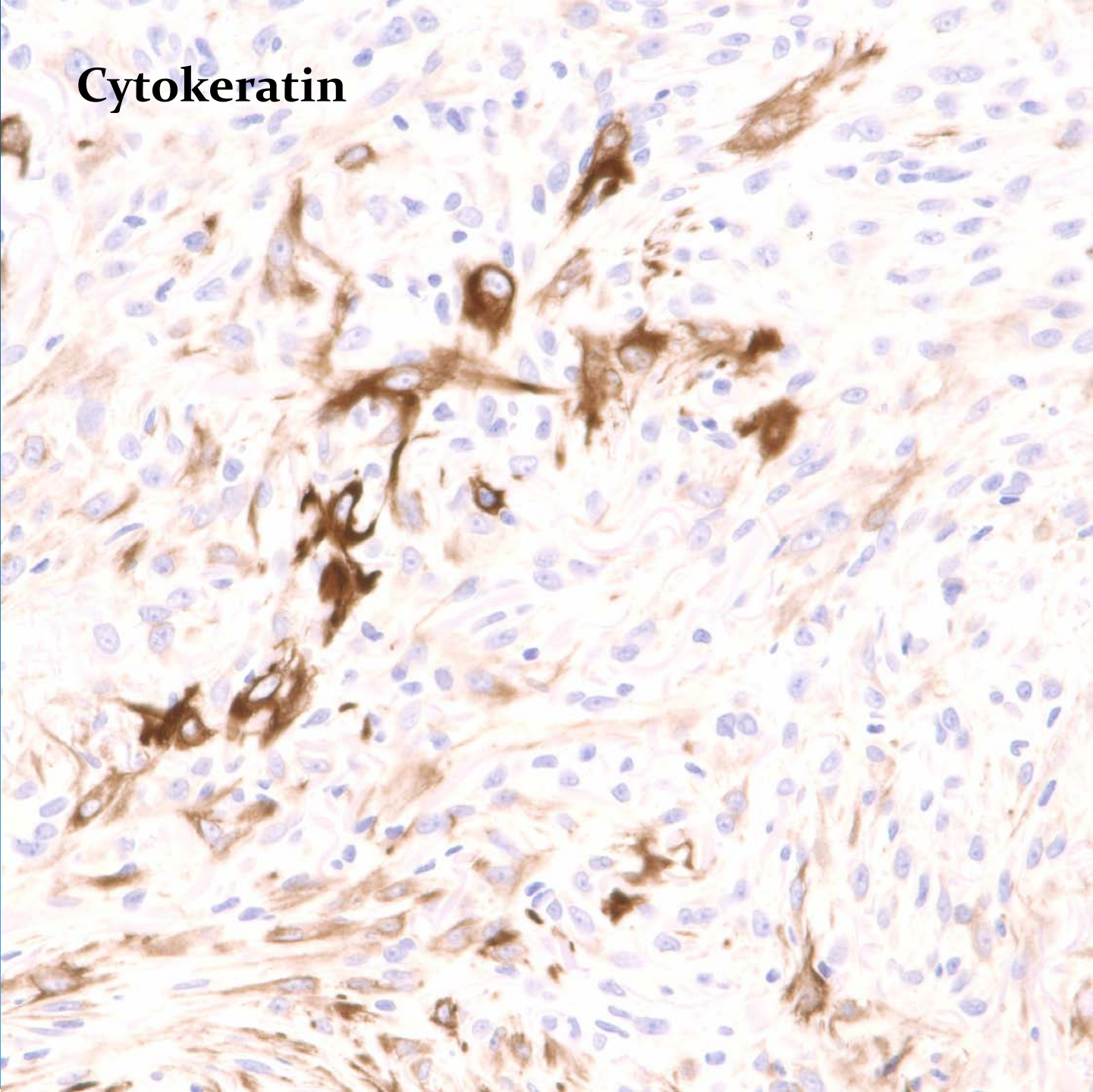
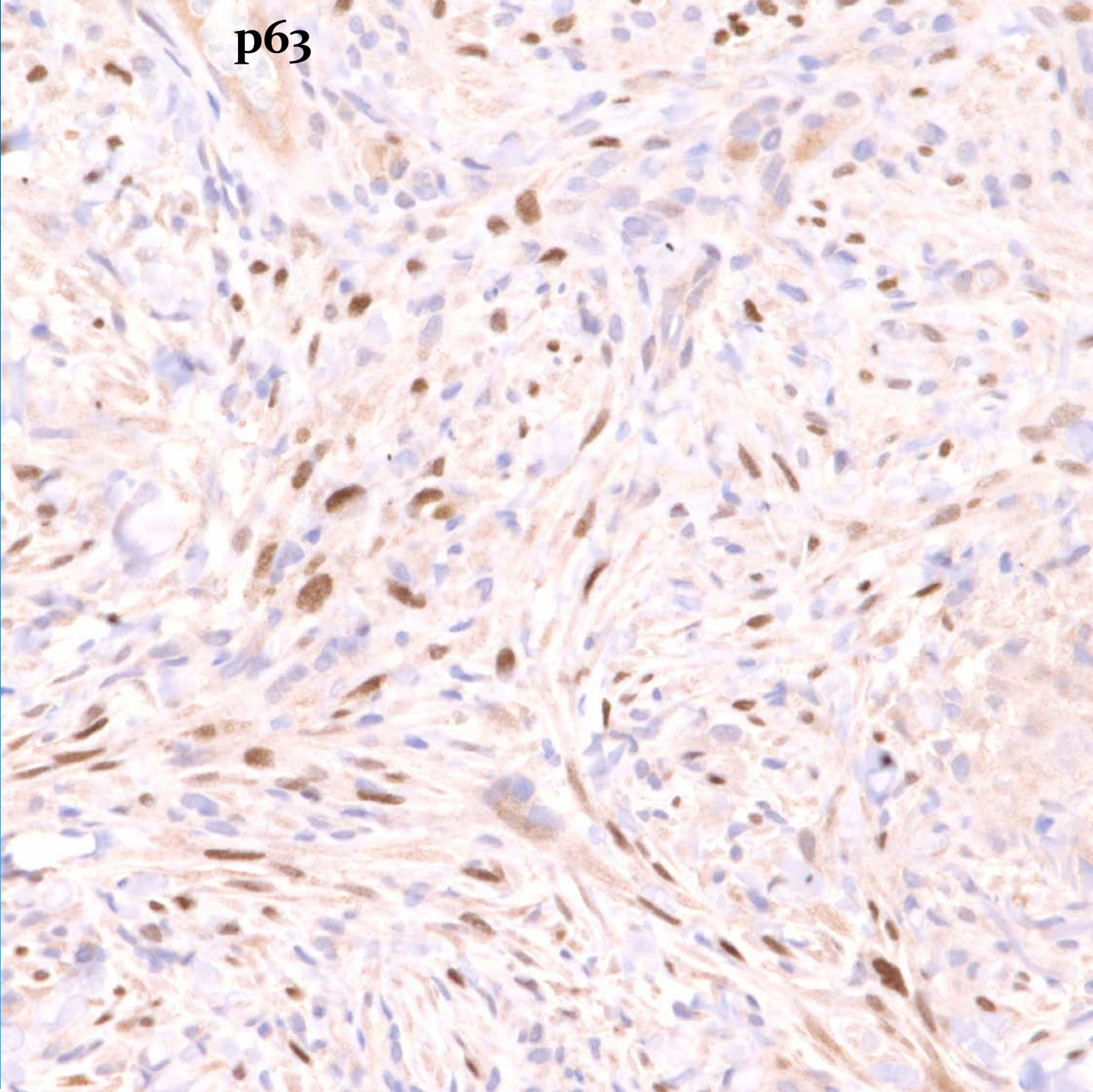


Sarcomatoid Squamous Cell Carcinoma

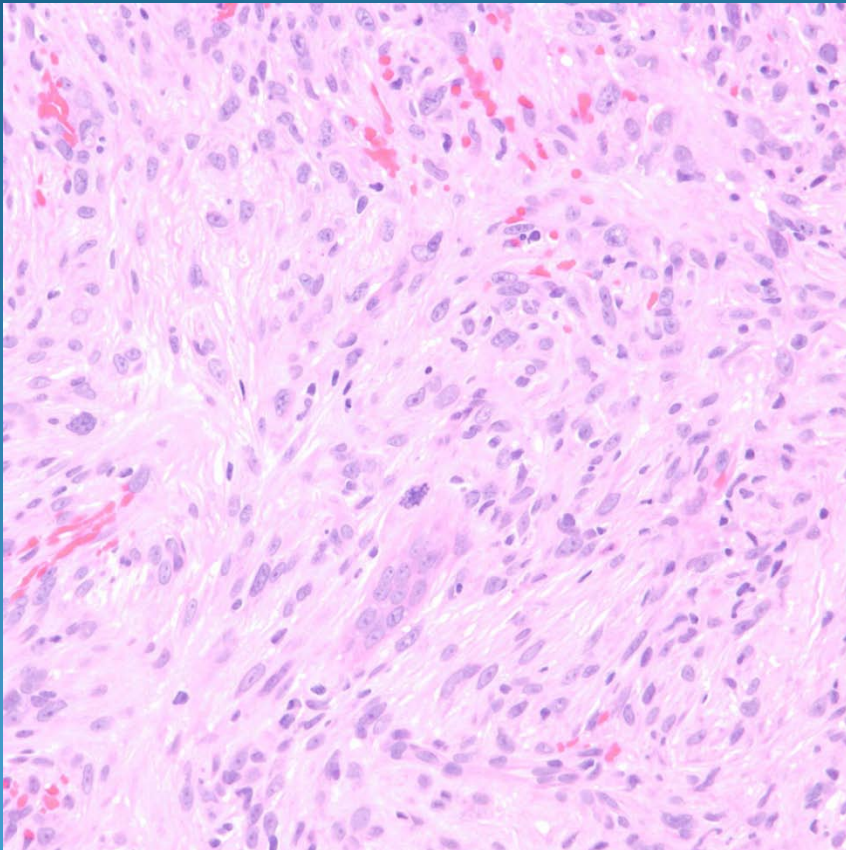
Cytokeratin



p63



Pearls



- Cytologically malignant spindle cell proliferation
- Look for areas of malignant squamous pearls or dyskeratosis
- DDX: AFX, Leiomyosarcoma, Desmoplastic melanoma
- Confirm with IHC: CK and p63+