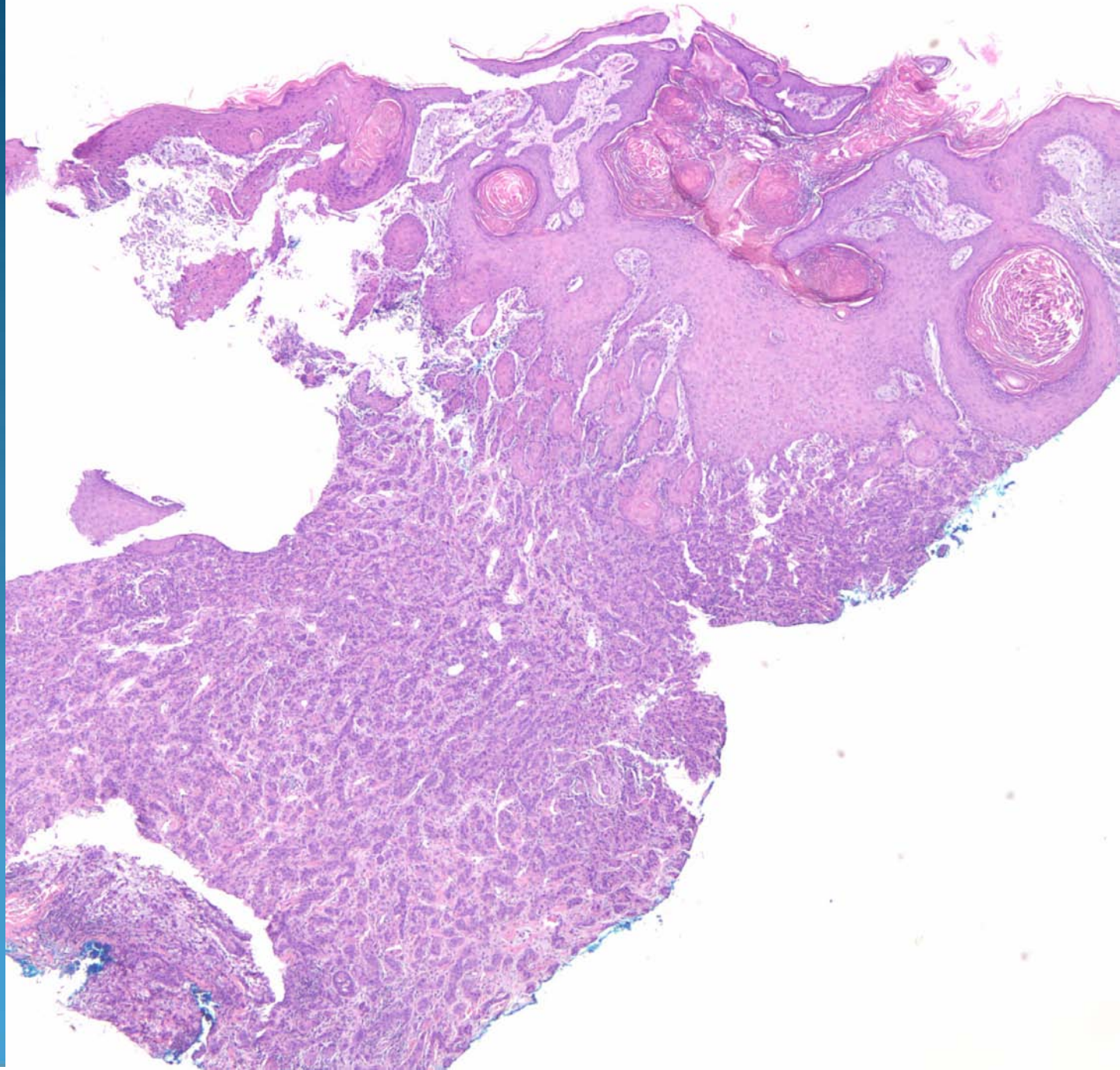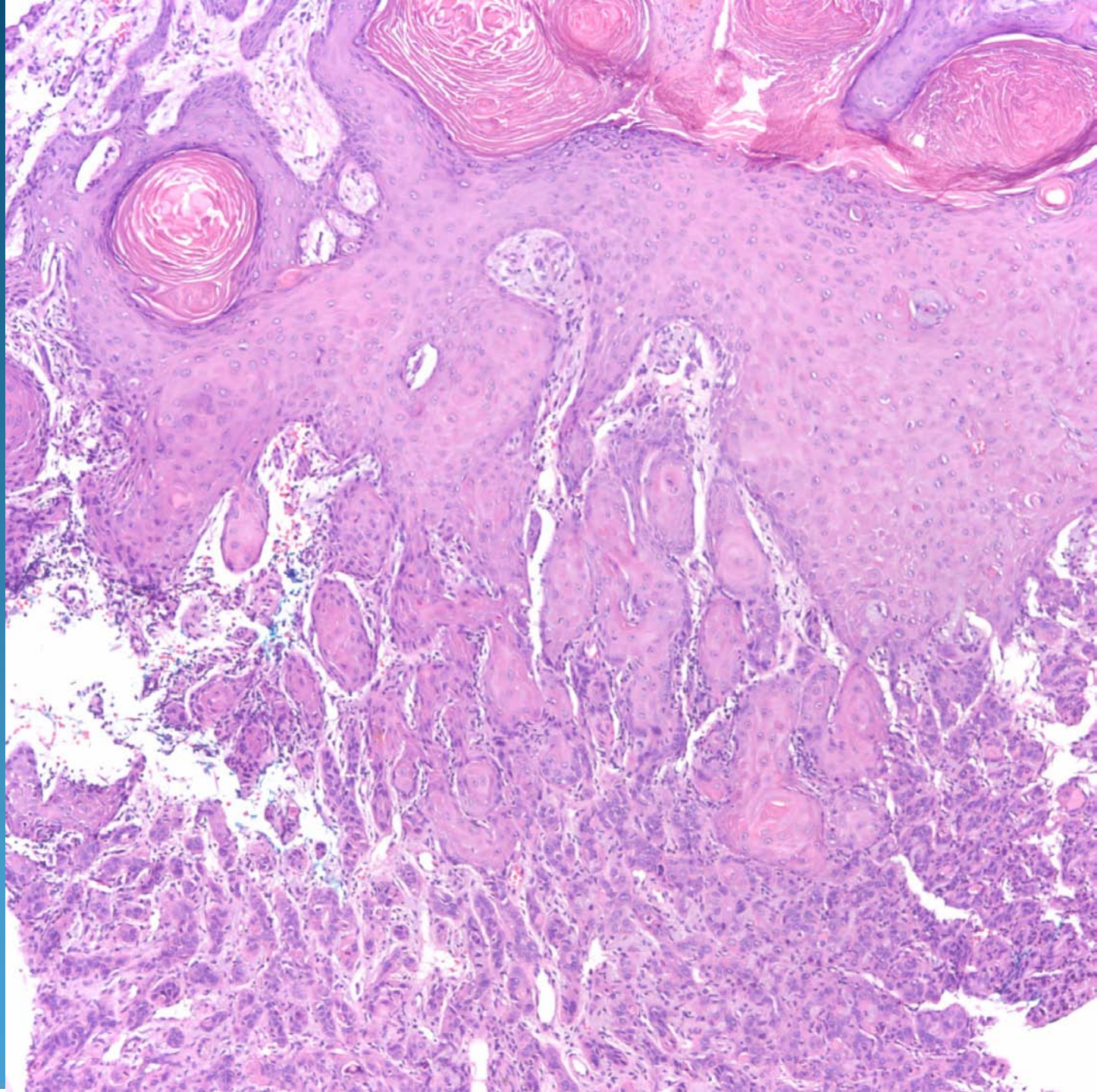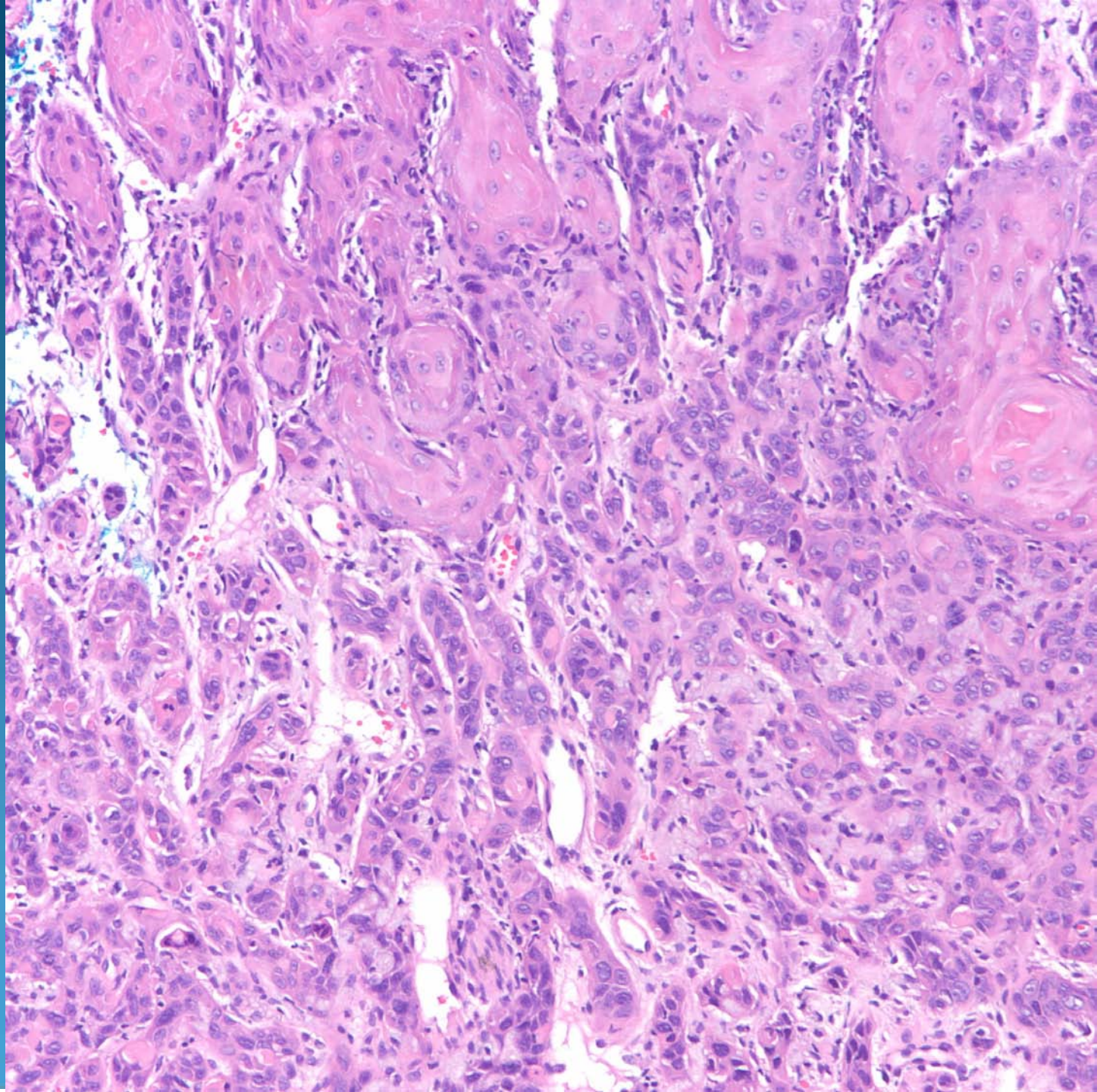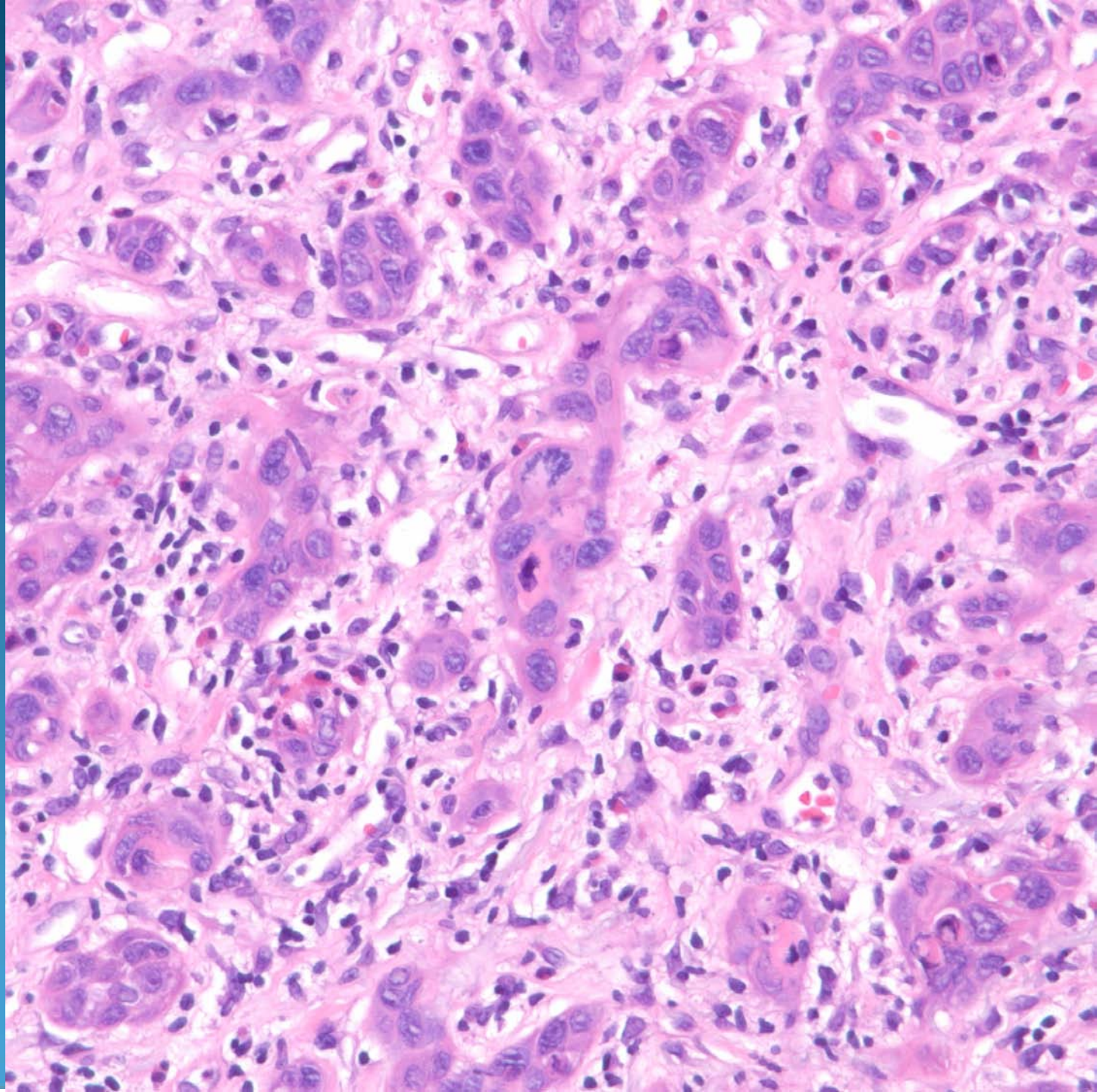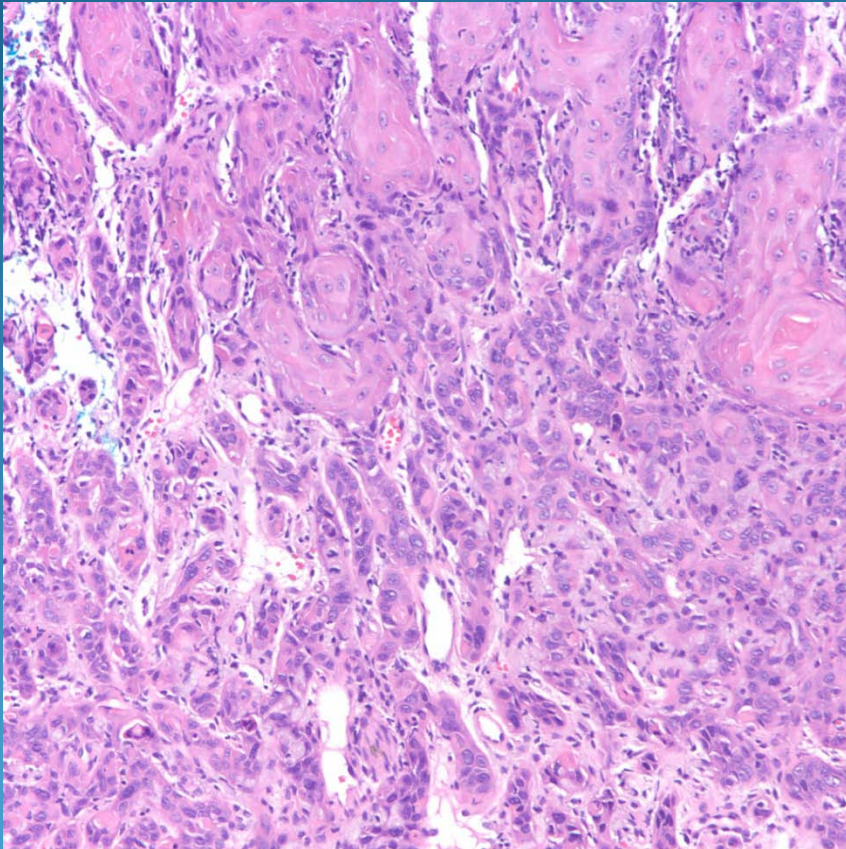


Invasive Squamous Cell Carcinoma, Poorly Differentiated

Pearls



- Invasive nests of pleomorphic squamous epithelial cells
- Look for areas of squamous pearl formation and intercellular bridges
- May be completely replaced with sheets and cords of poorly differentiated cells
- Beware of perineural or lymphovascular invasion
- May need IHC to confirm (CK+)