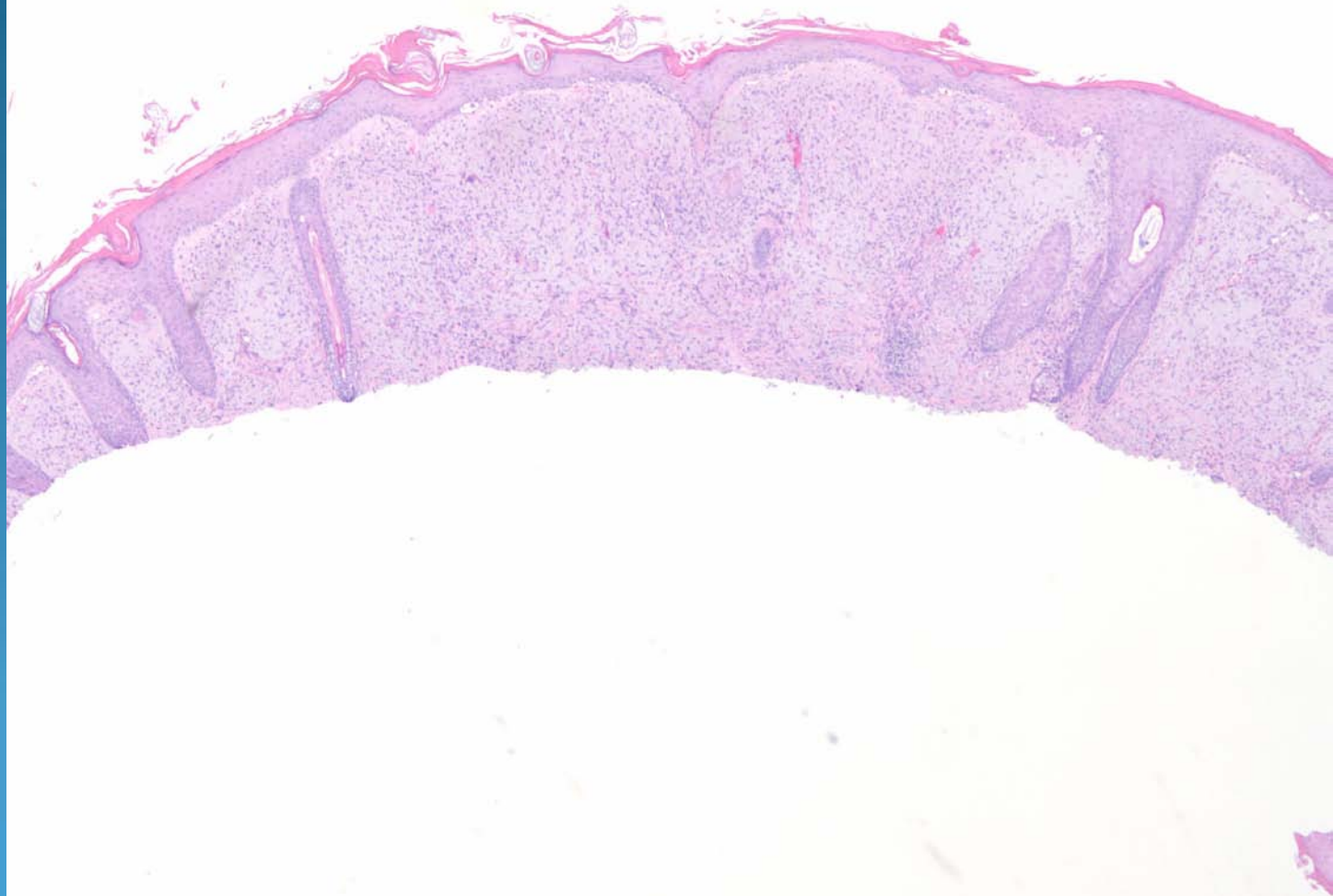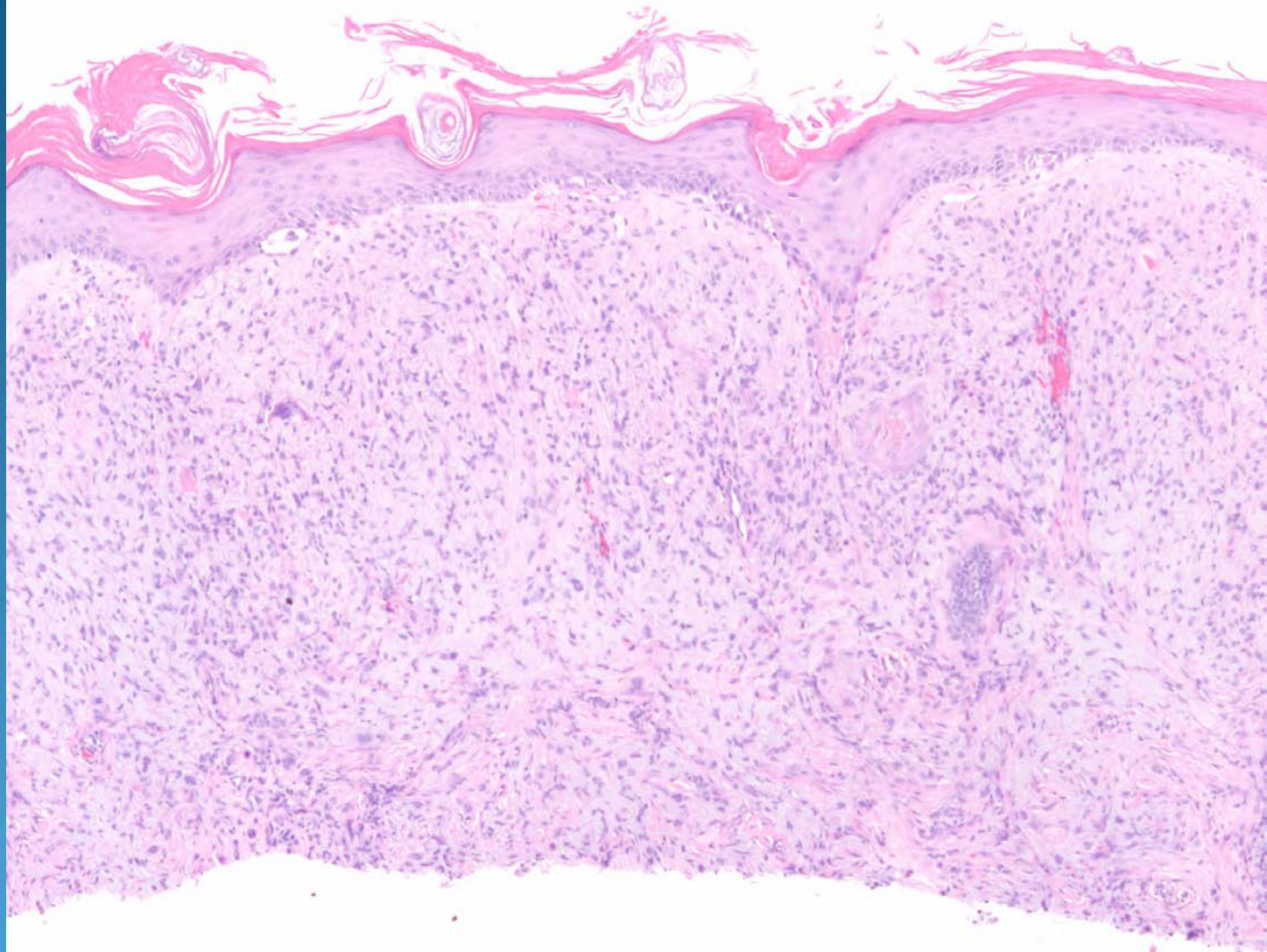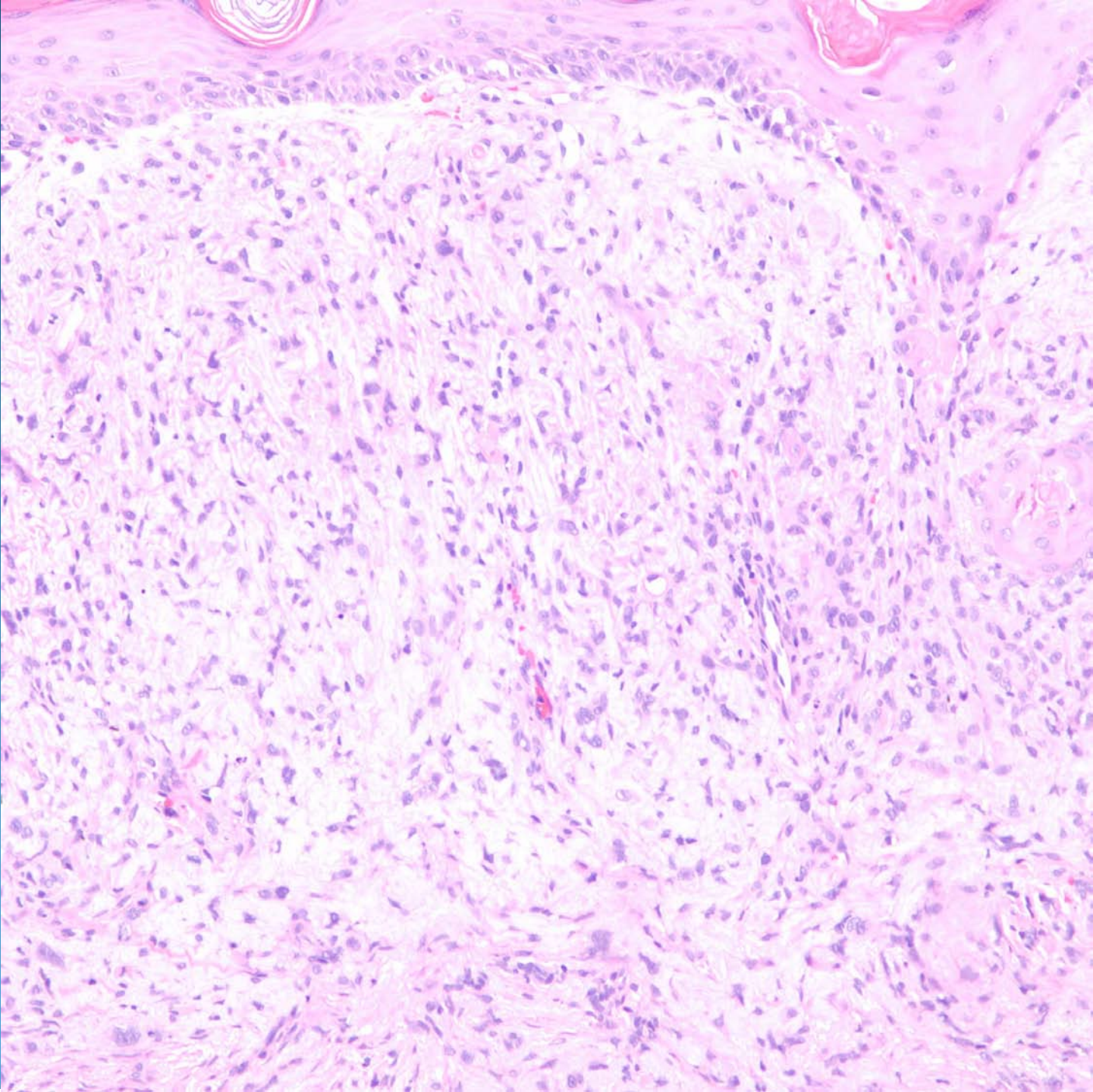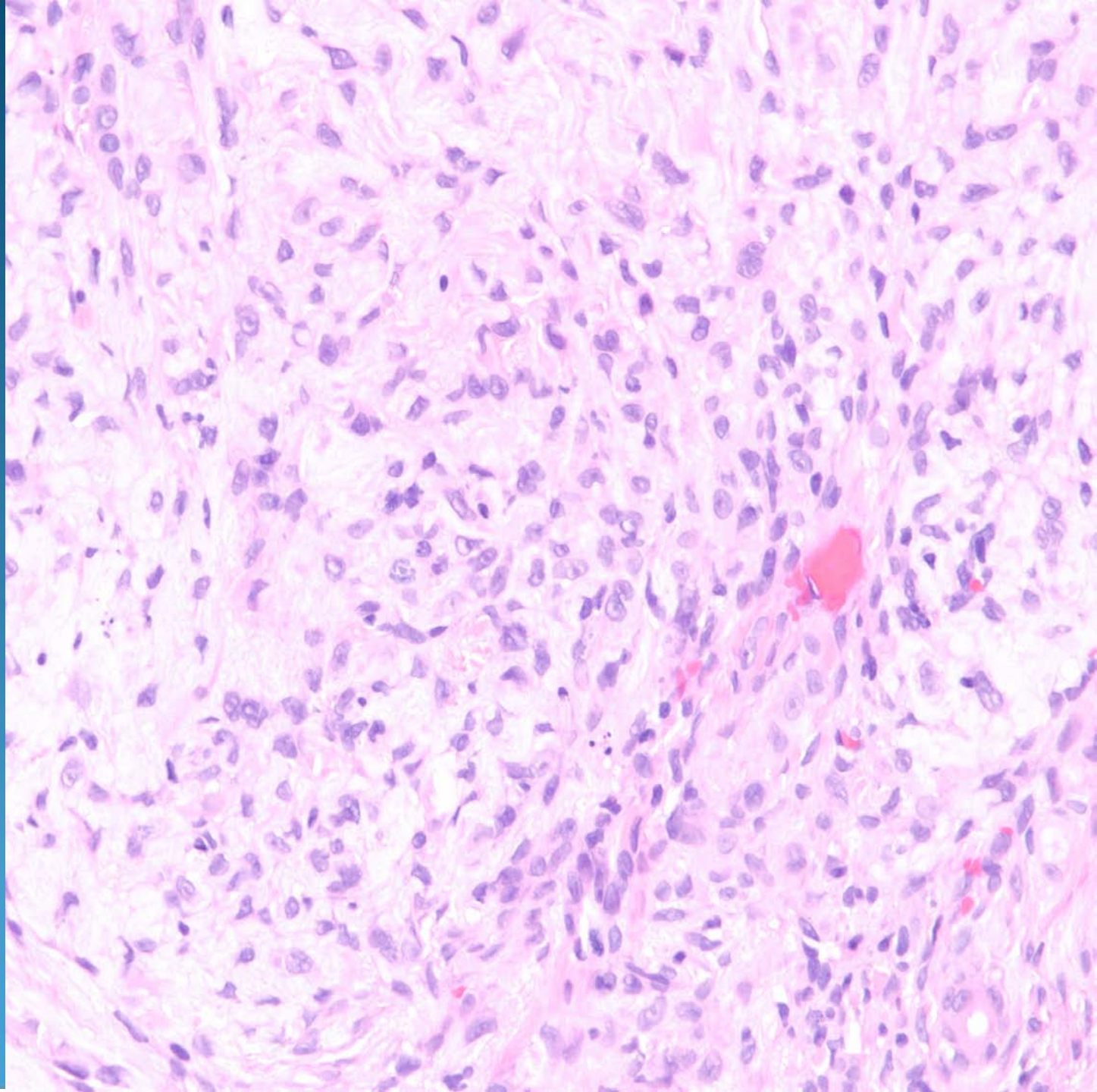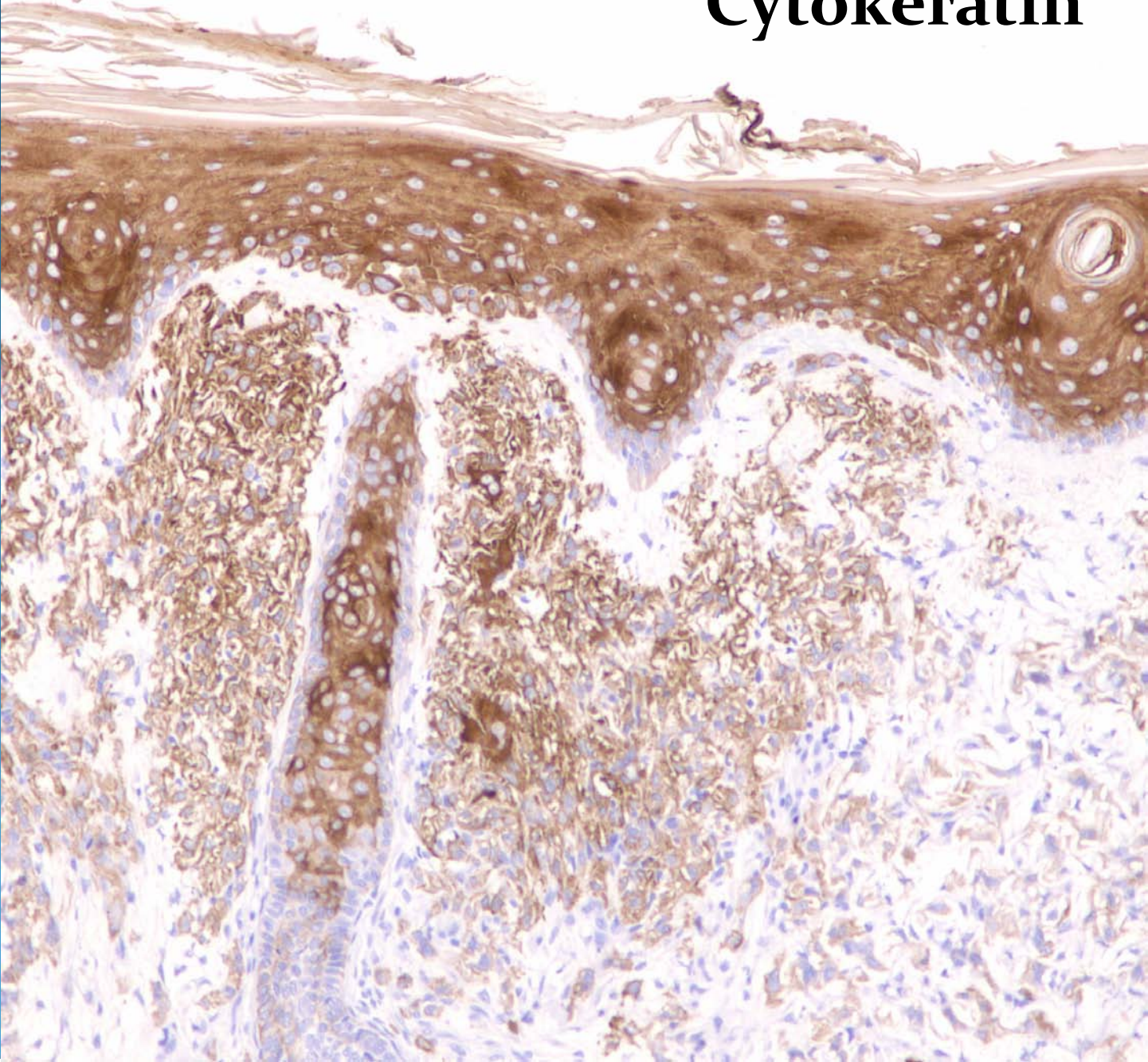
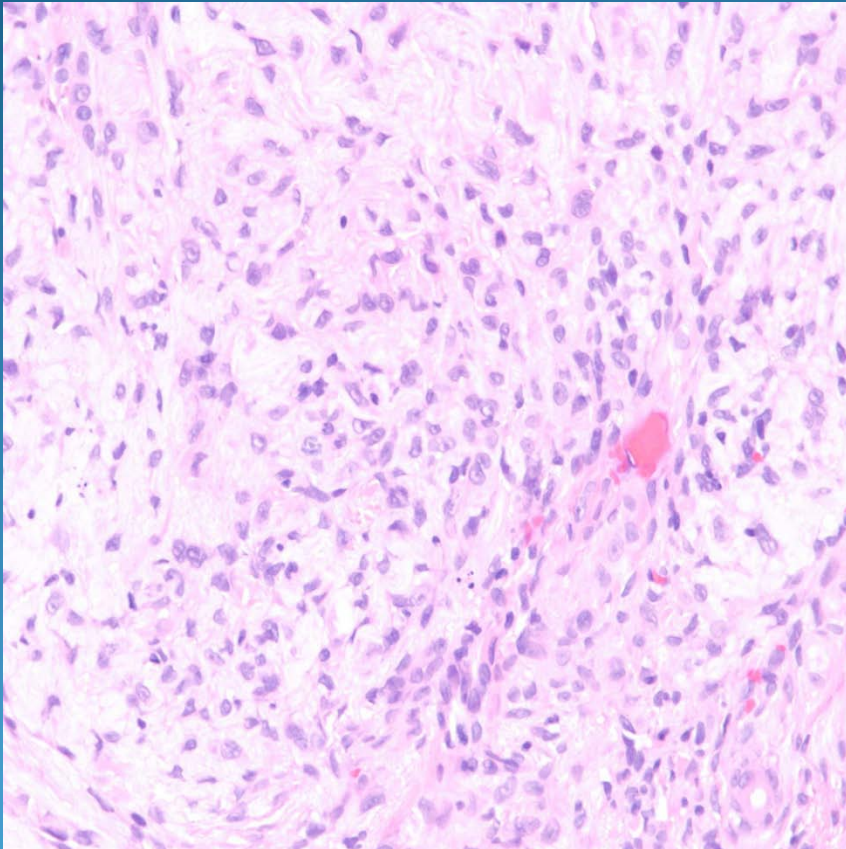


Cytokeratin



Invasive Squamous Cell Carcinoma, Poorly Differentiated

Pearls



- Diffuse sheets of cytologically malignancy spindle cells
- Squamous pearl formation and epidermal attachment may be difficult to find
- May need IHC (Cytokeratin) to confirm