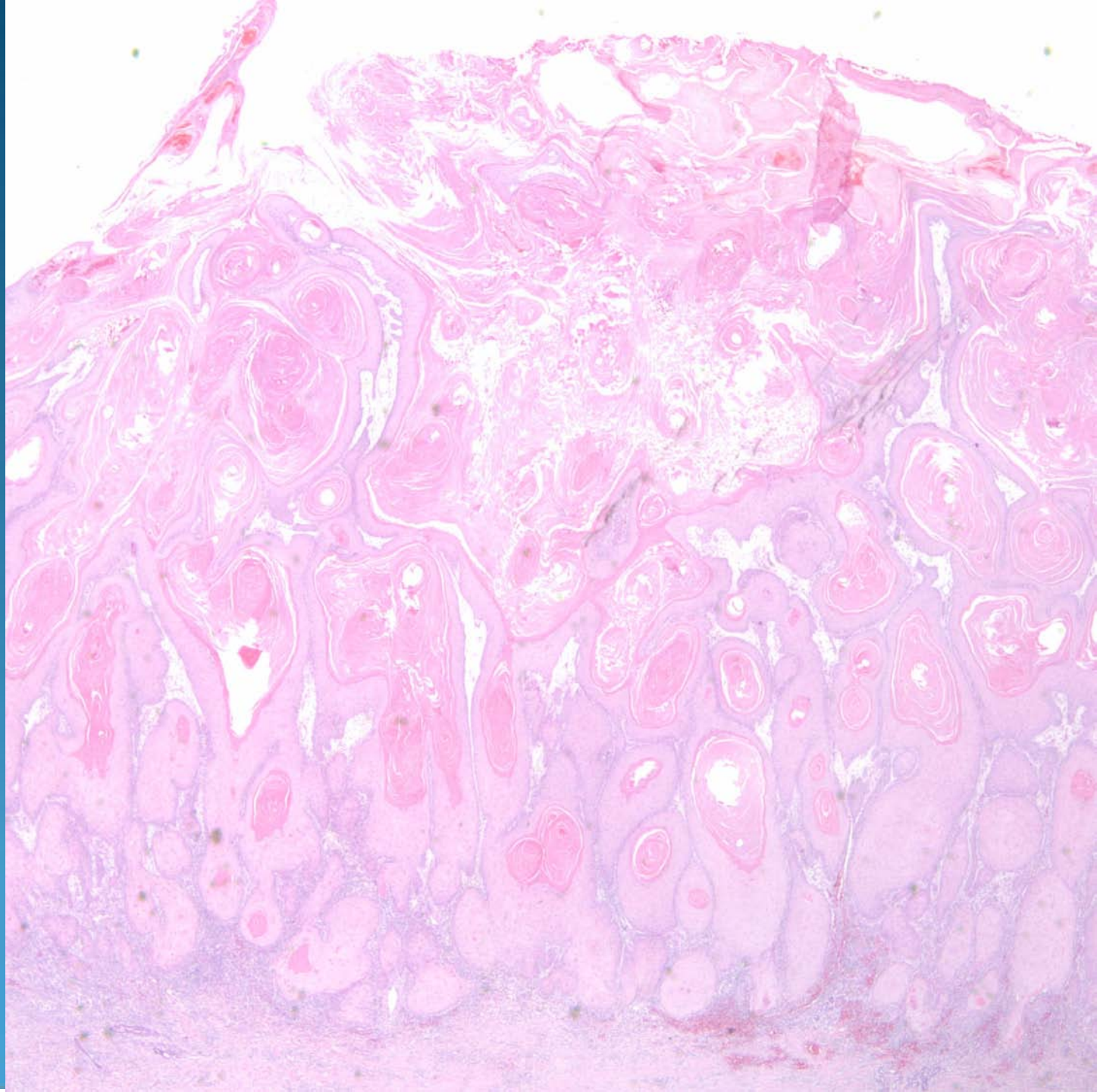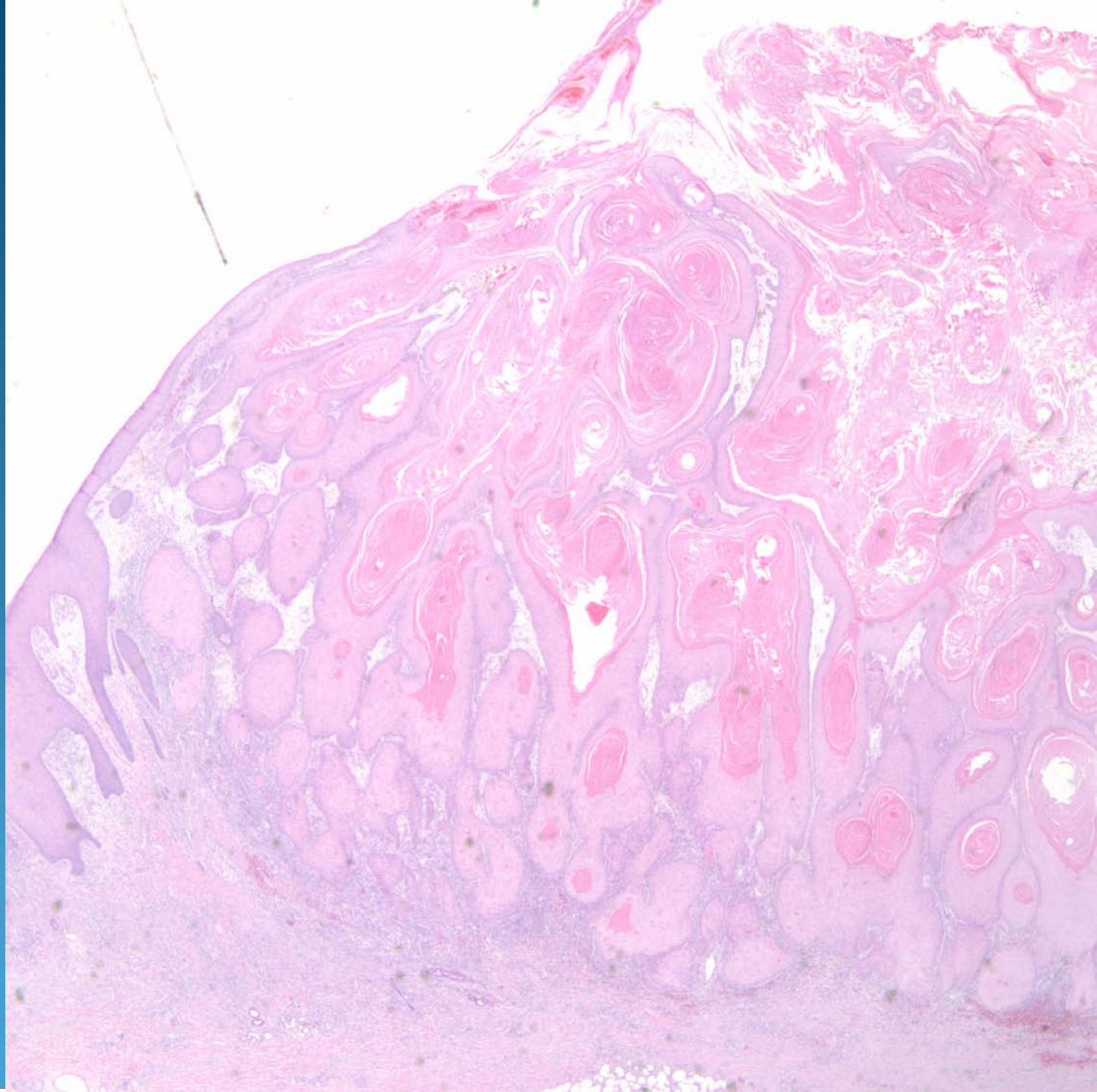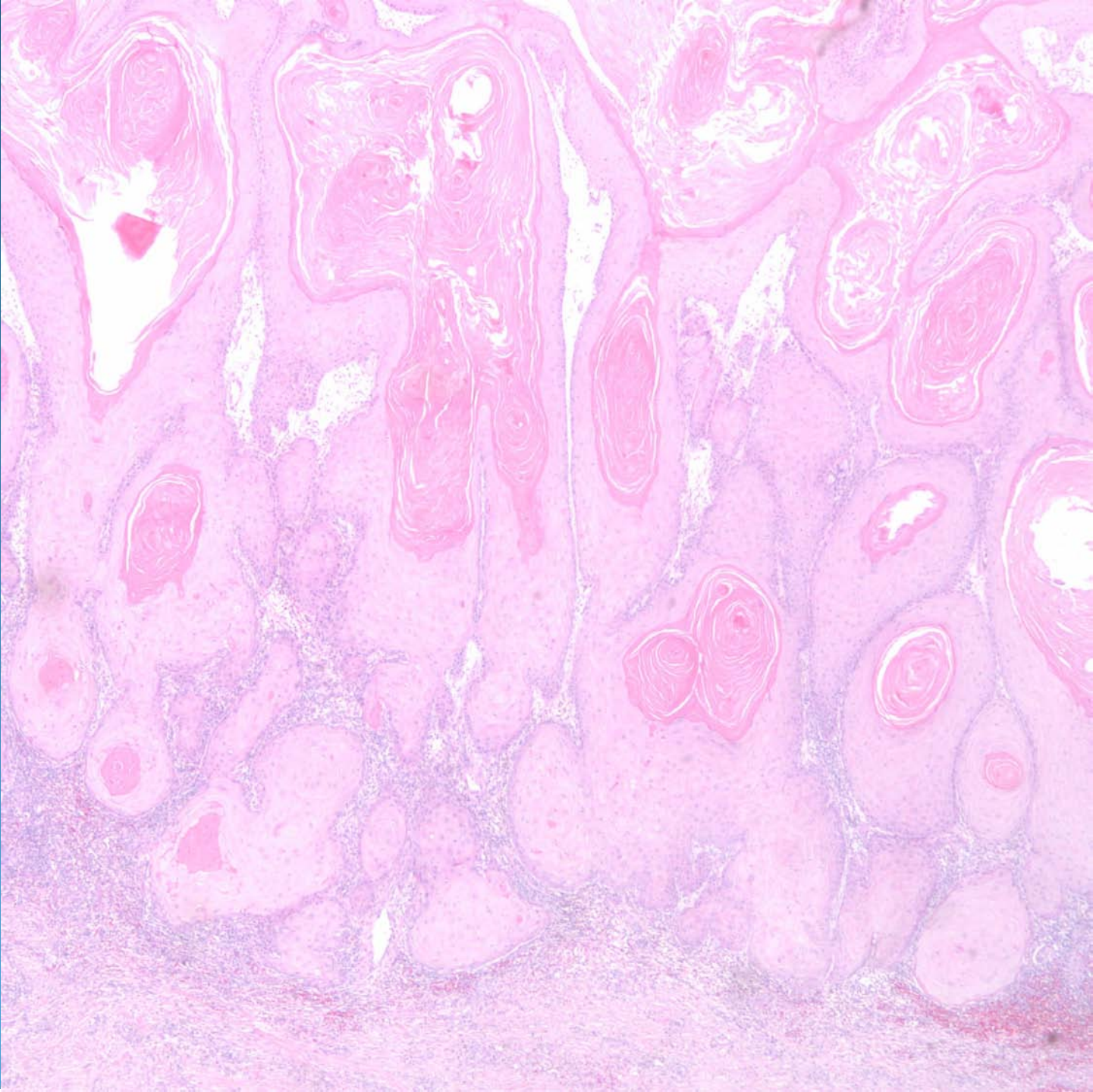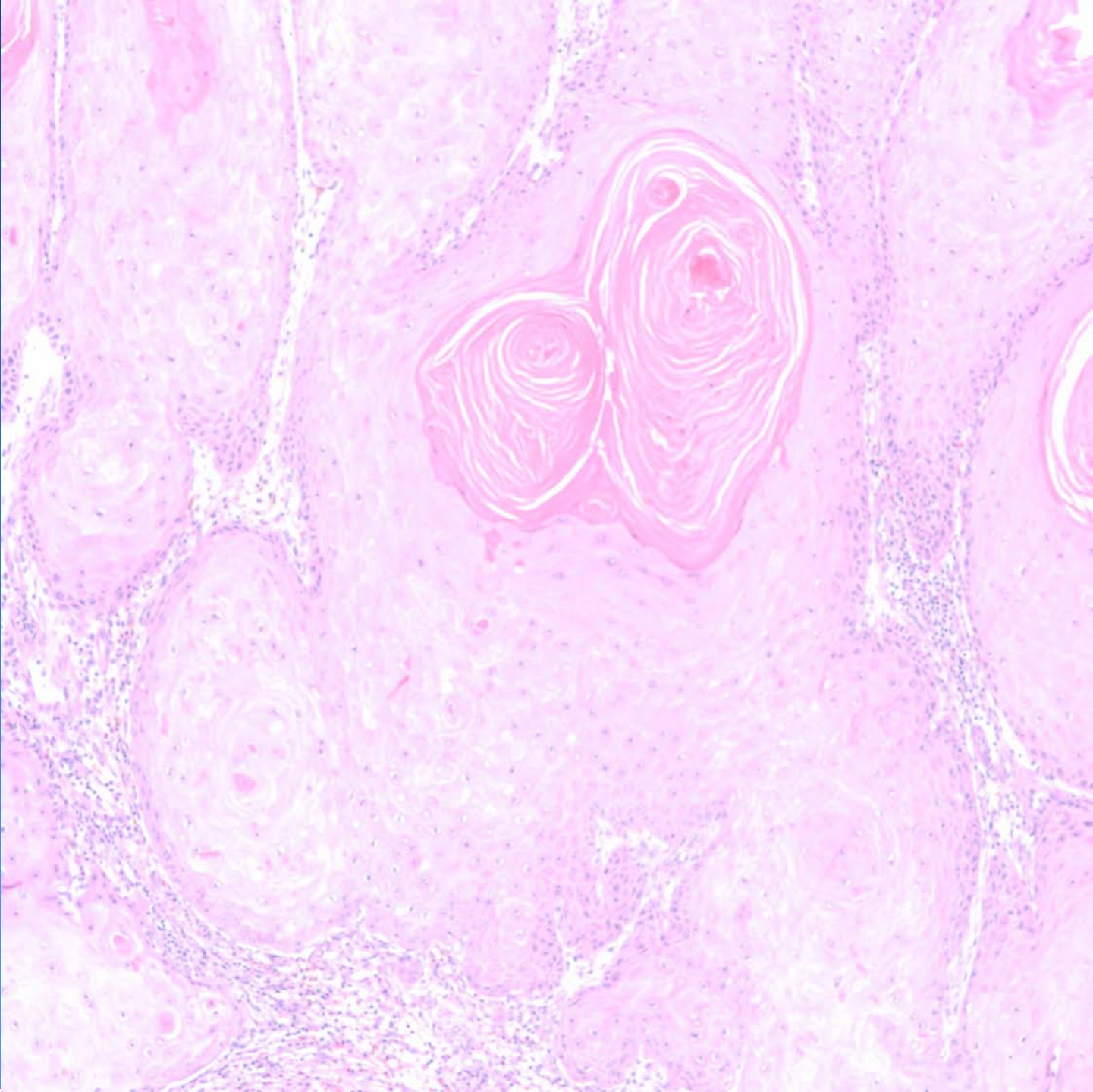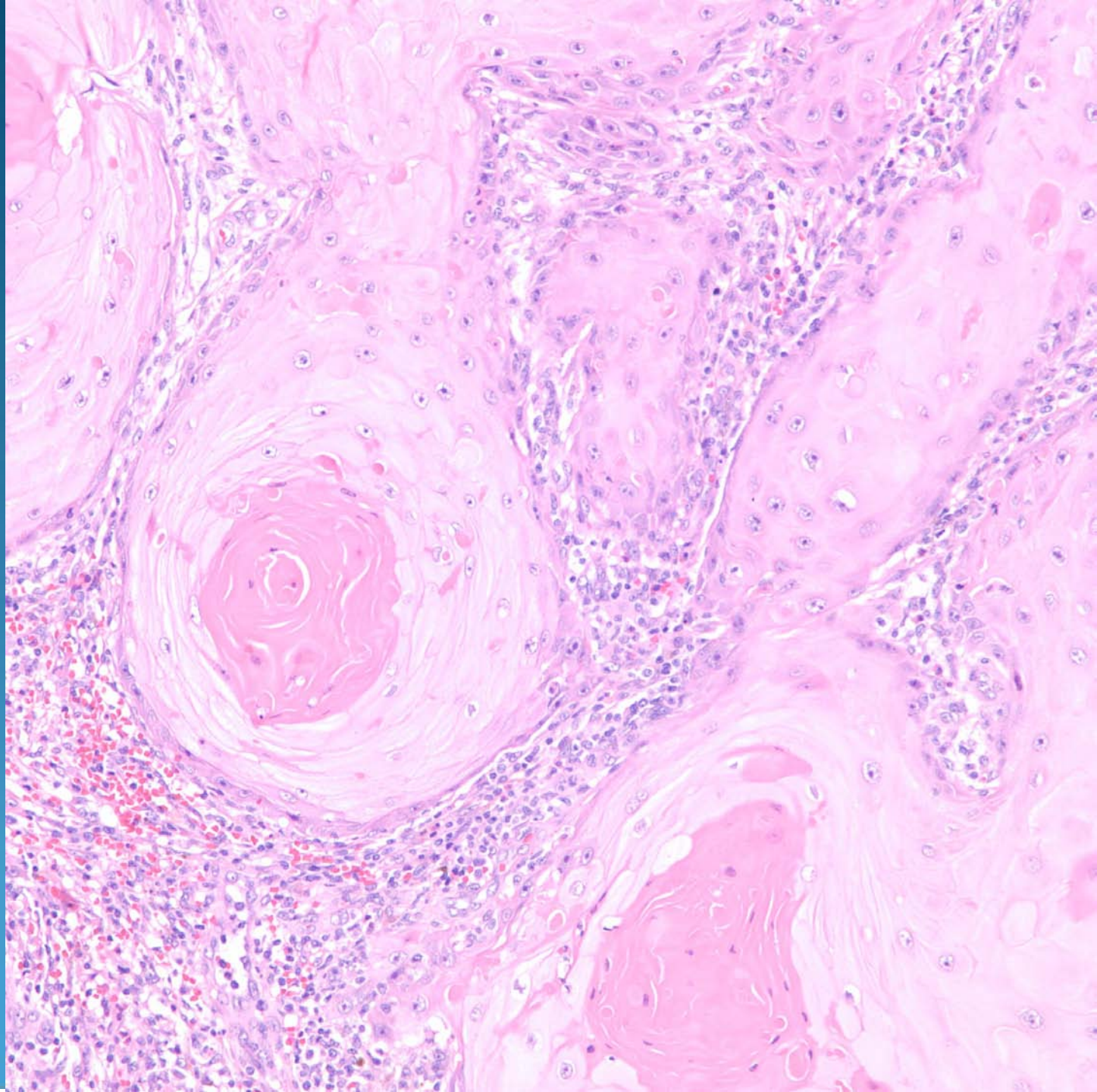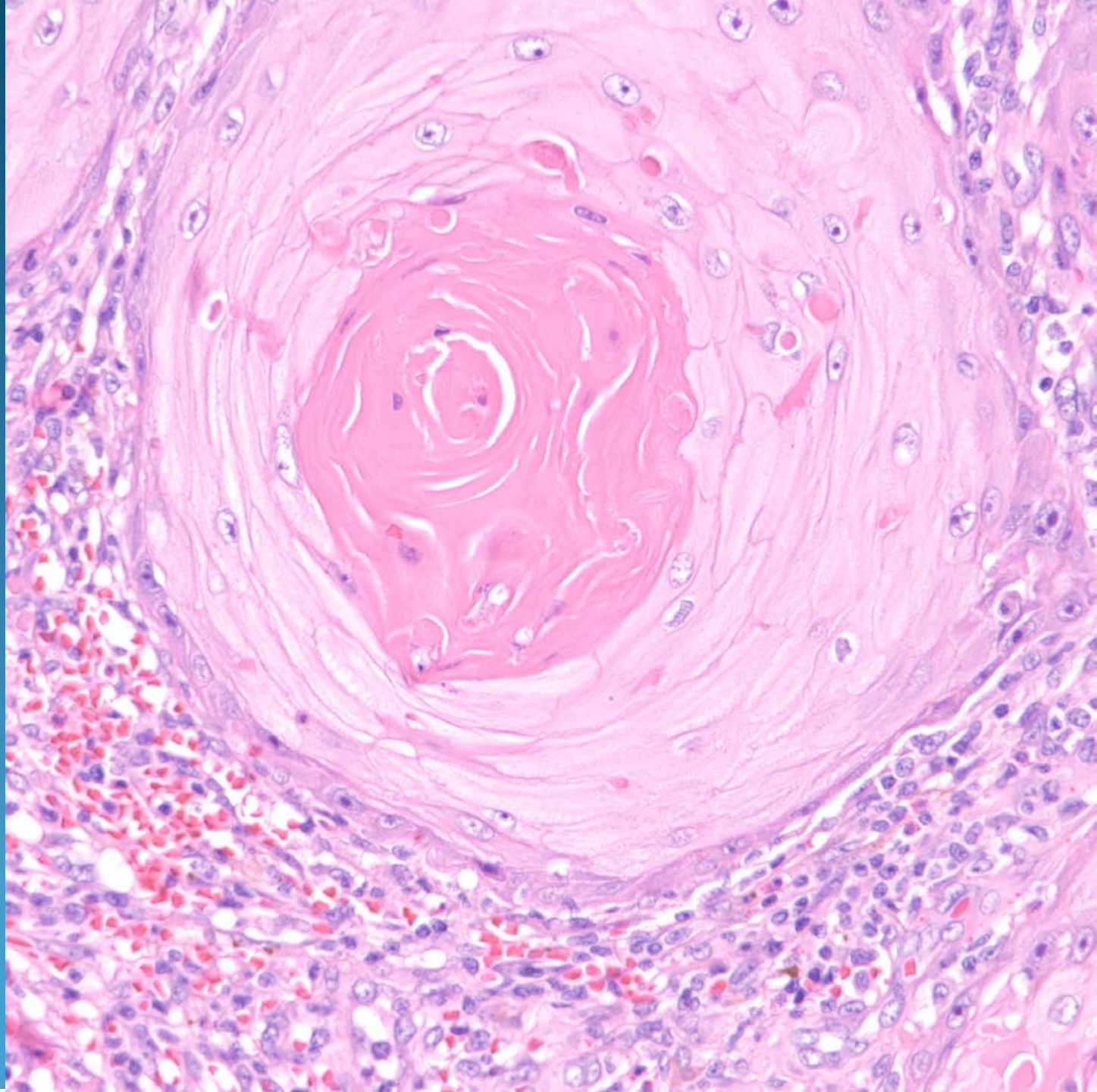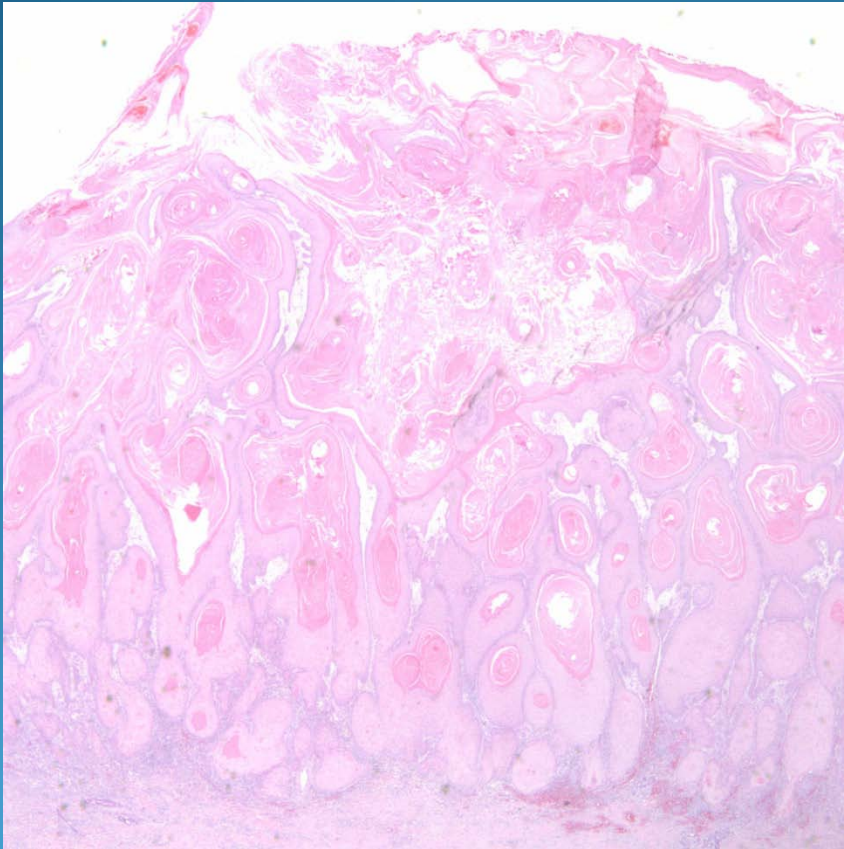


# Keratoacanthoma

# Pearls



- Crateriform architecture forming an epidermal buttress
- Glassy well differentiated keratinocytes and squamous pearl formation