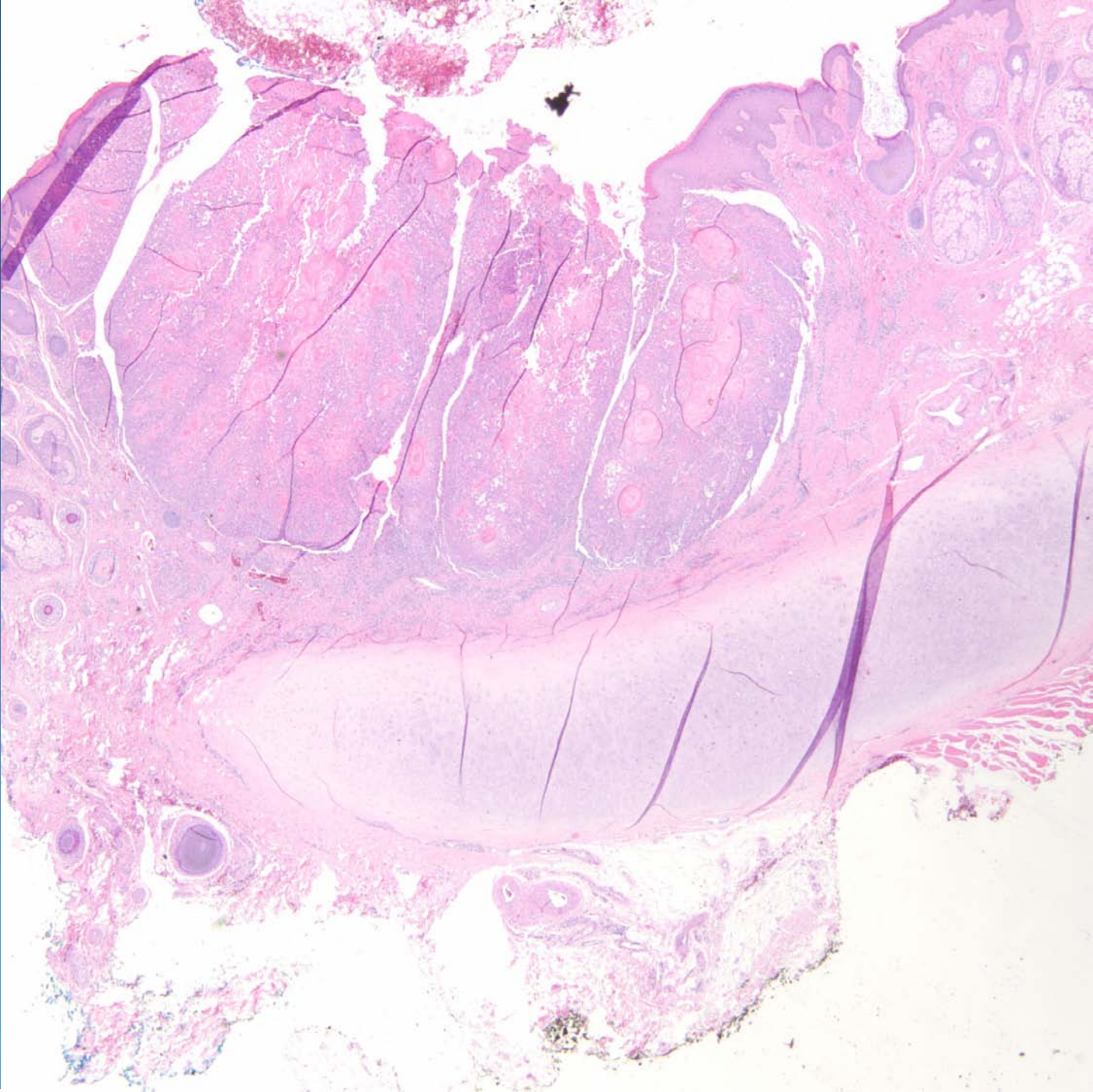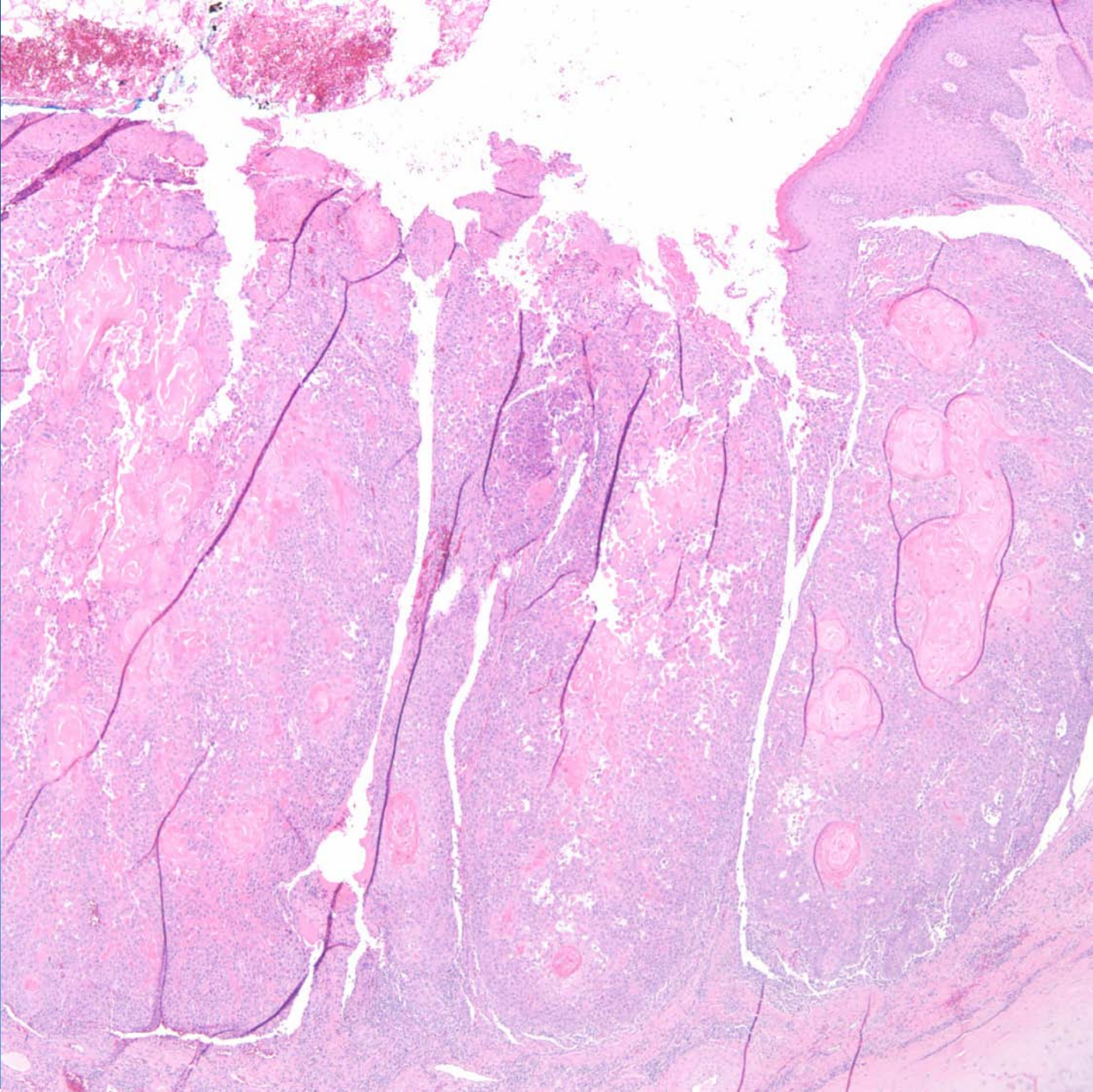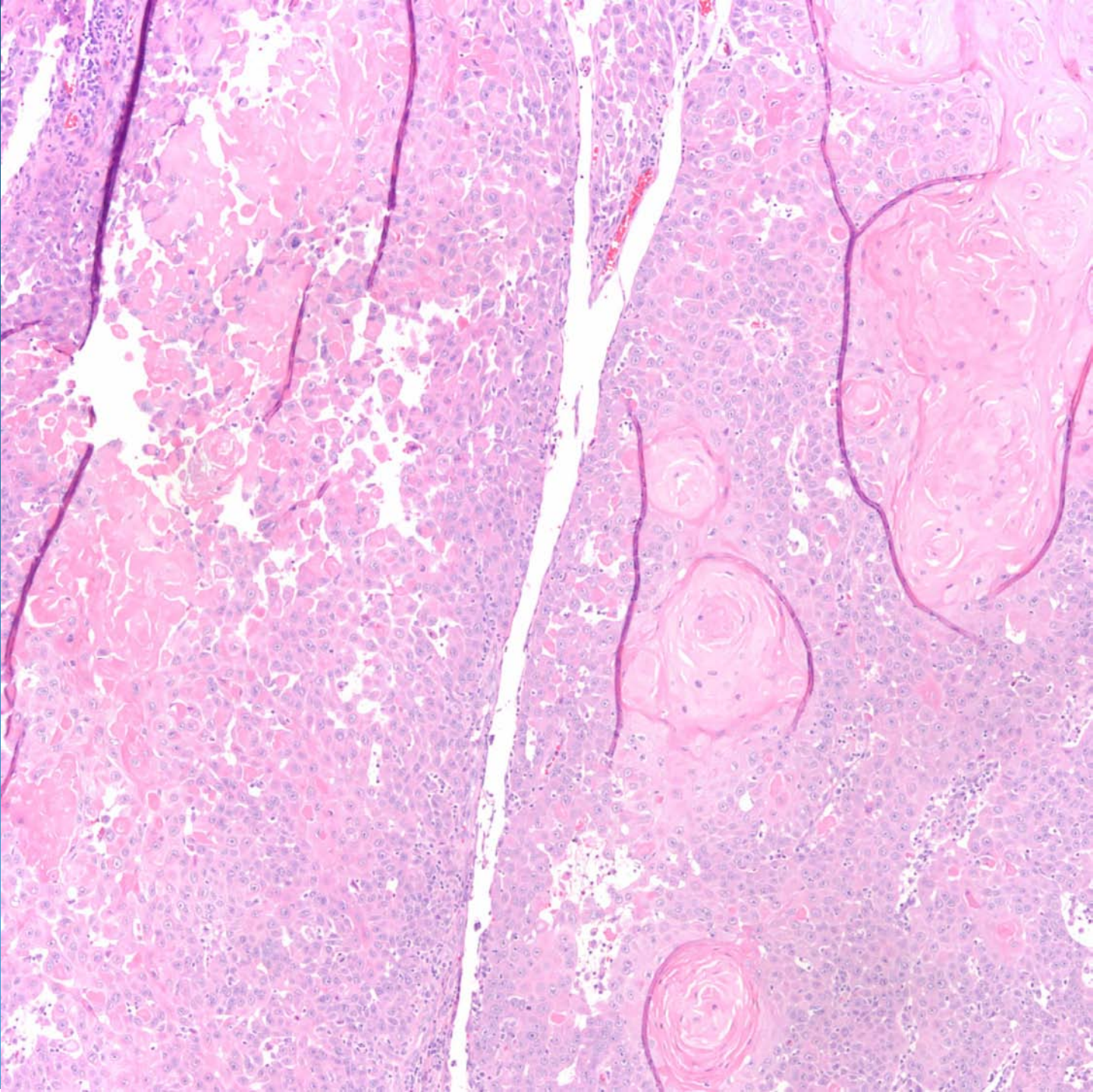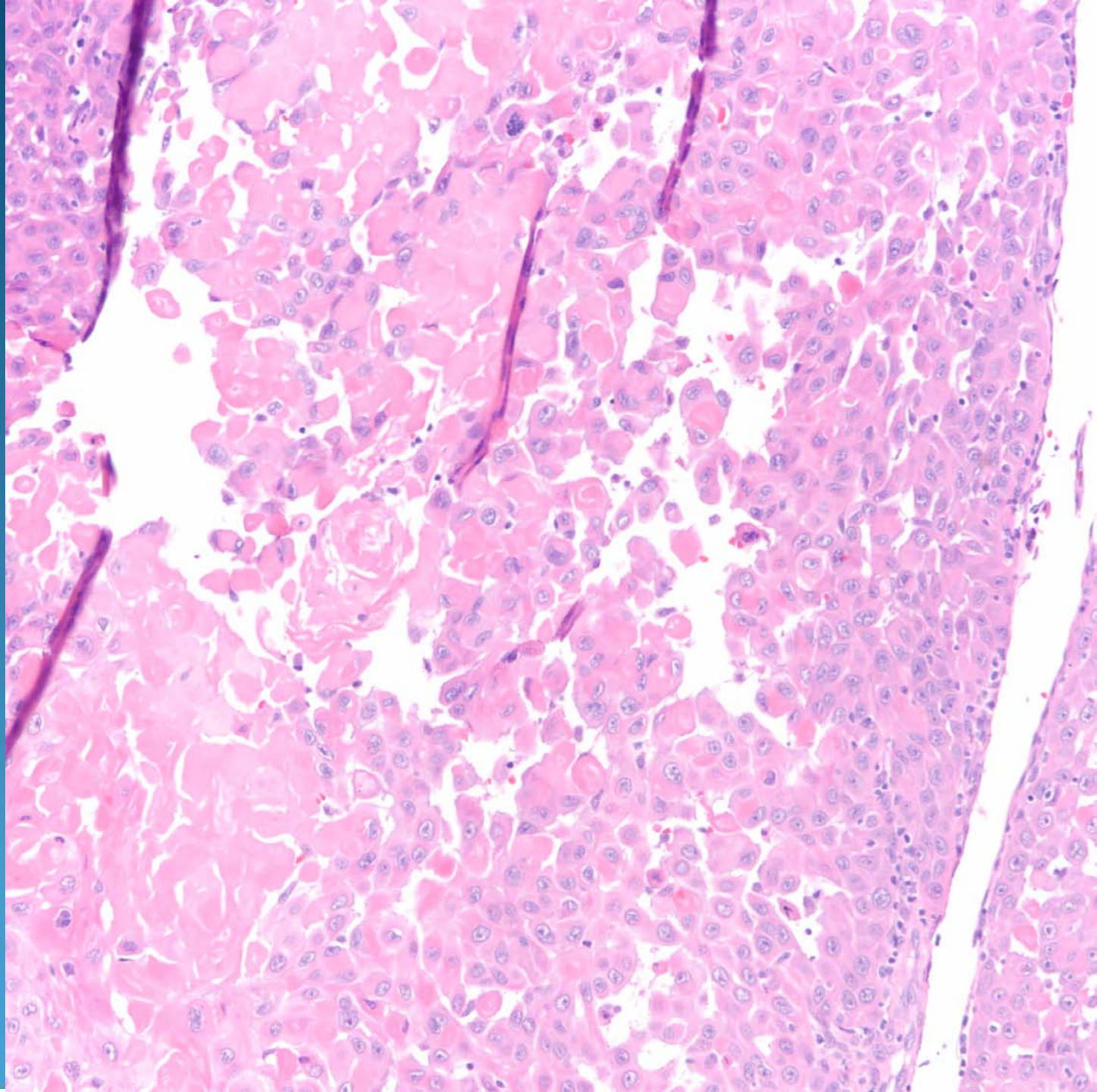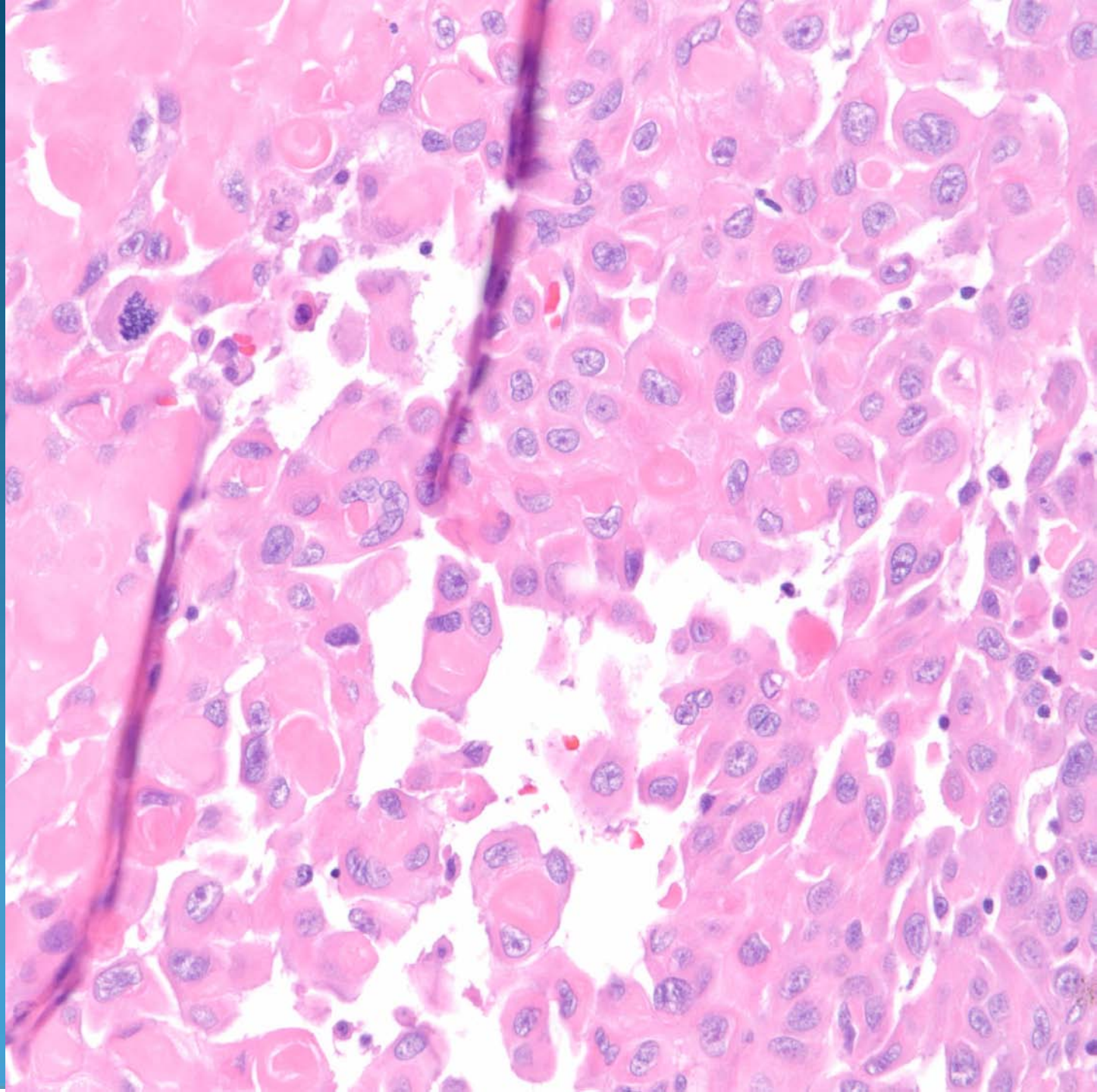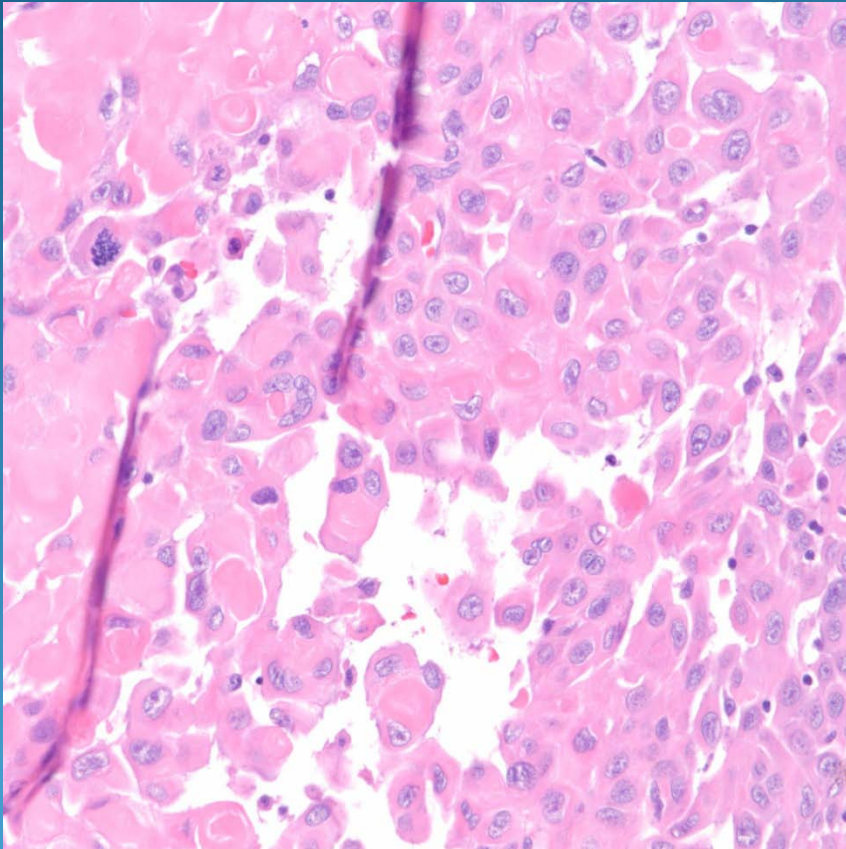


Invasive Squamous Cell Carcinoma with Acantholytic Features

Pearls



- Squamous cell carcinoma with discohesion between malignant keratinocytes
- Invasive pattern with squamous pearls and dyskeratosis
- Look for cytologically malignant keratinocytes