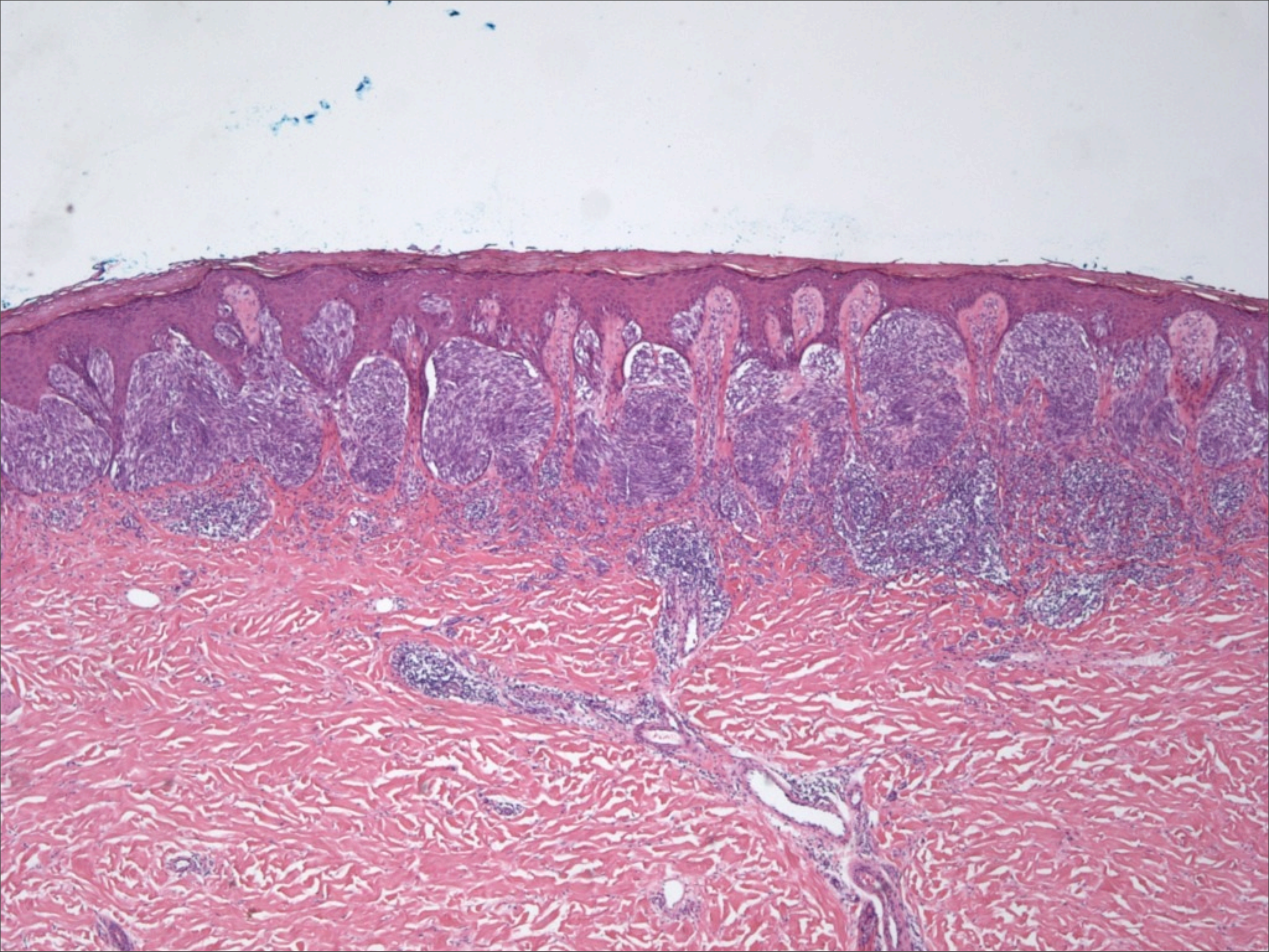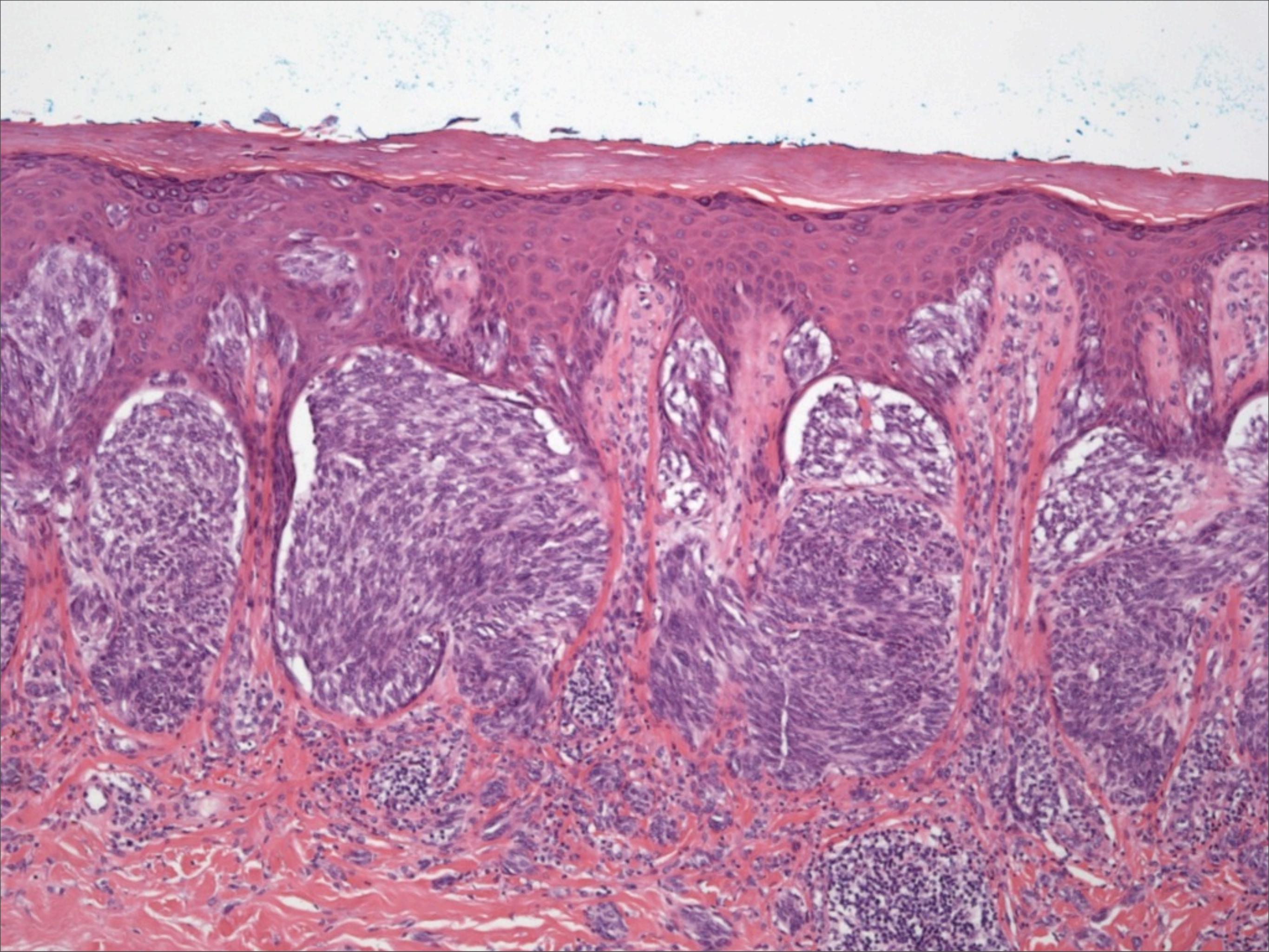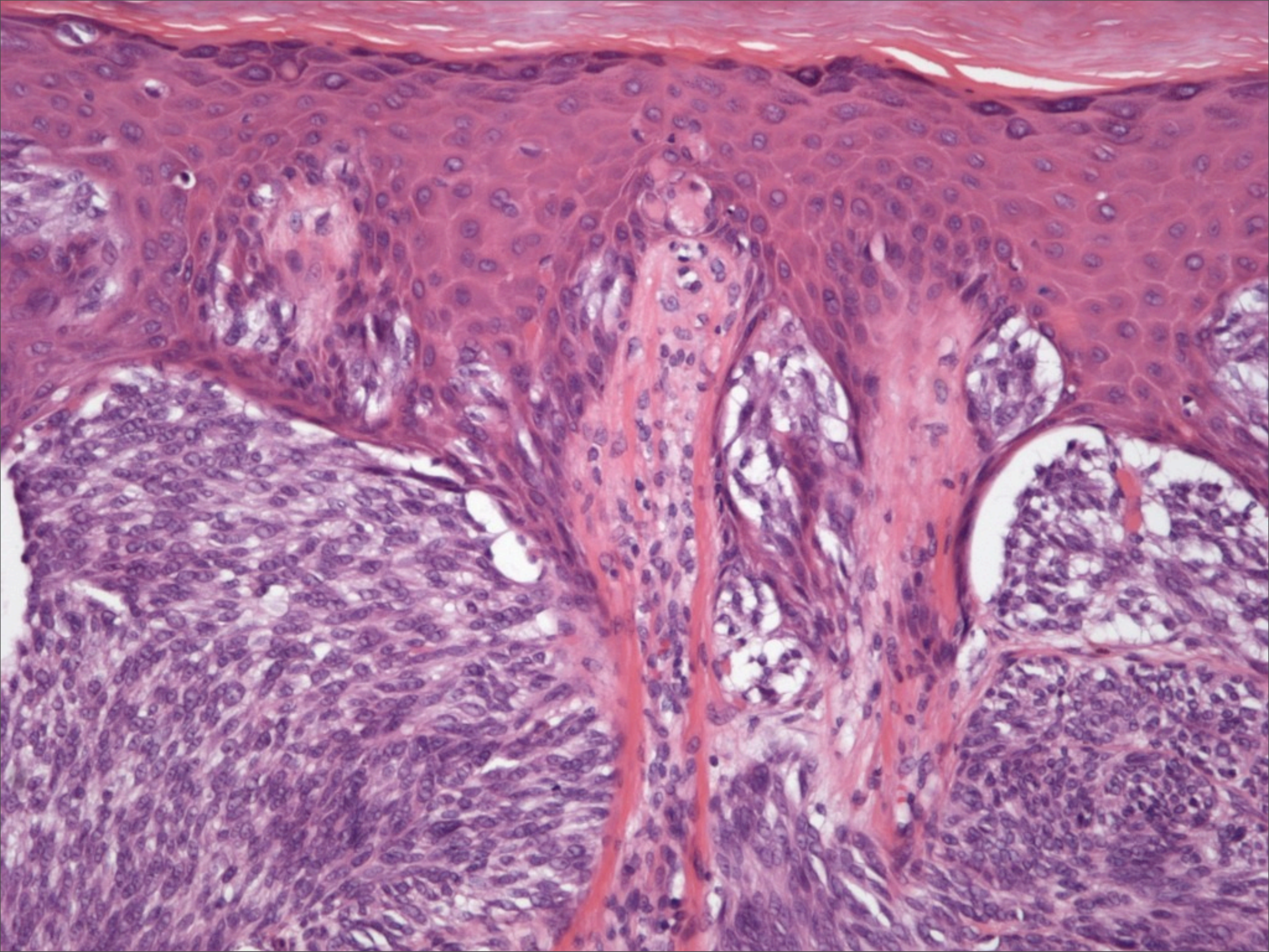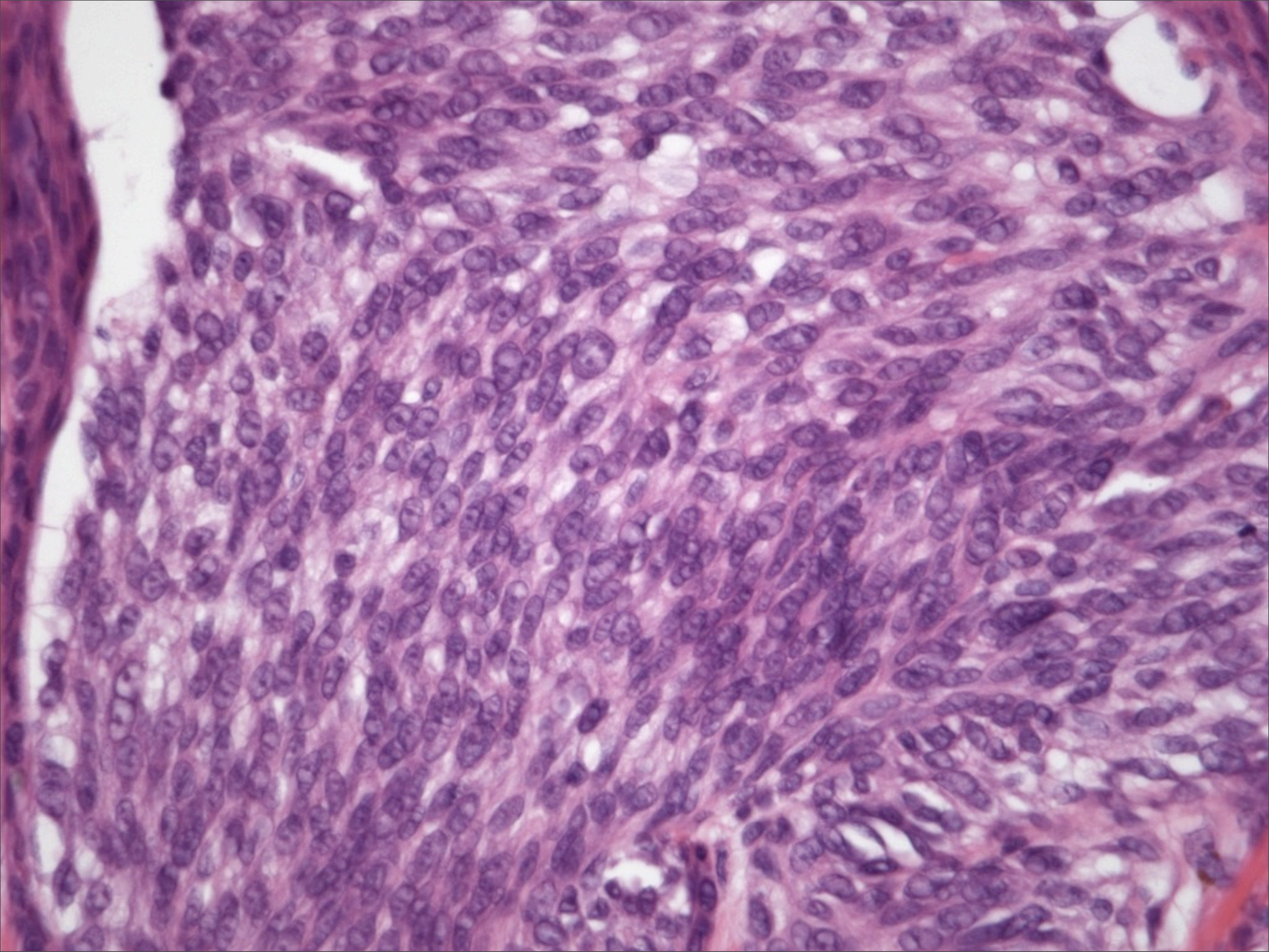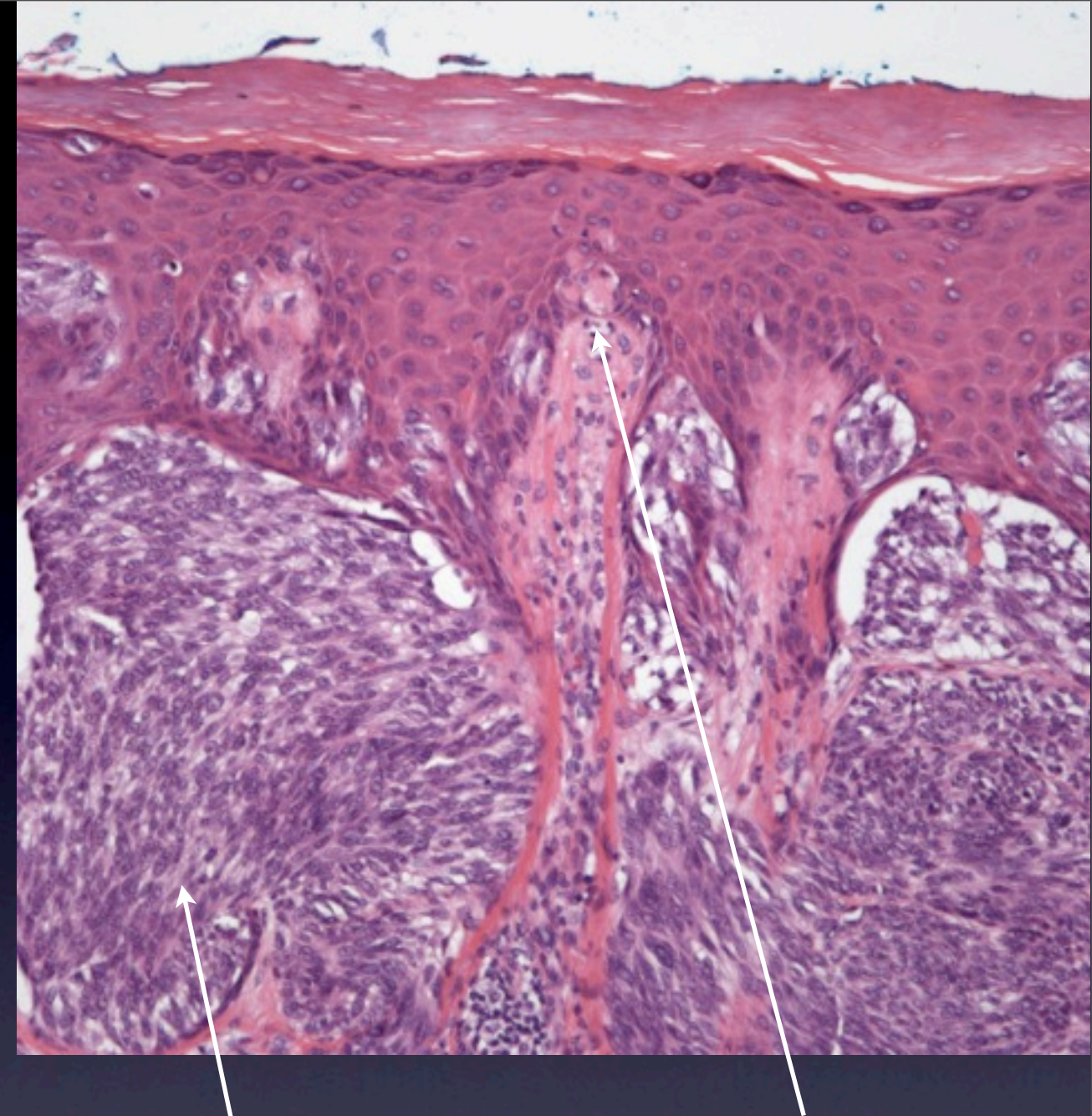
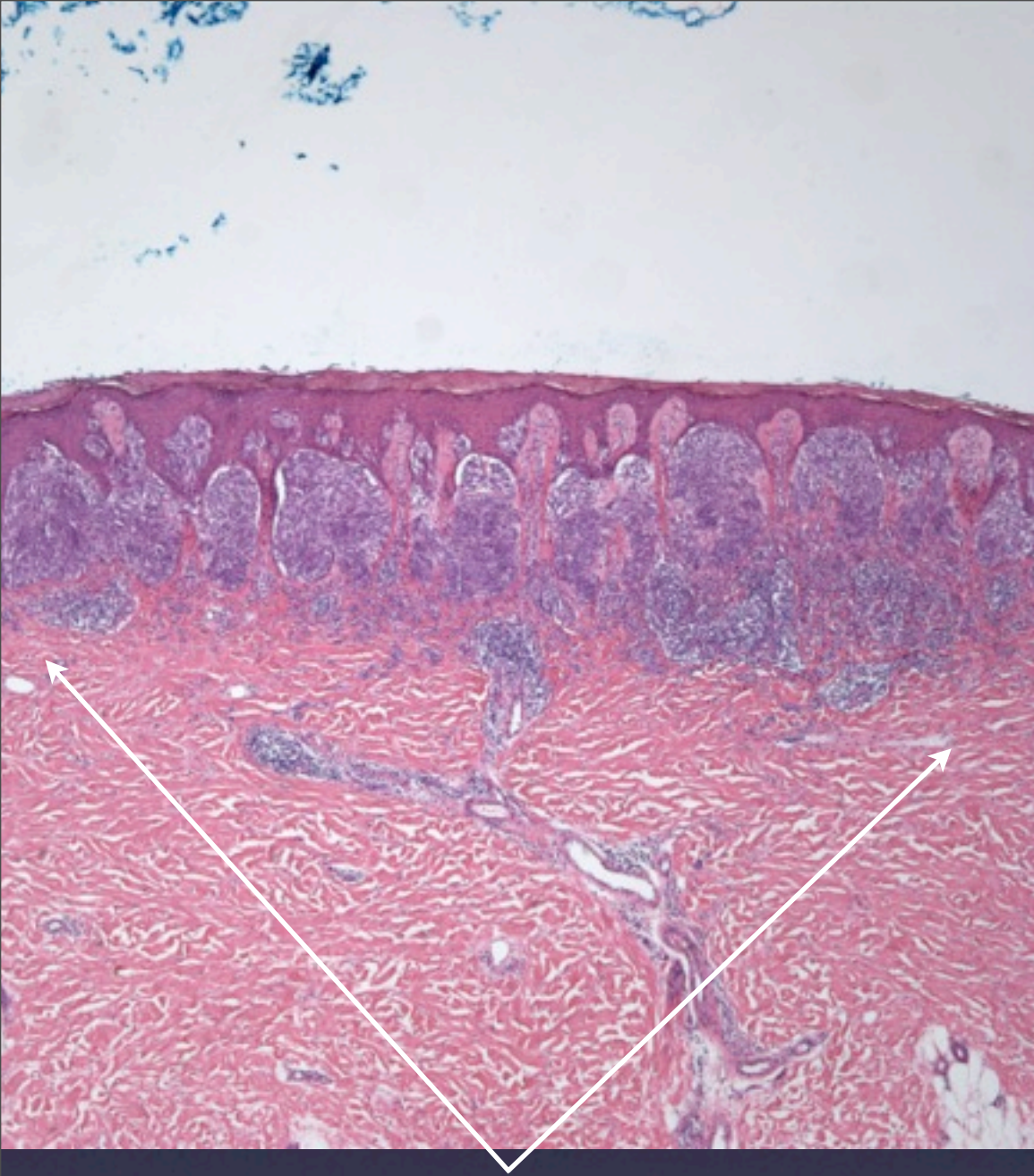


Spitz Nevus



Sharp peripheral
circumscription

Maturation of melanocytes

Kamino bodies

Streaming of
junctional nests