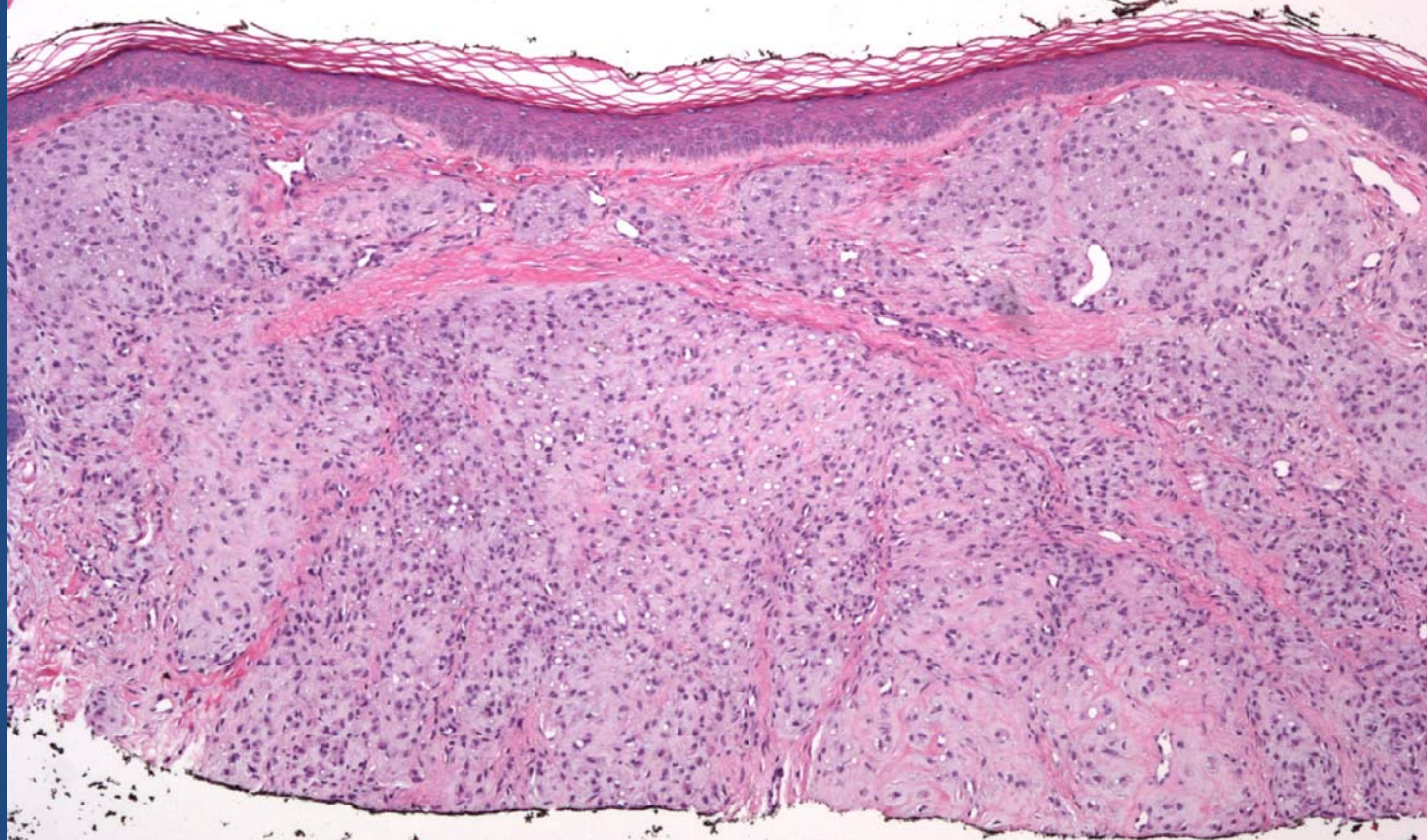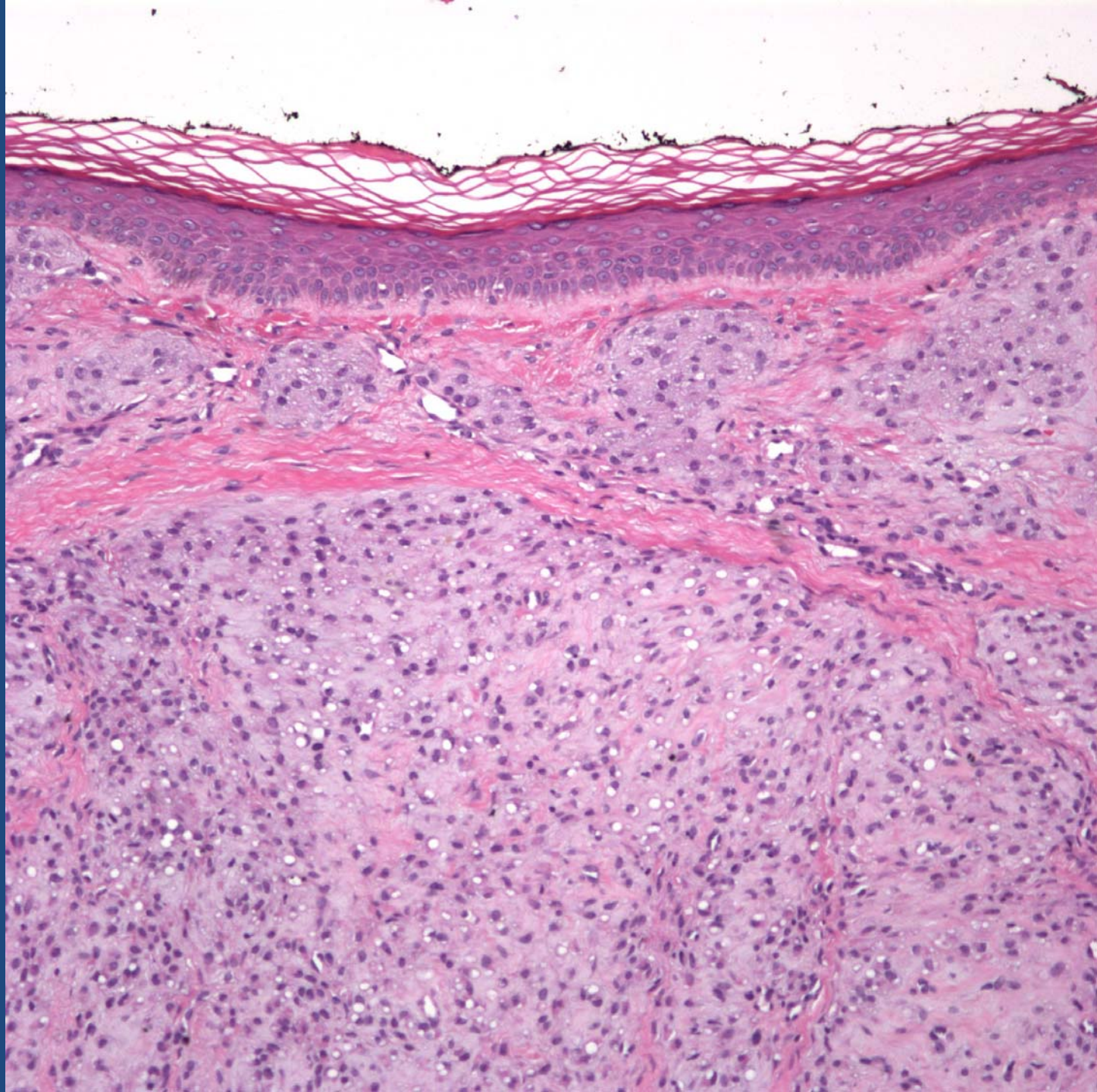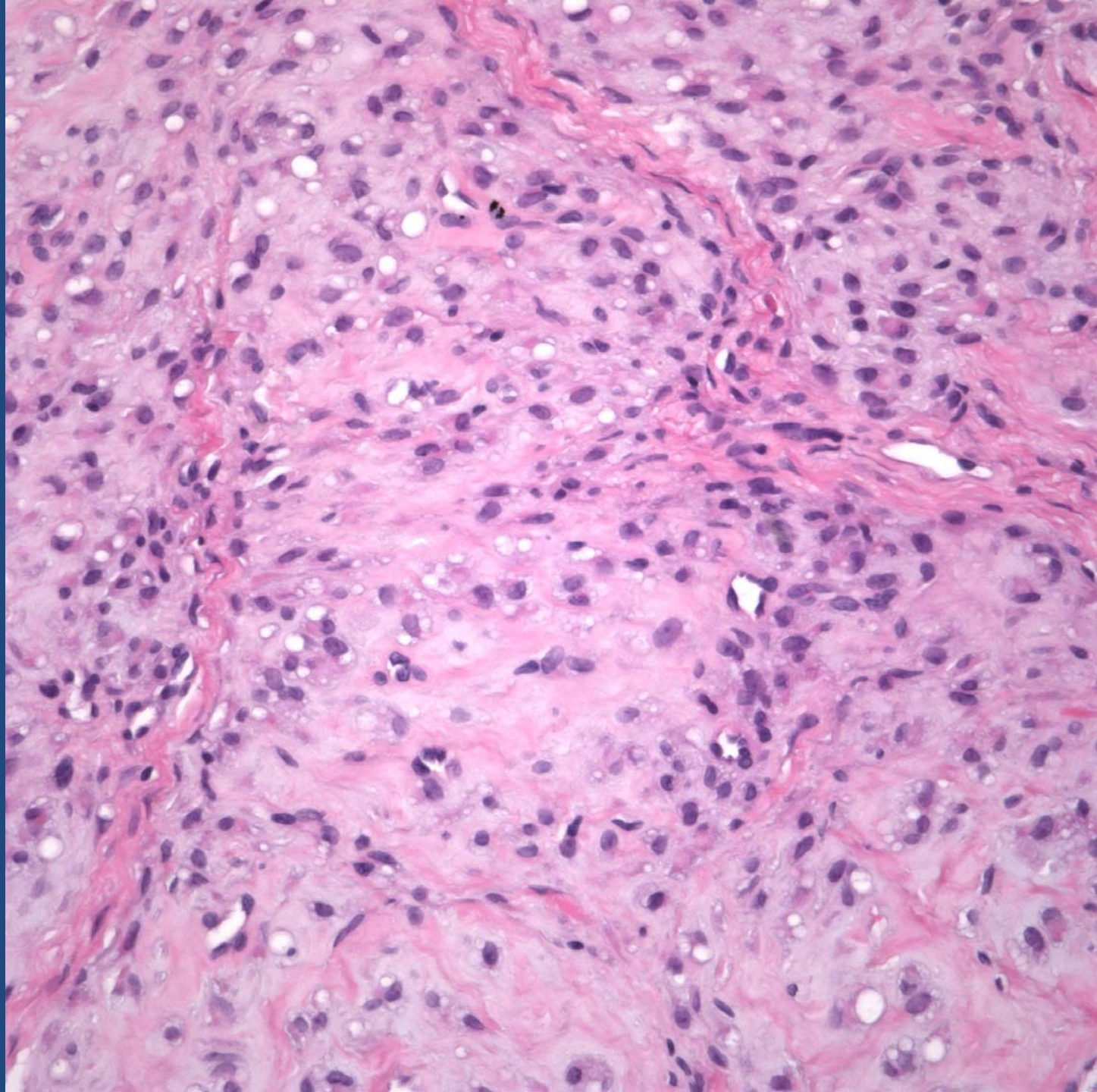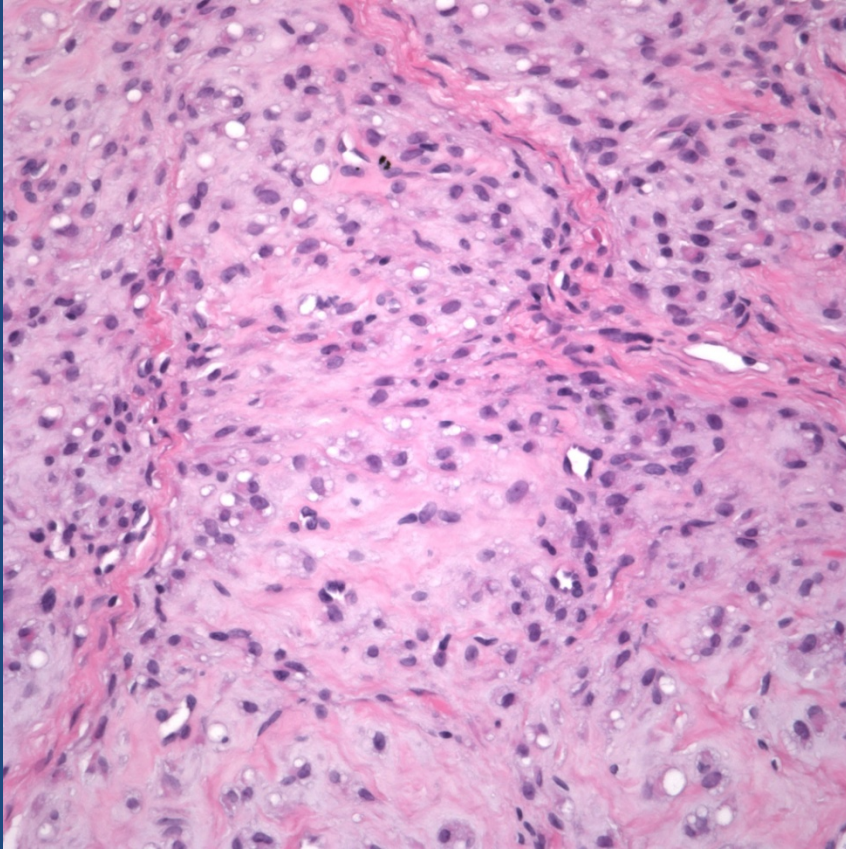


Chondroid Tumor Consistent with  
Superficial Portion of Chondroid  
Syringoma

# Pearls



- Dermal based tumor exhibiting characteristic nesting of bland chondrocytes
- Look for lacunae
- Lobular architecture of cartilaginous nests
- Rule out underlying salivary gland tumor, metaplastic change in BCC, nevi, etc.