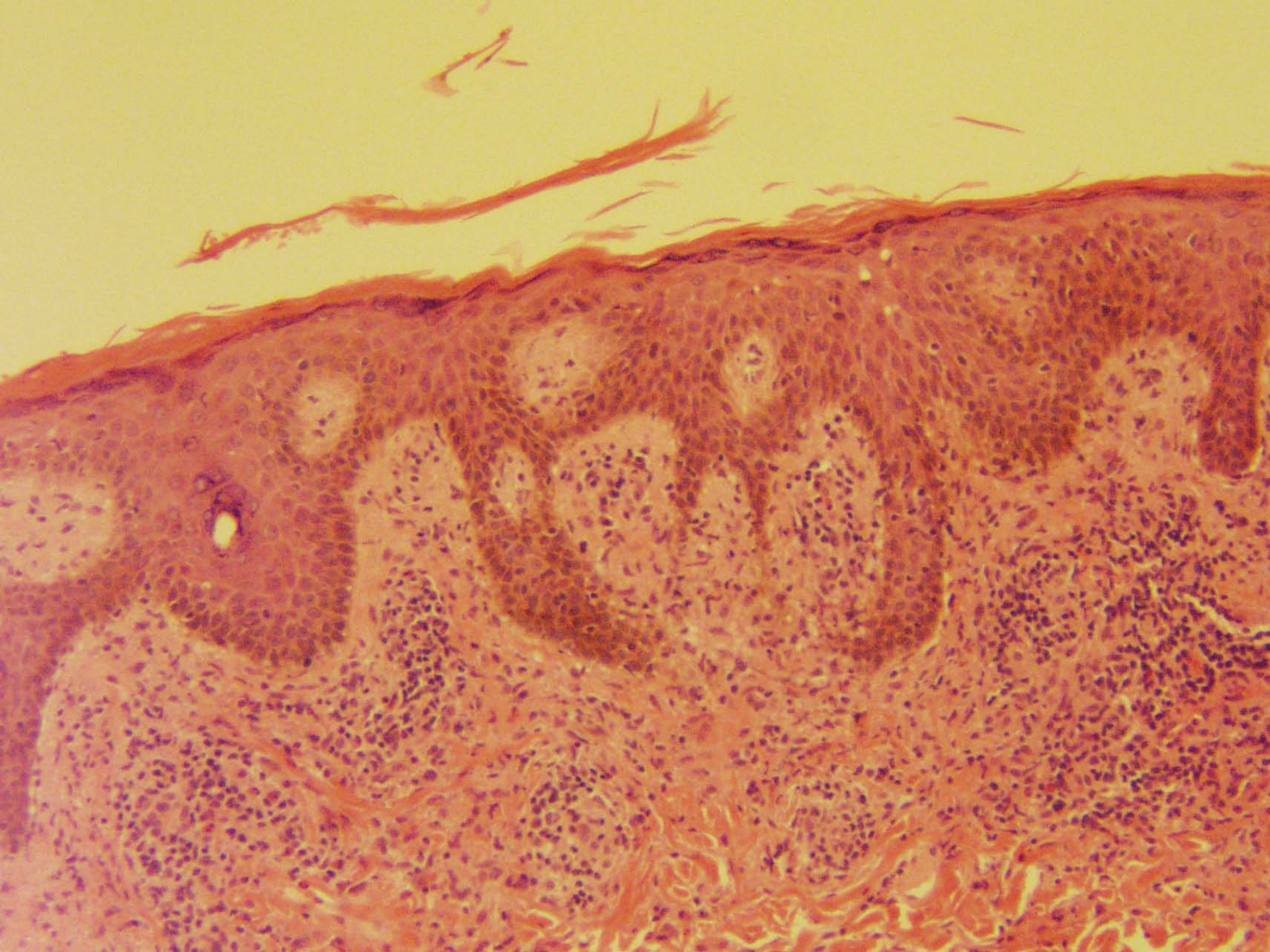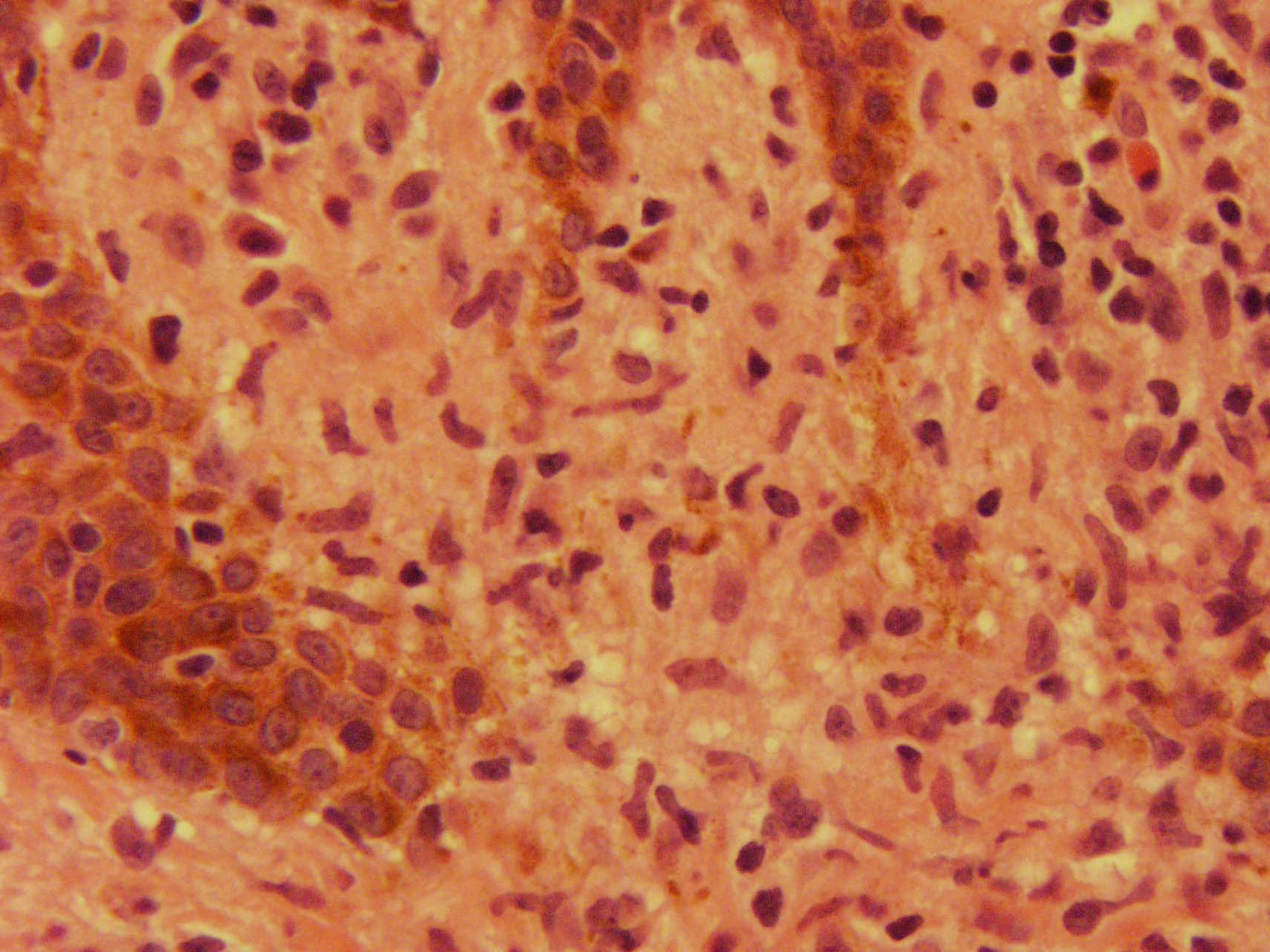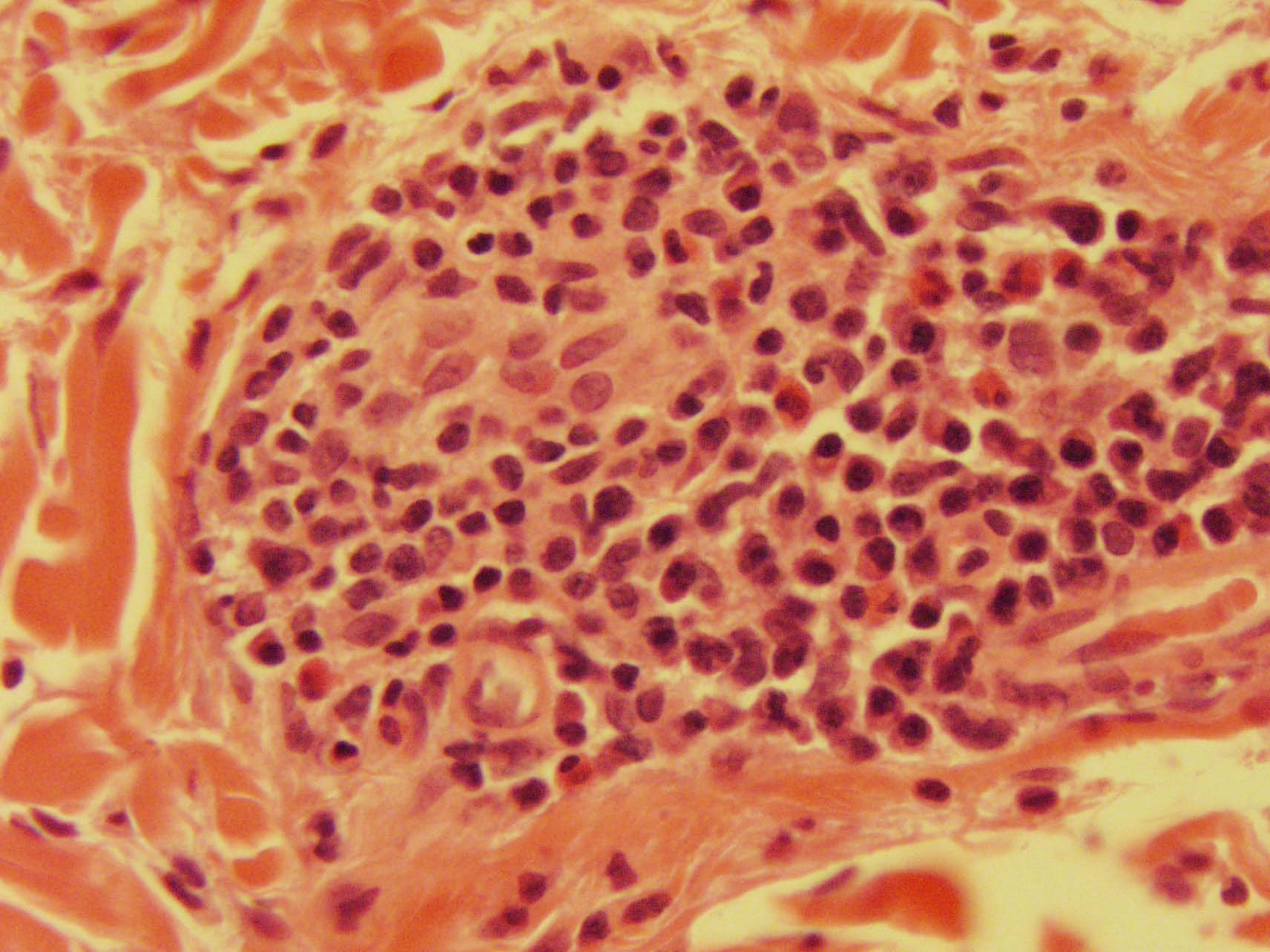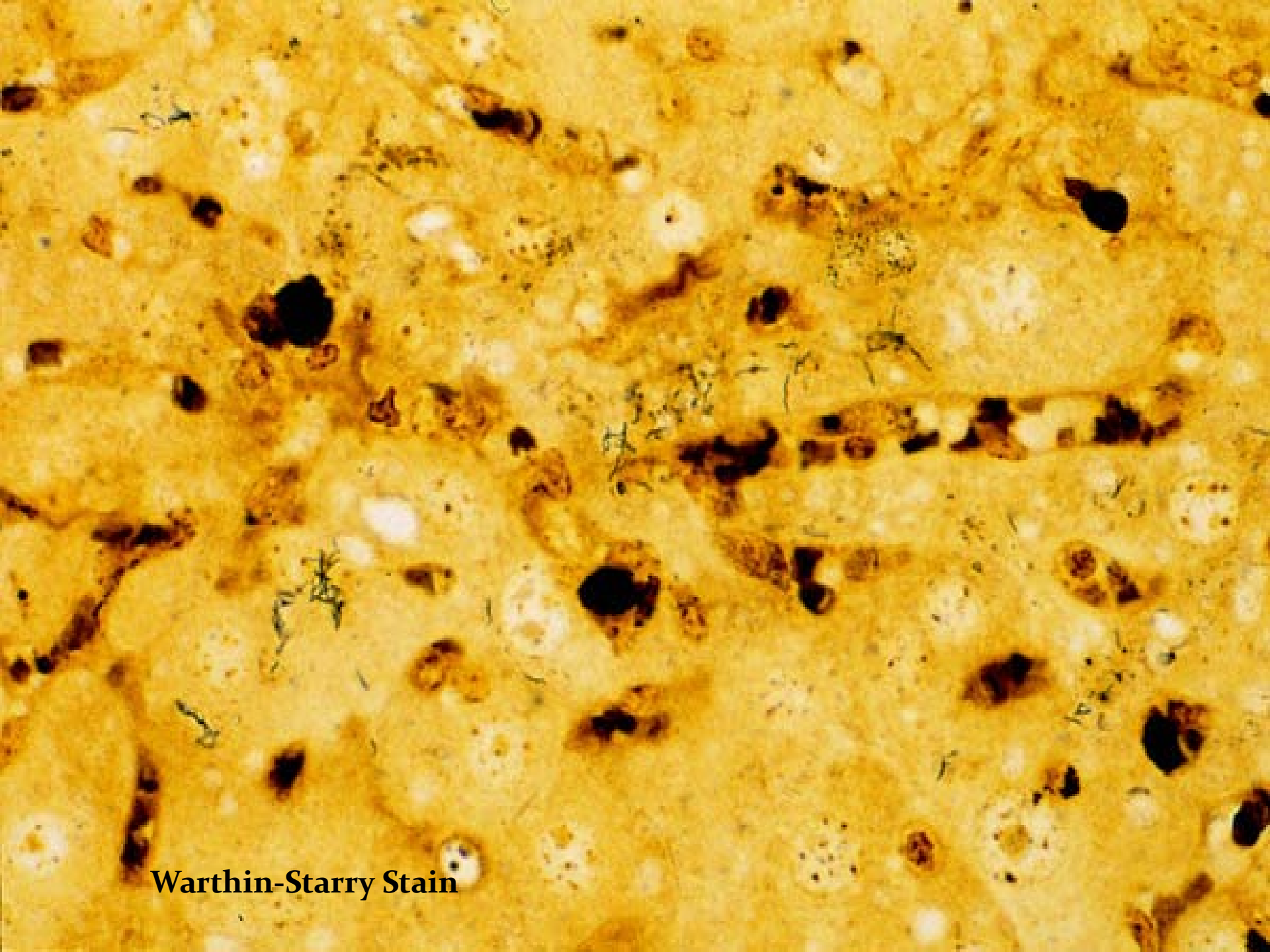


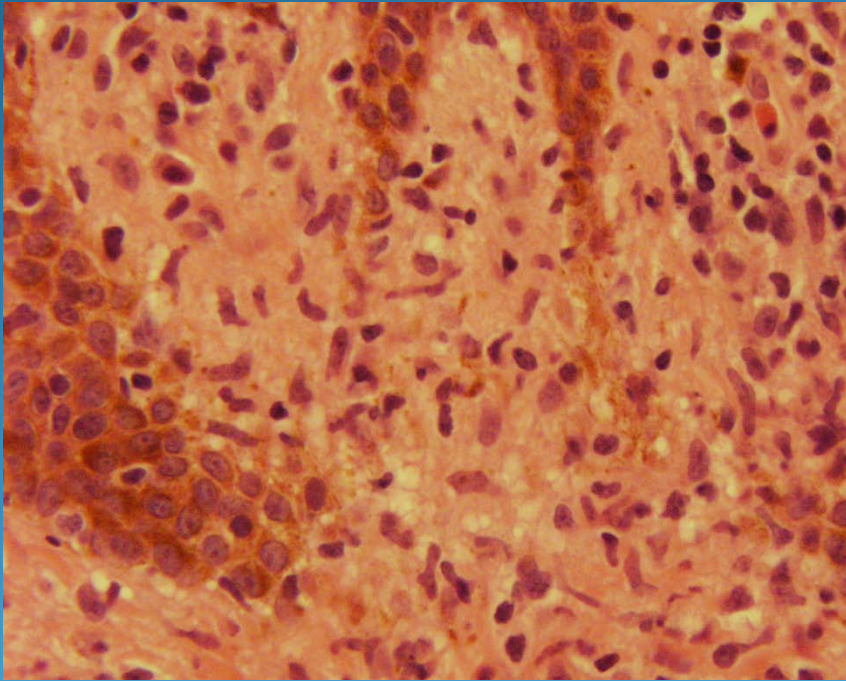
# Secondary Syphilis



**Warthin-Starry Stain**



# Pearls



- Lichenoid dermatitis with numerous plasma cells
- Beware! Plasma cells normally seen in mucosa and scalp
- May also present with granulomas or psoriasiform