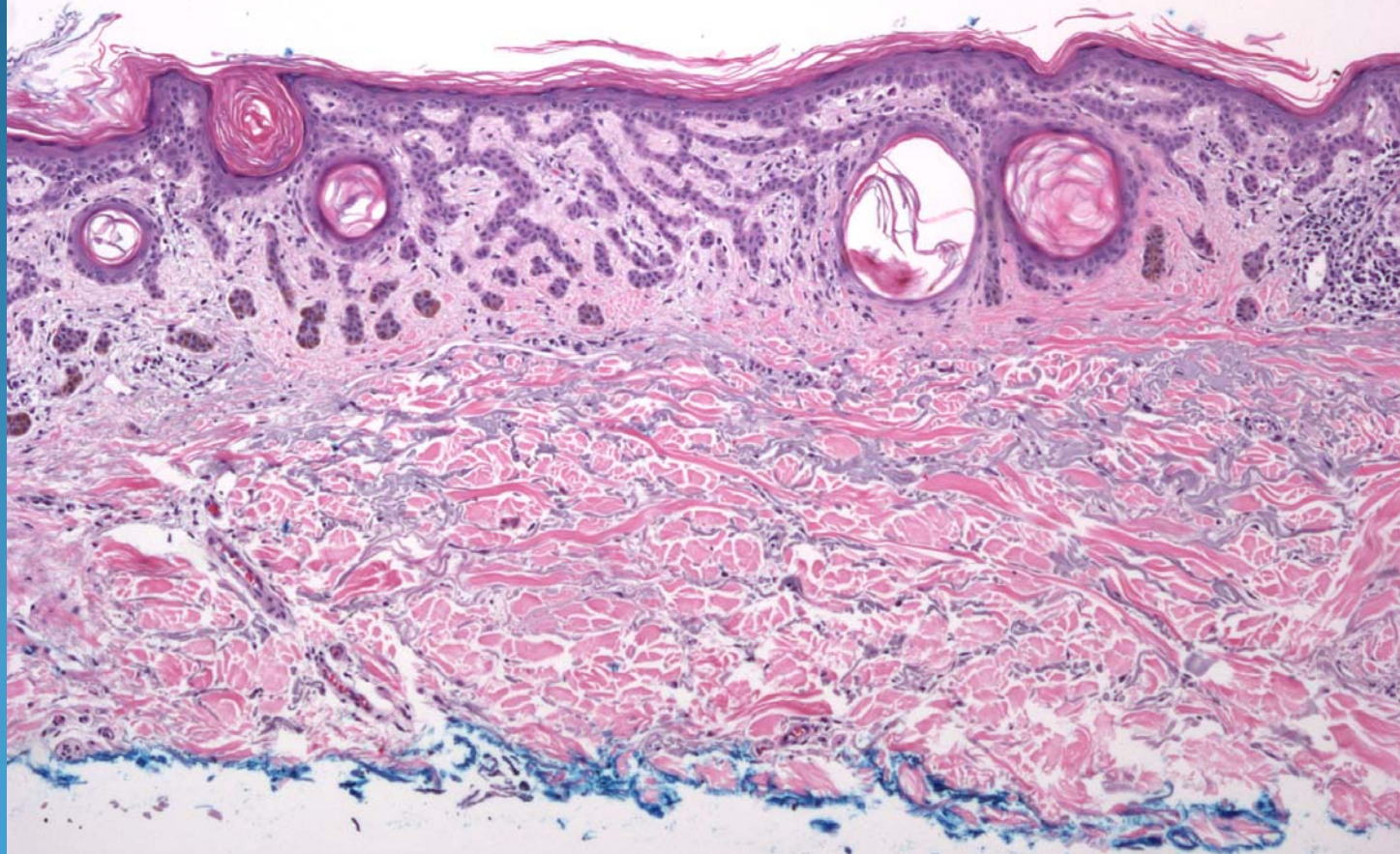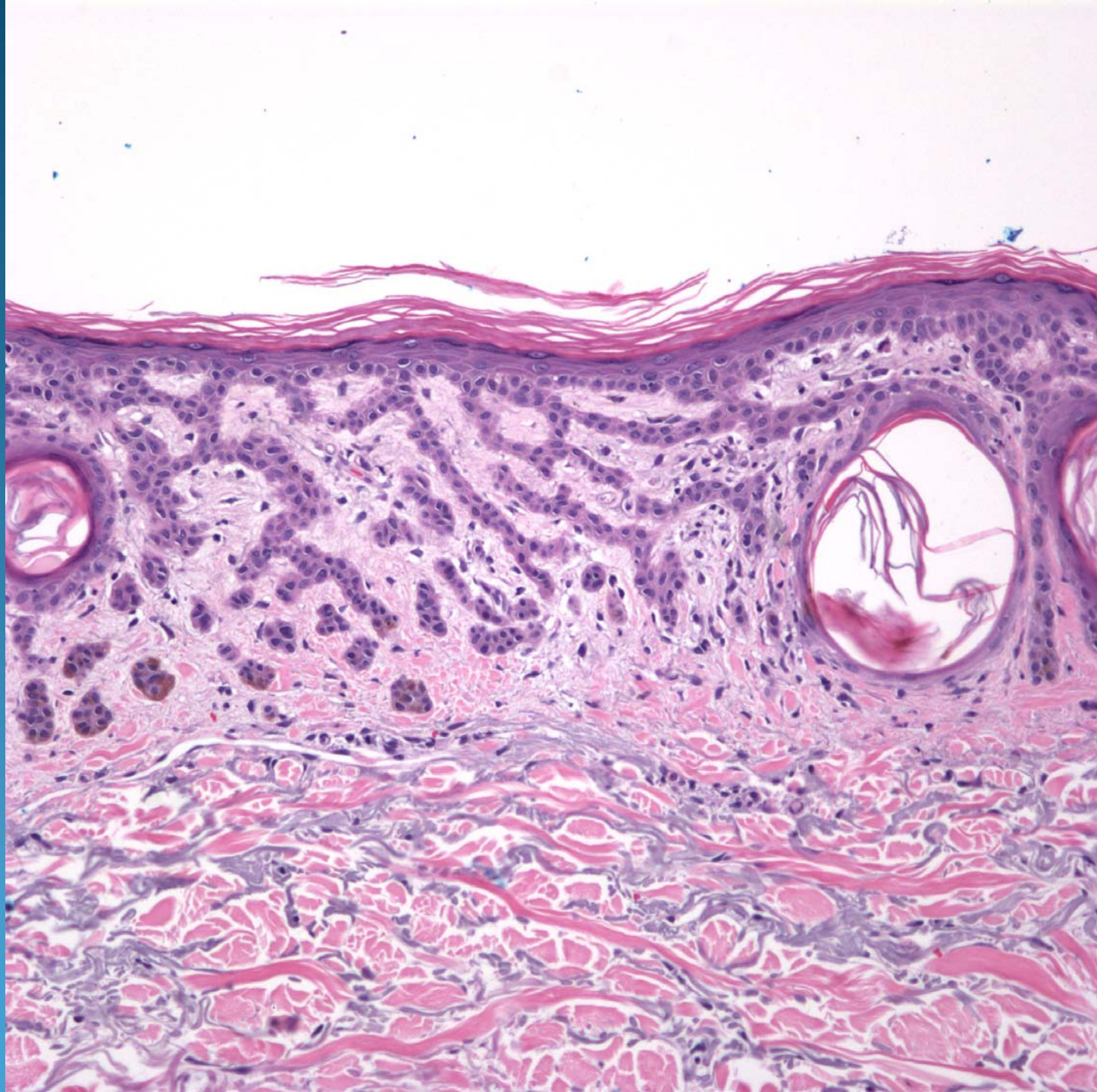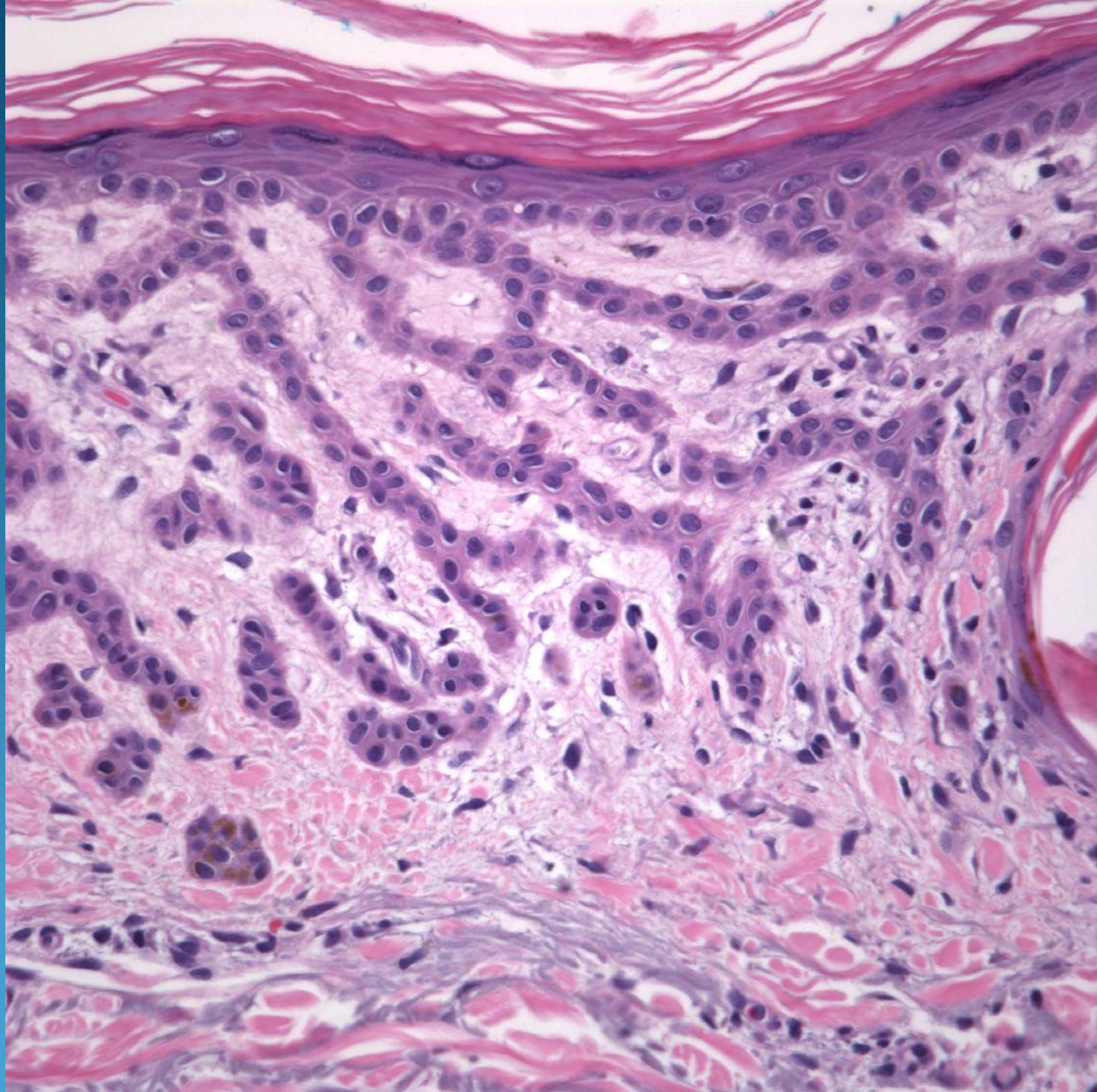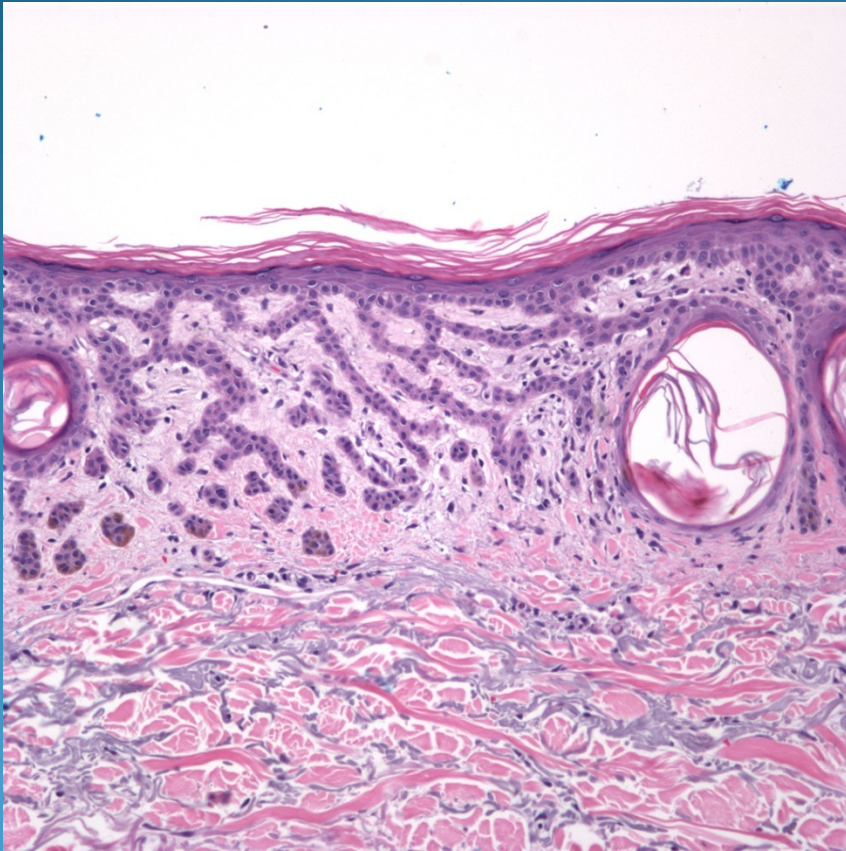


Seborrheic Keratosis, Reticulated Type

Pearls



- Classic outline of seborrheic keratosis
- Filigree-like pattern of rete ridges with interanastomoses
- No atypia
- May have melanin pigmentation