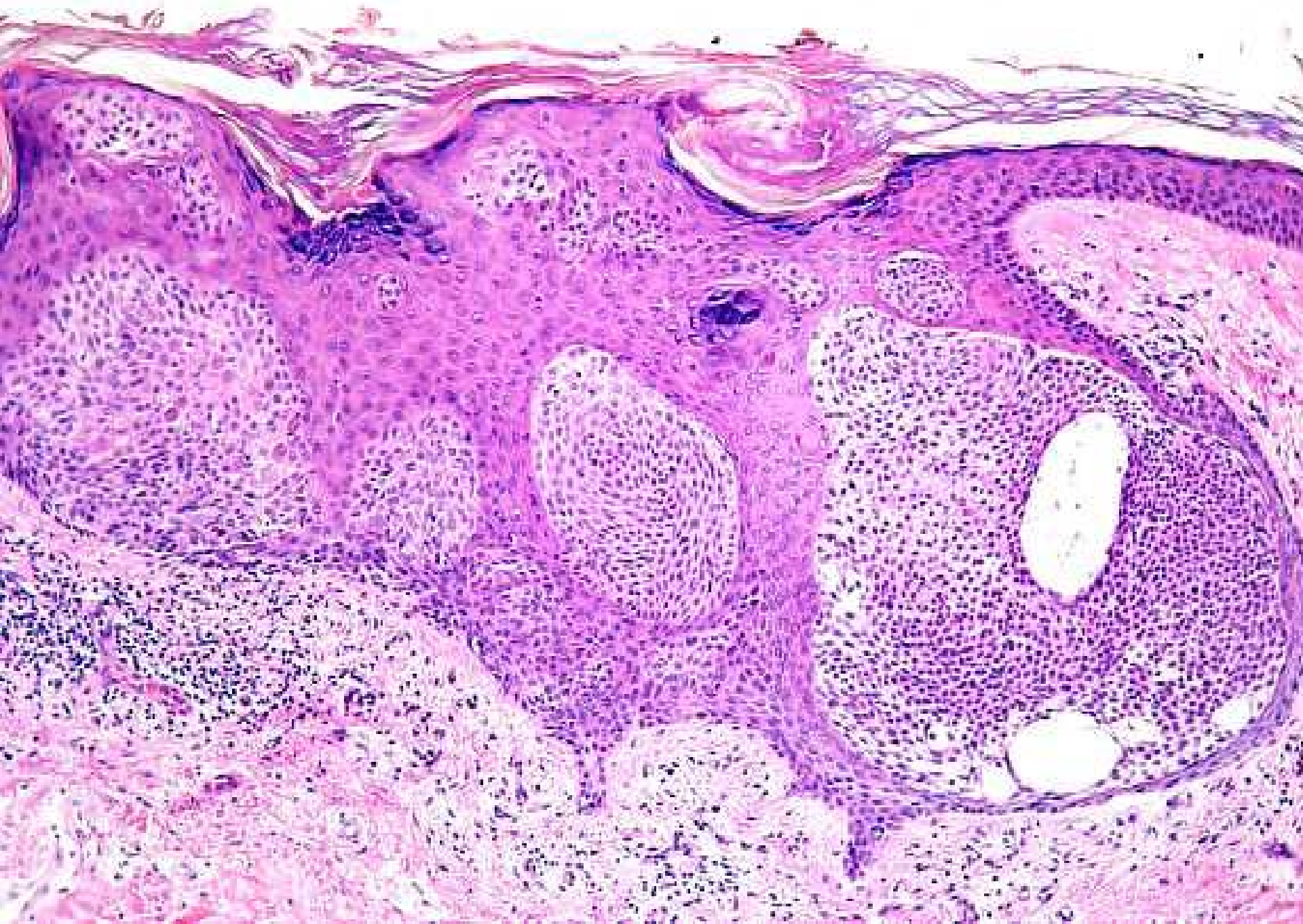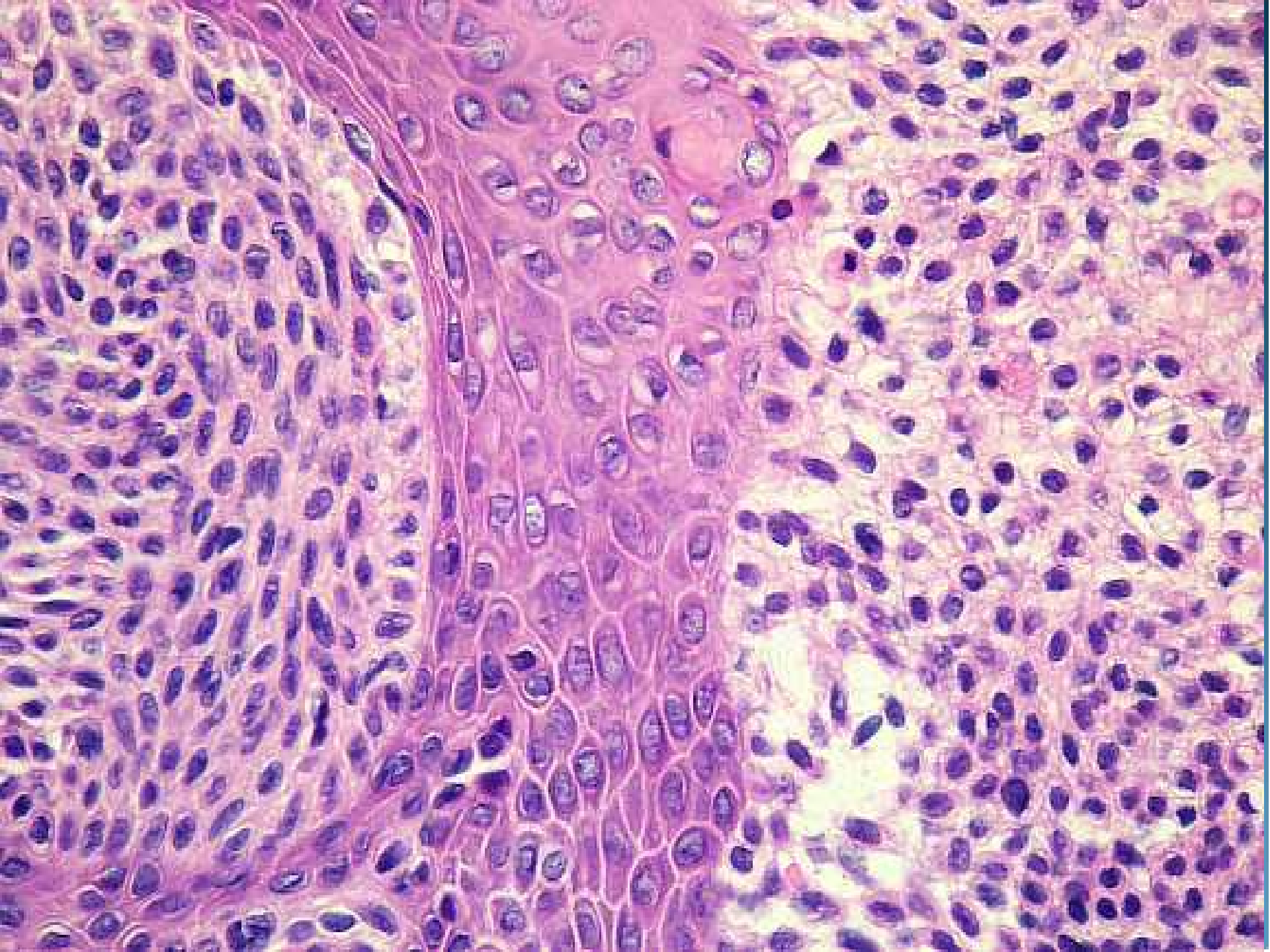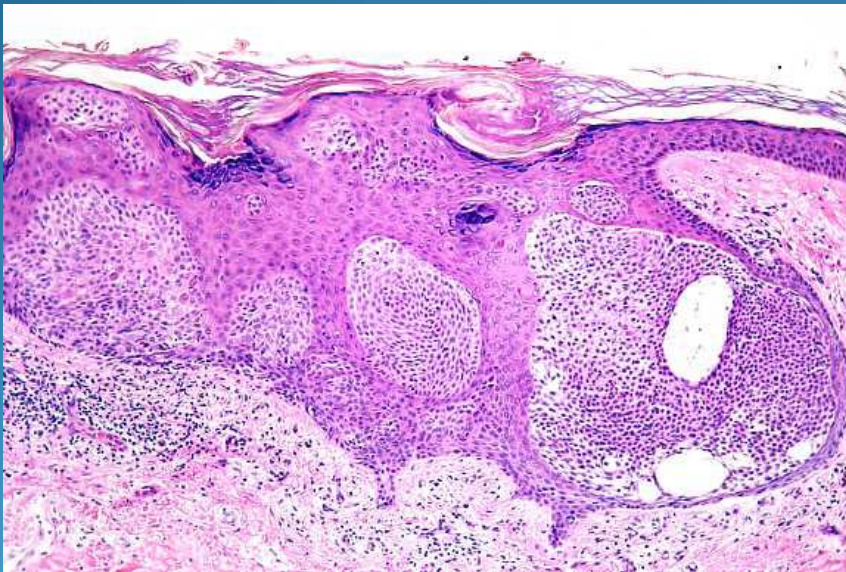


# Seborrheic Keratosis-Clonal Type

# Pearls



- Flattened rete ridges with sharply demarcated nests of squamous cells usually with larger and pale staining cytoplasm
- Usually horn pseudocysts
- No atypia