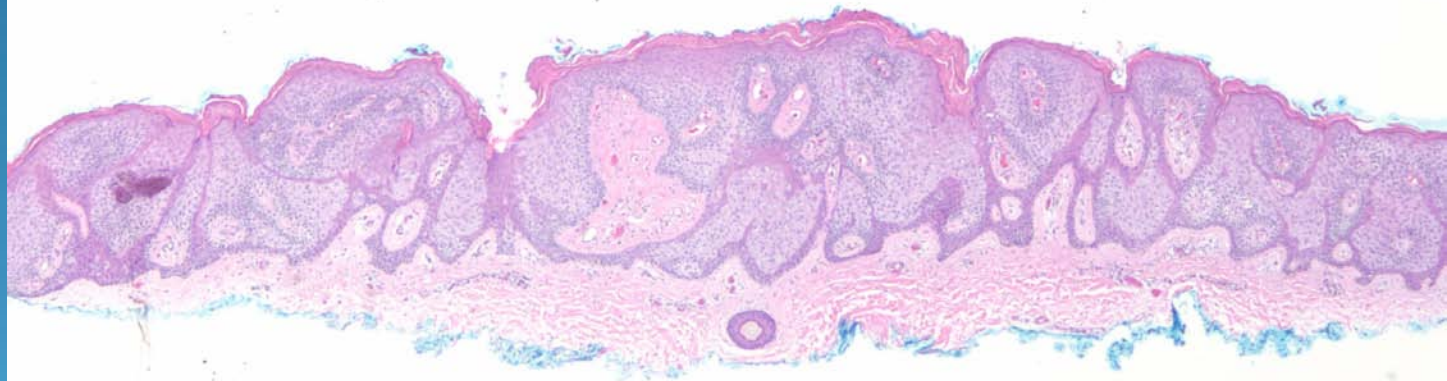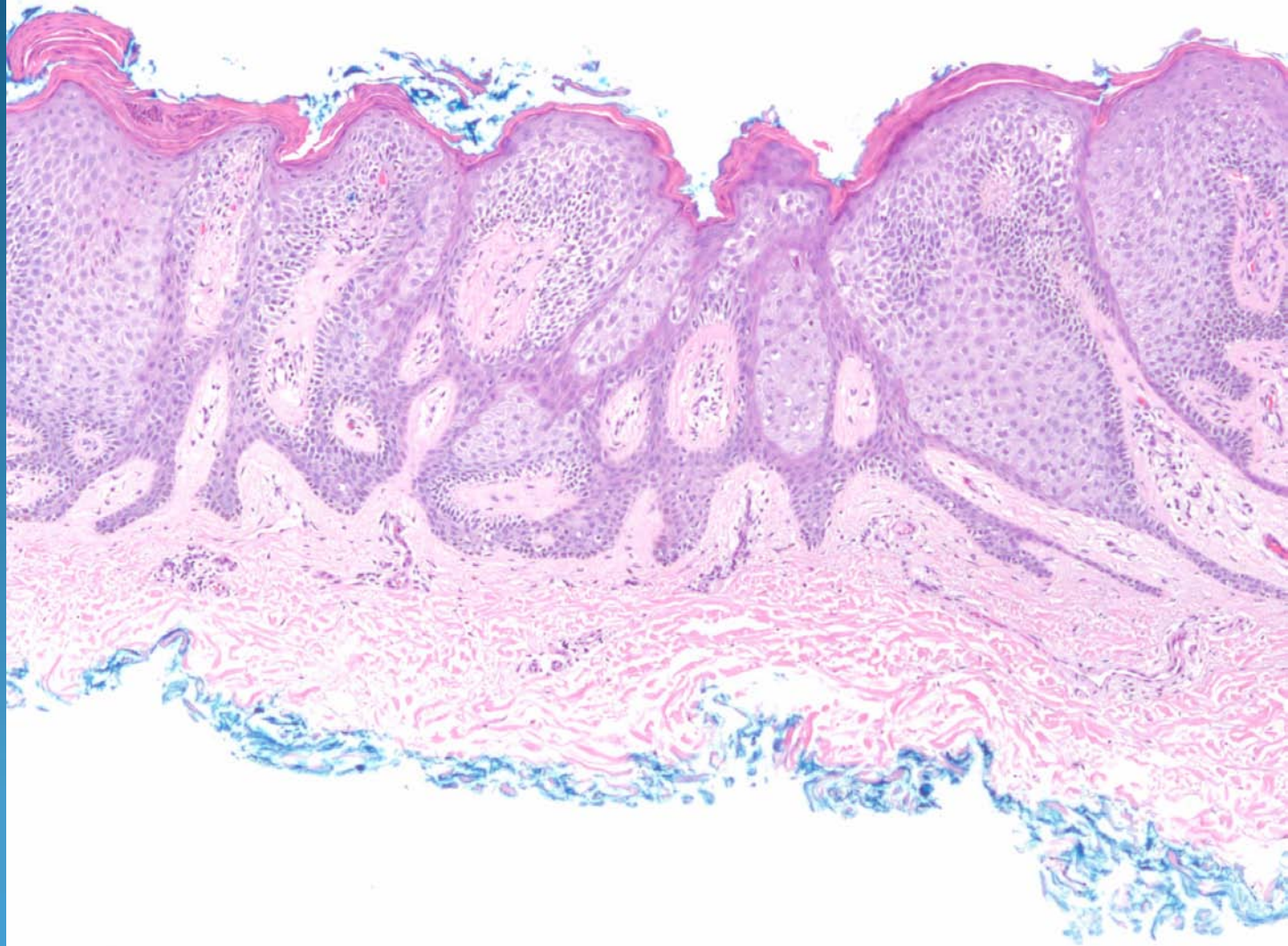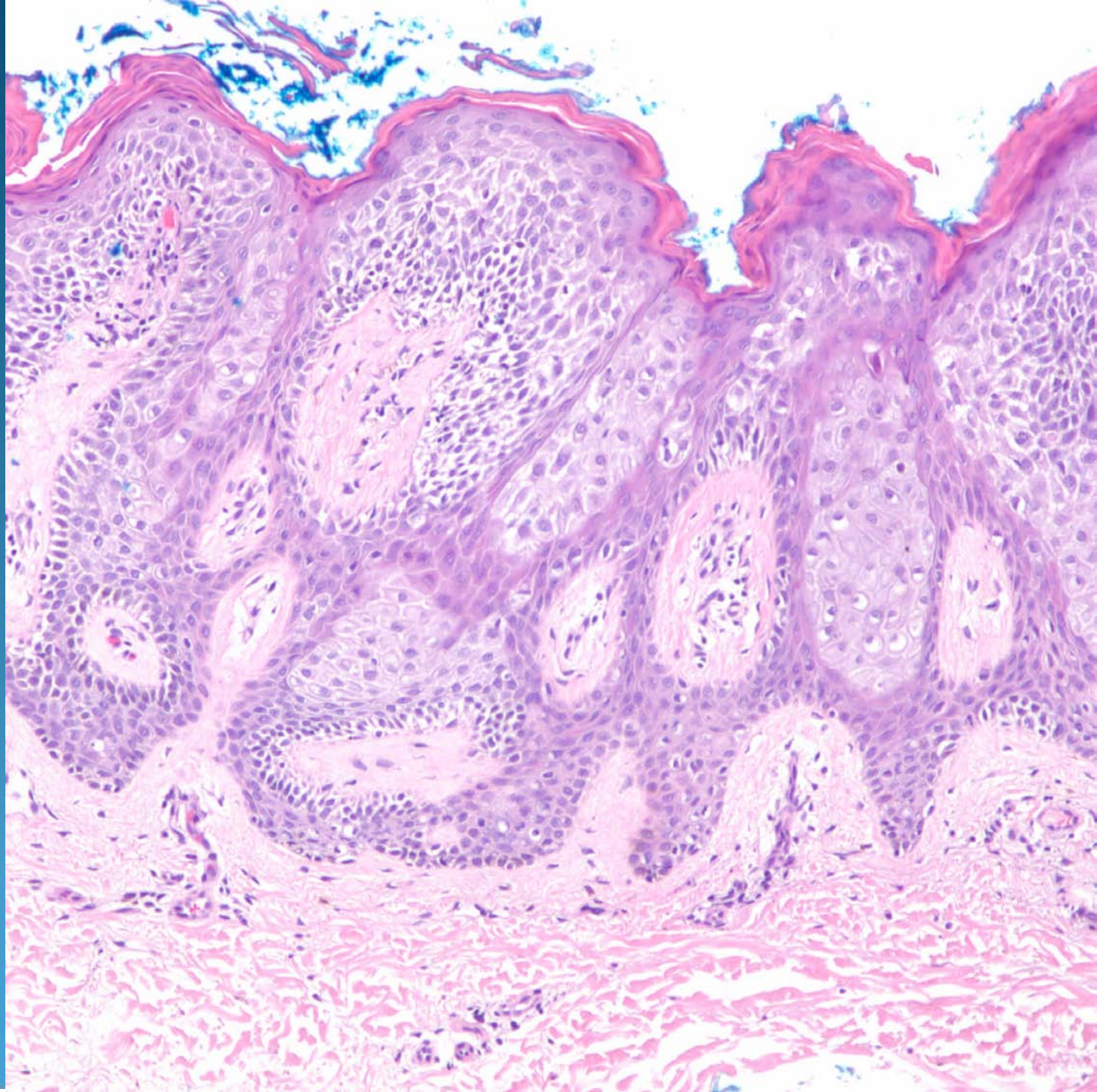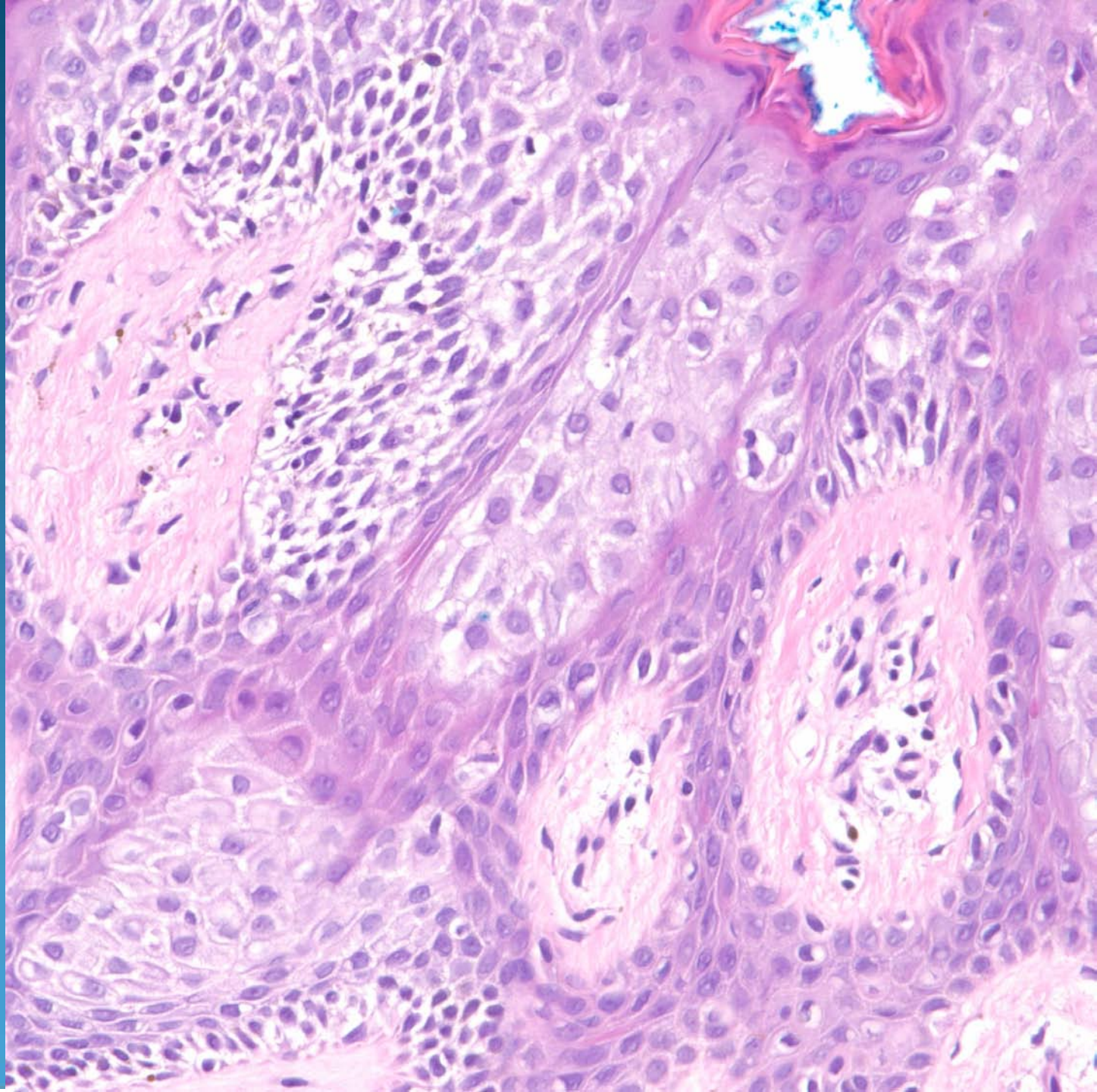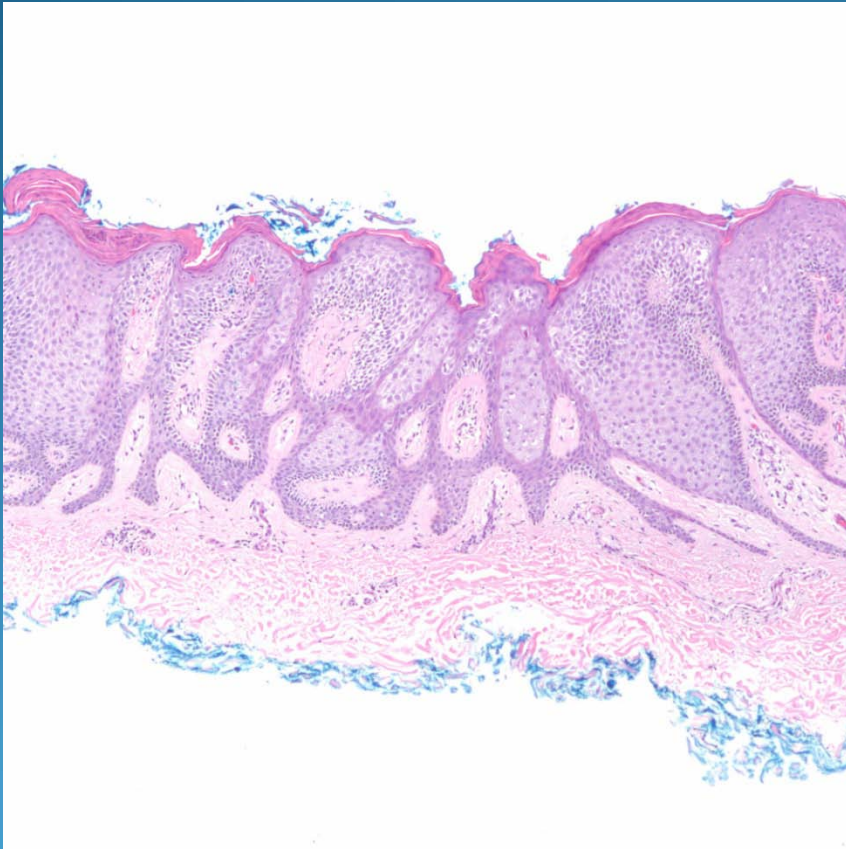


Seborrheic Keratosis-Clonal Type

Pearls



- Silhouette of conventional seborrheic keratosis with sharply demarcated islands of keratinocytes, imparting a clonal appearance