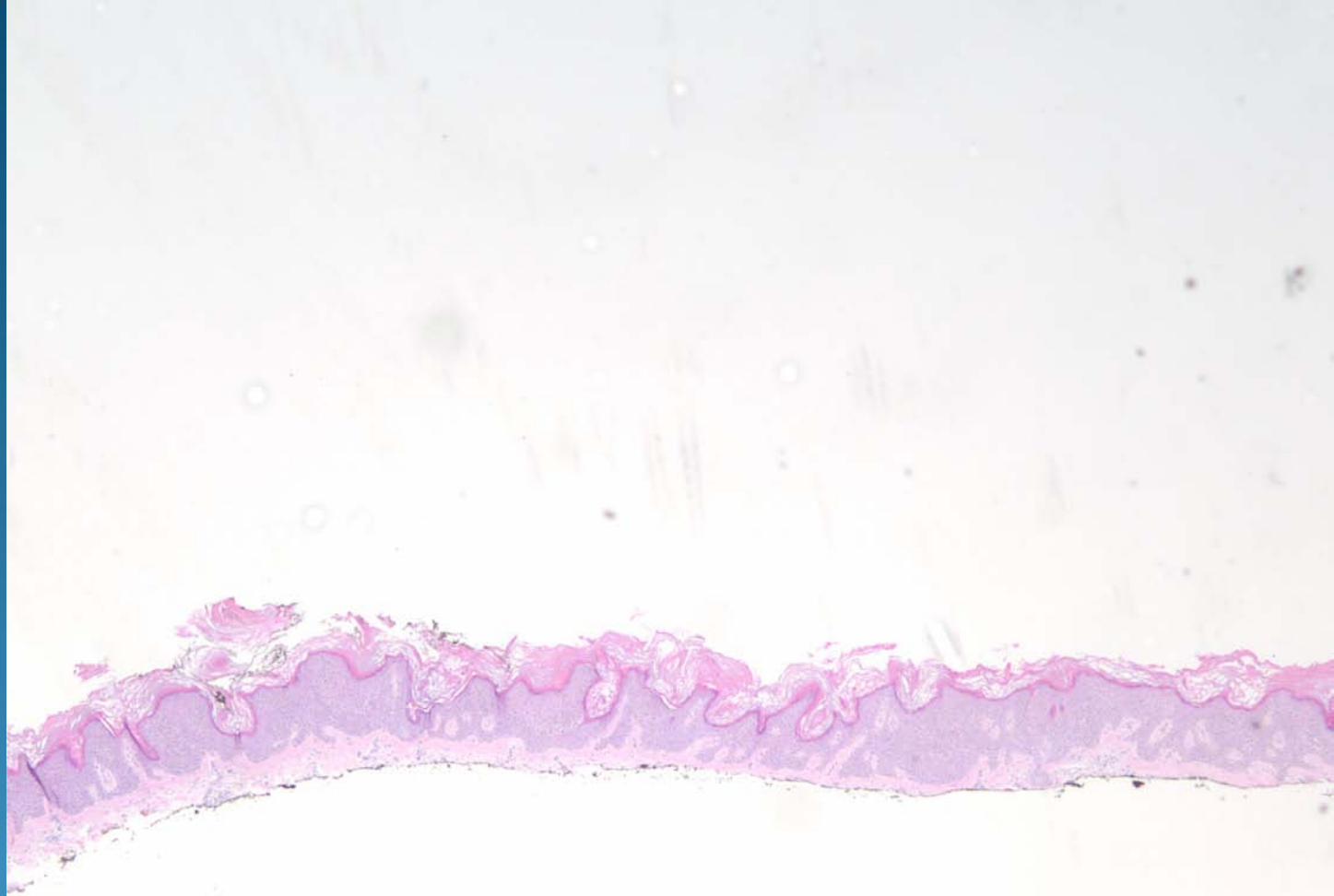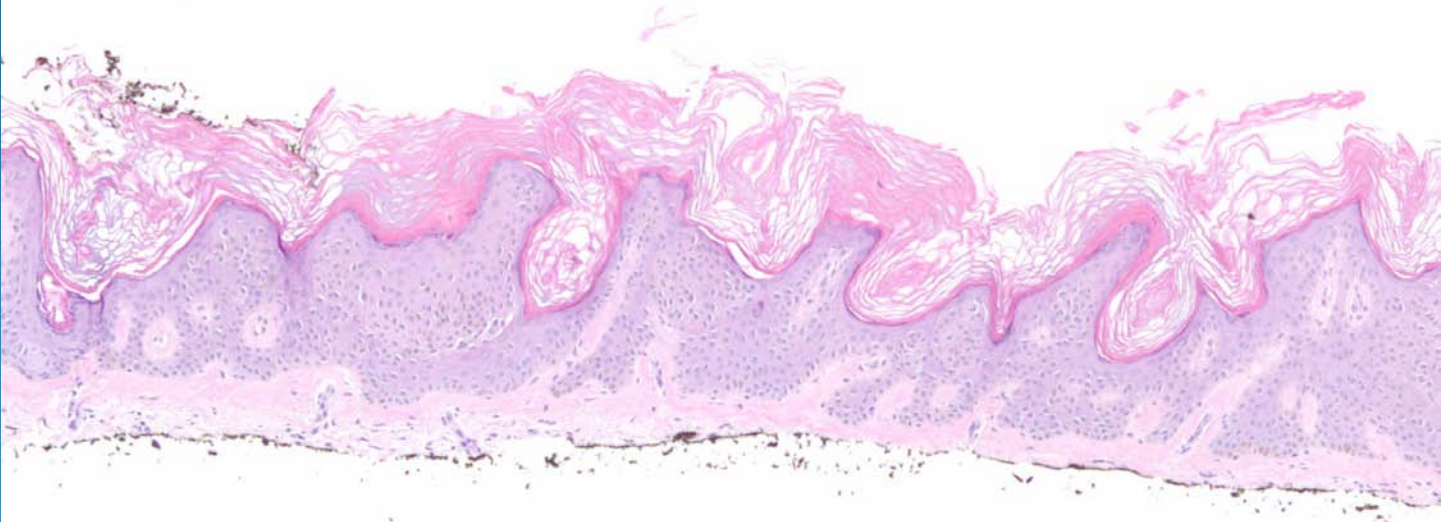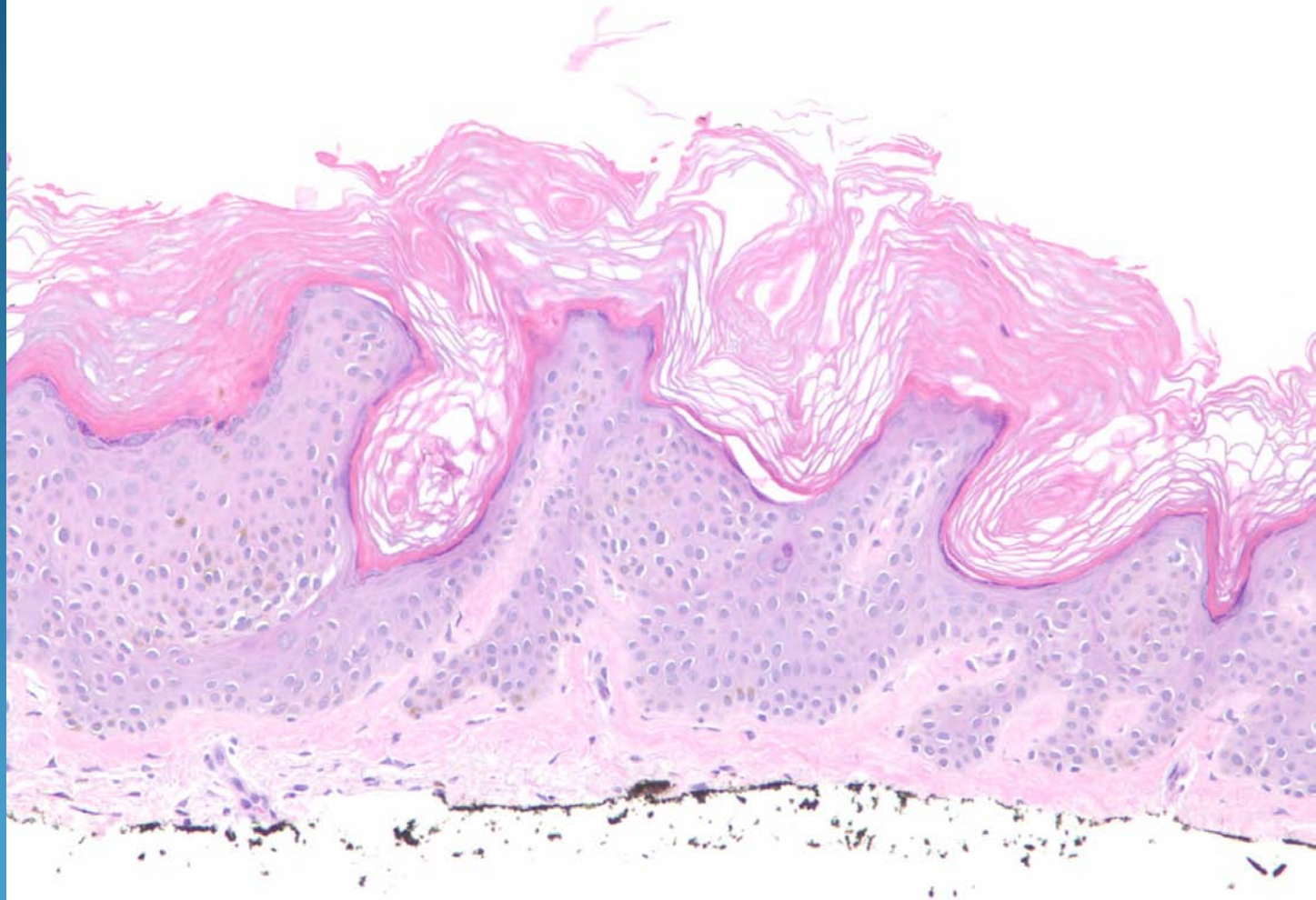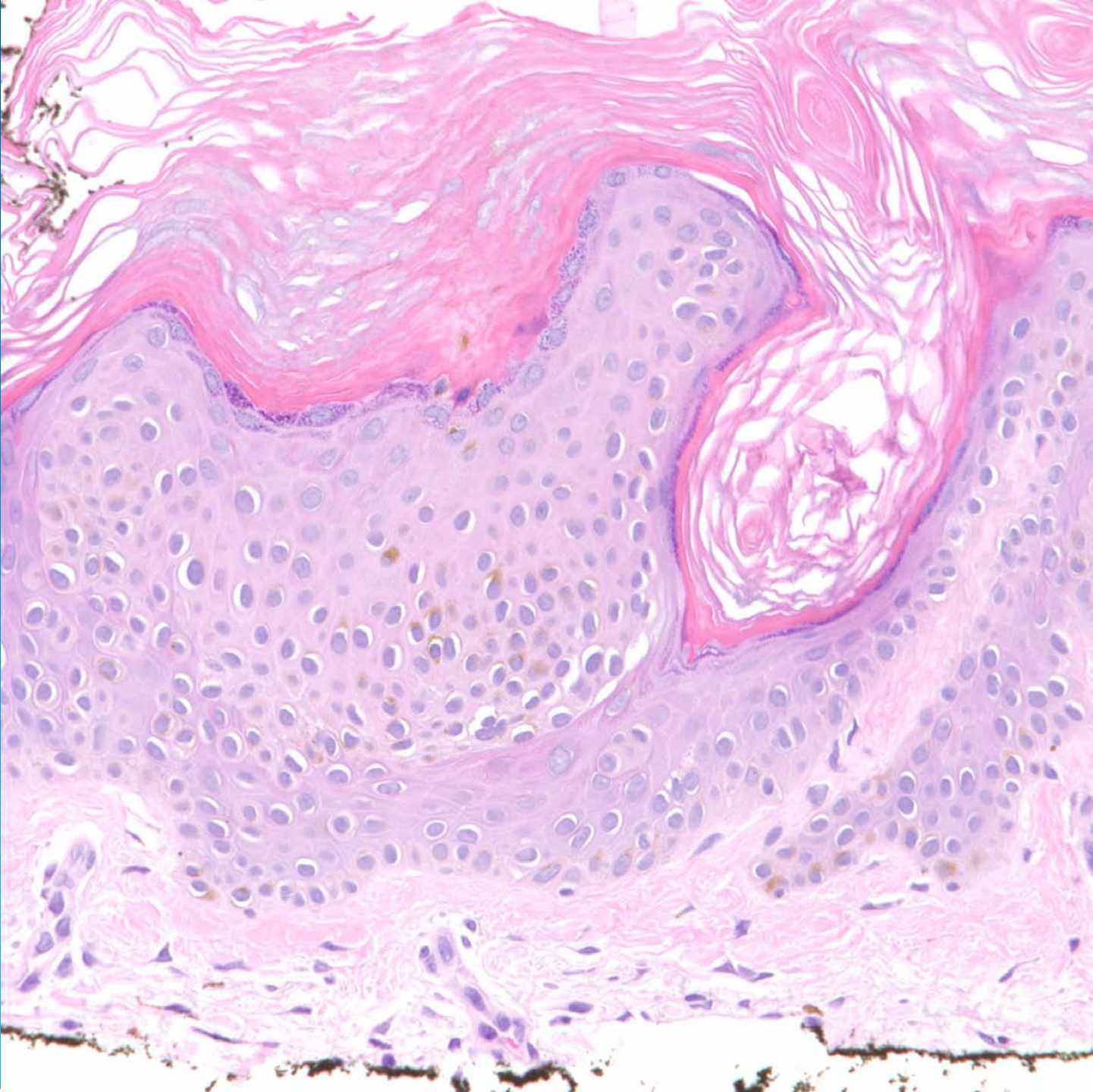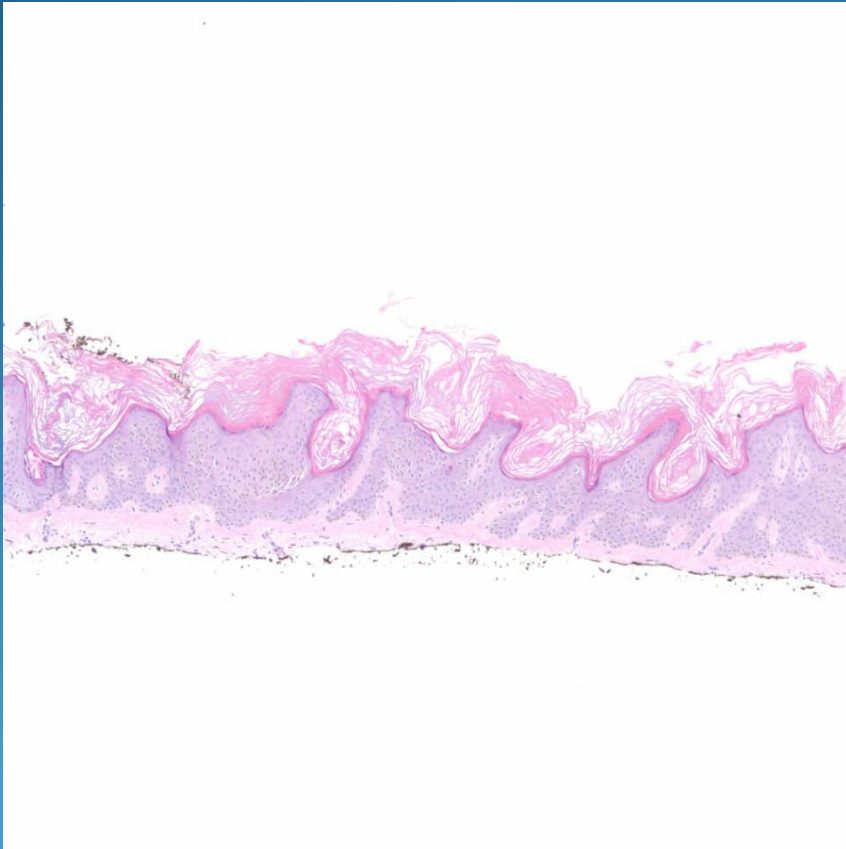


# Seborrheic Keratosis

# Pearls



- Flattened and fused rete ridges
- Epidermal hyperplasia
- Horn pseudocysts