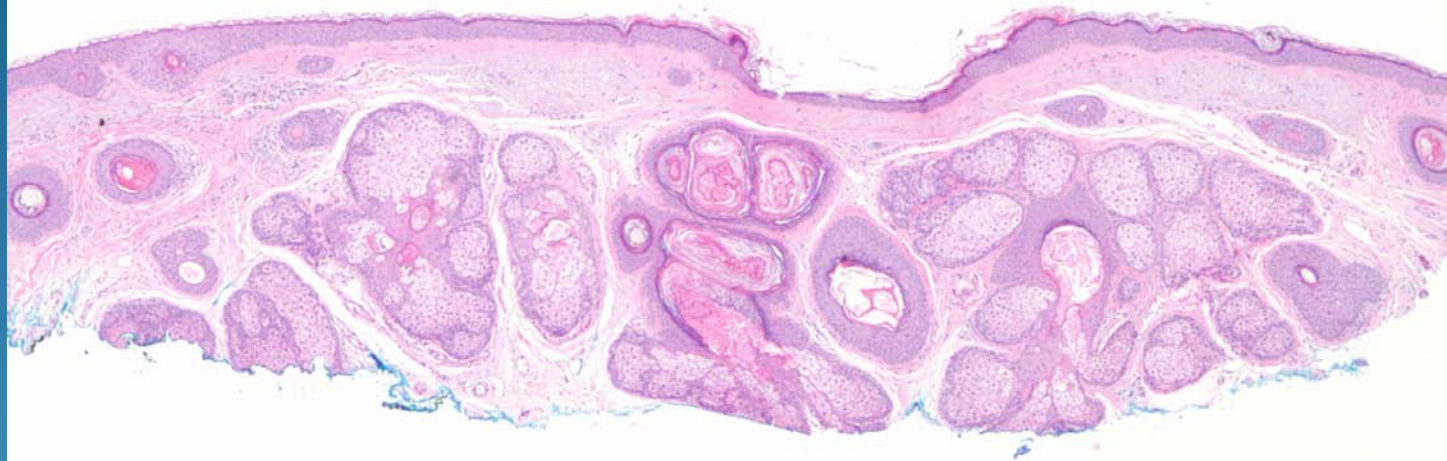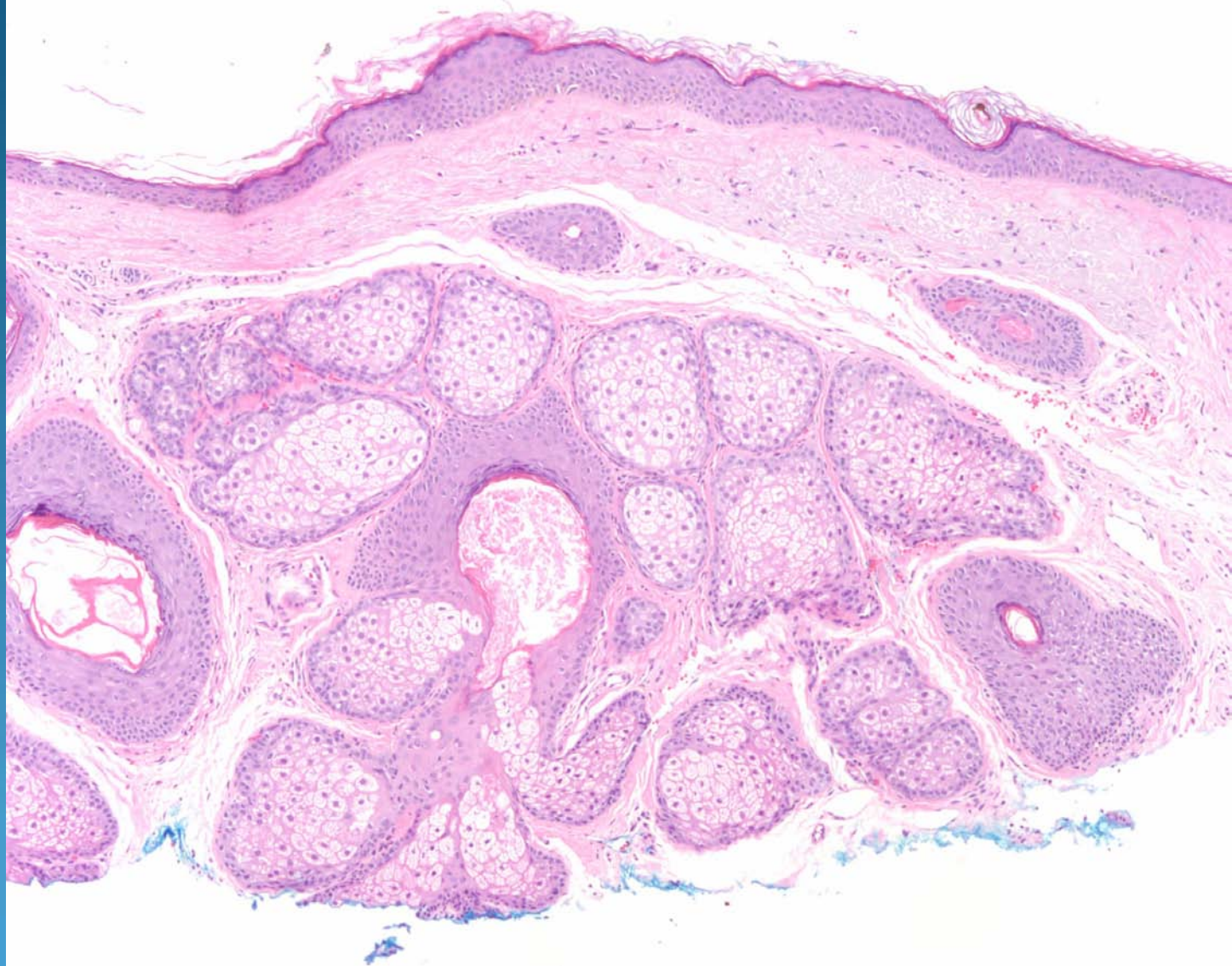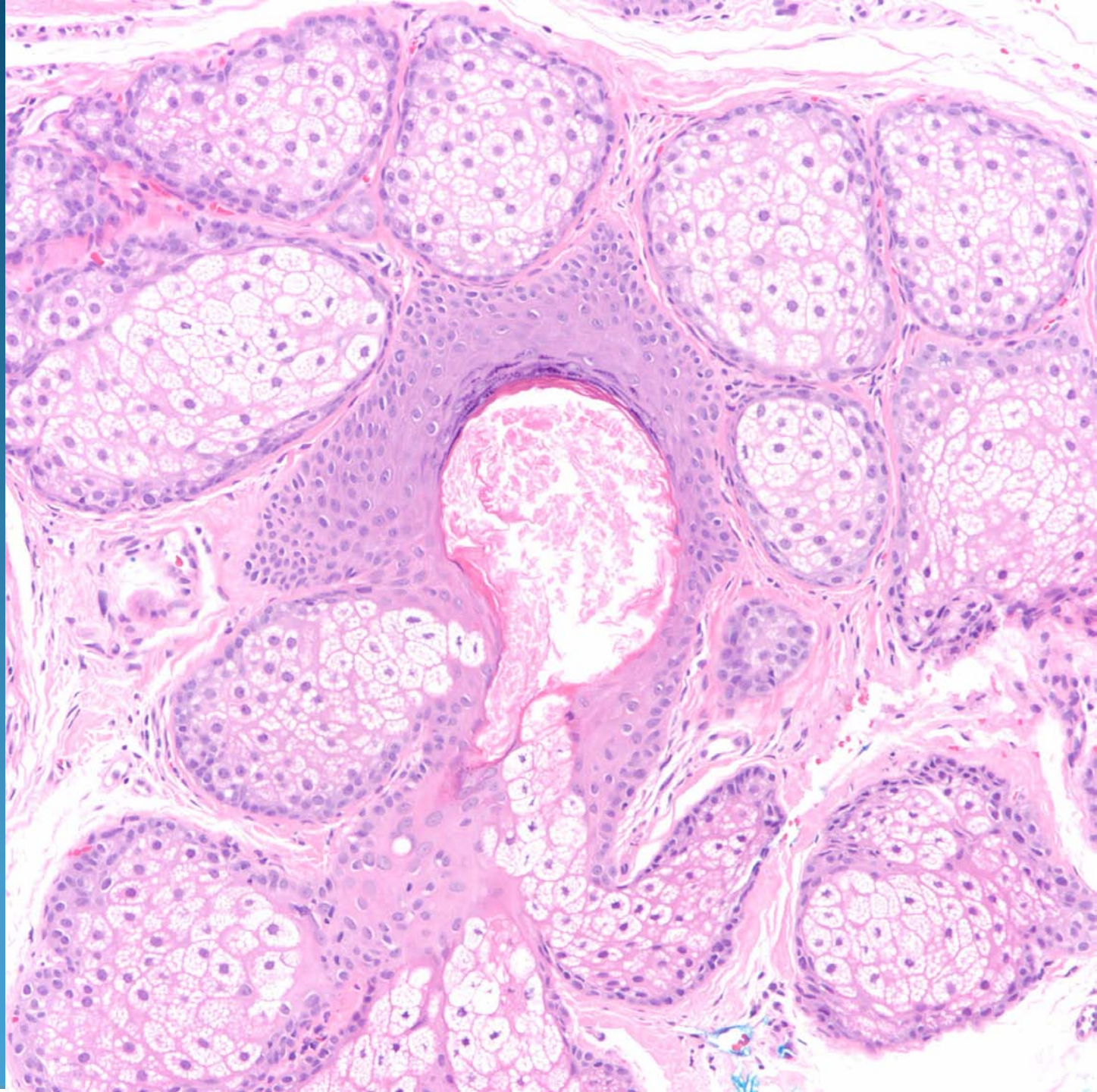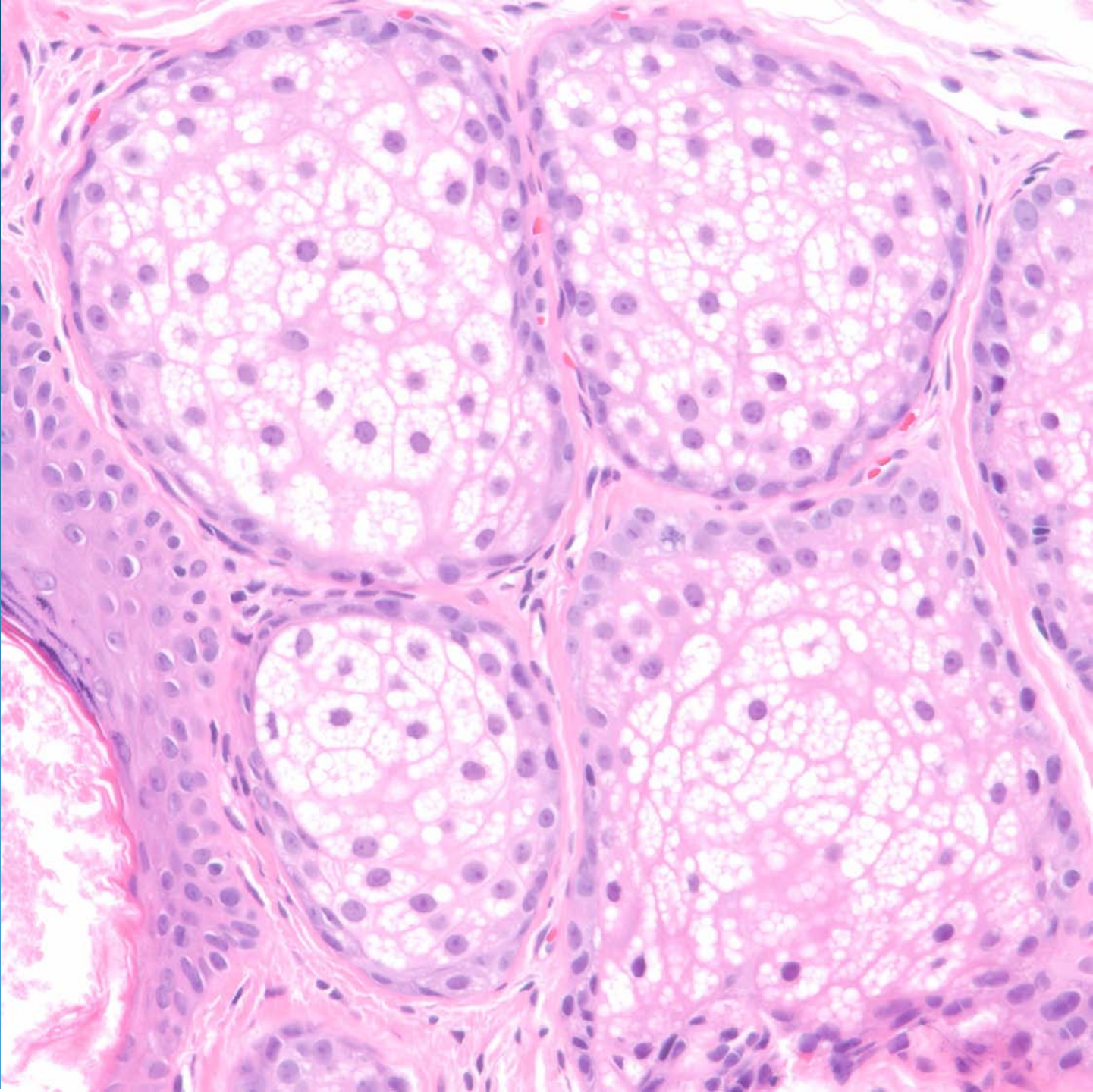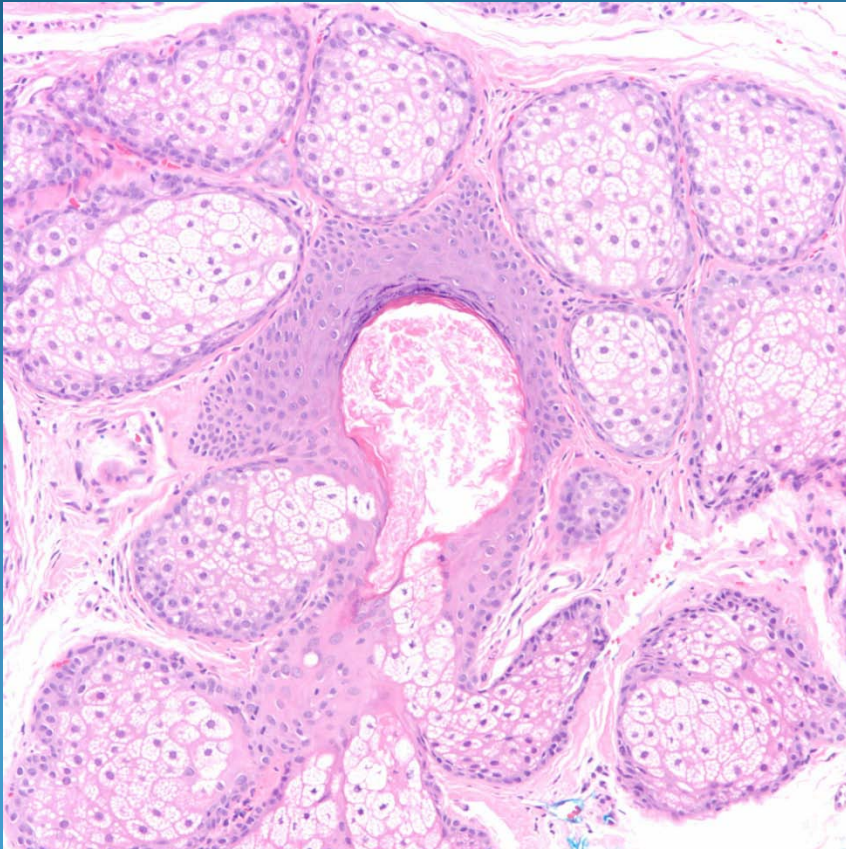


# Sebaceous Gland Hyperplasia

# Pearls



- Circumferential proliferation of mature sebaceous glands around a hair follicle
- No cytologic atypia