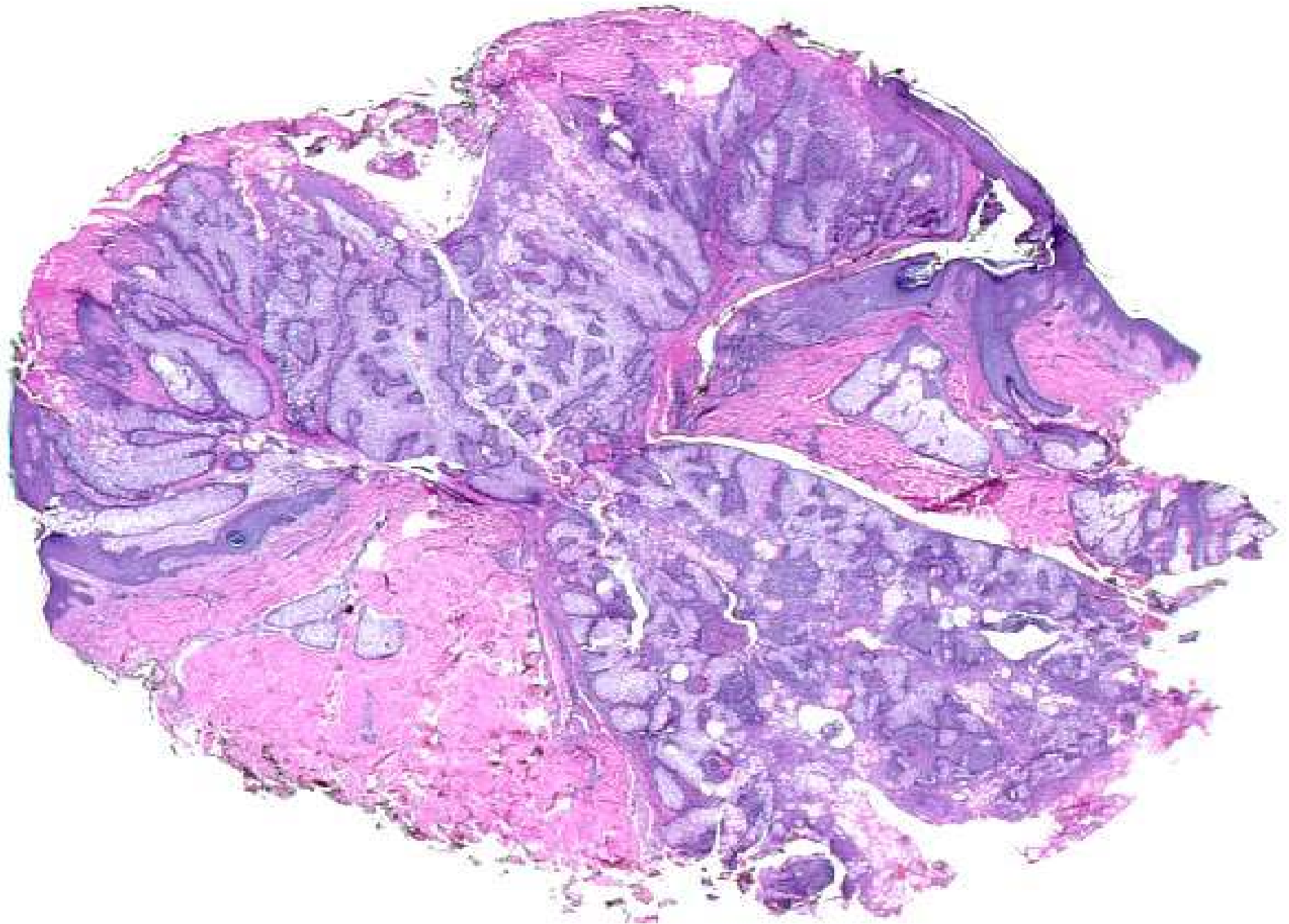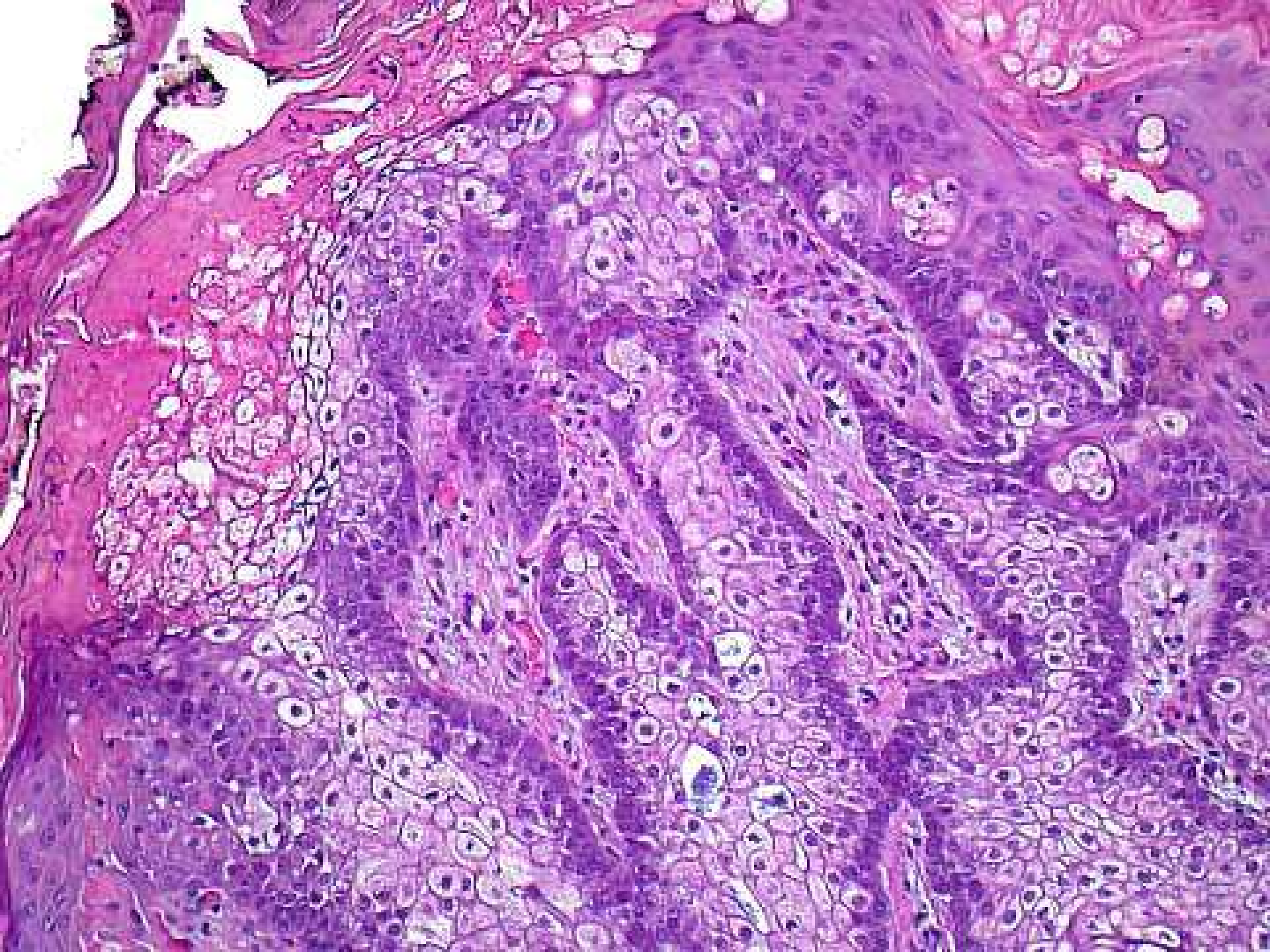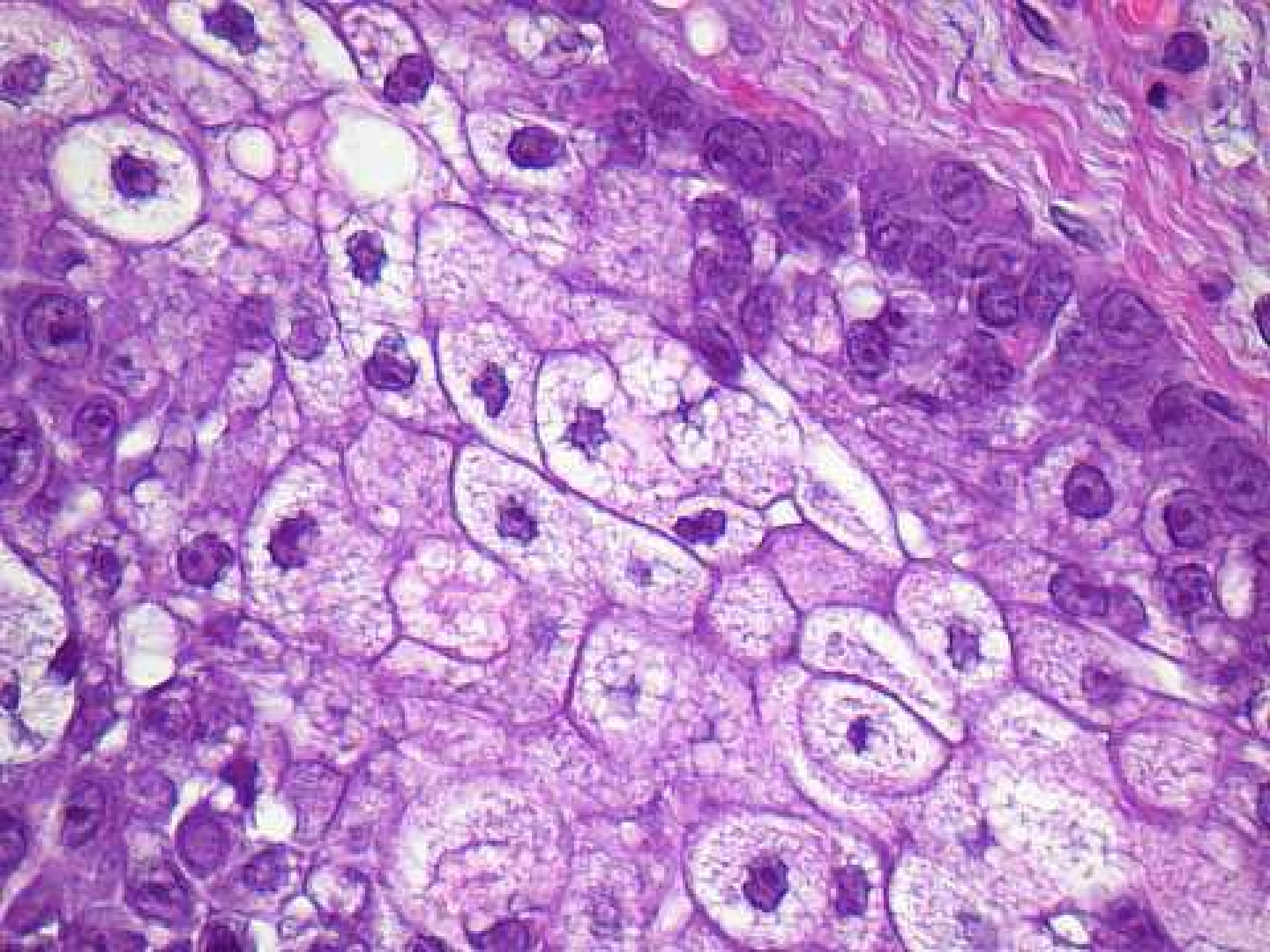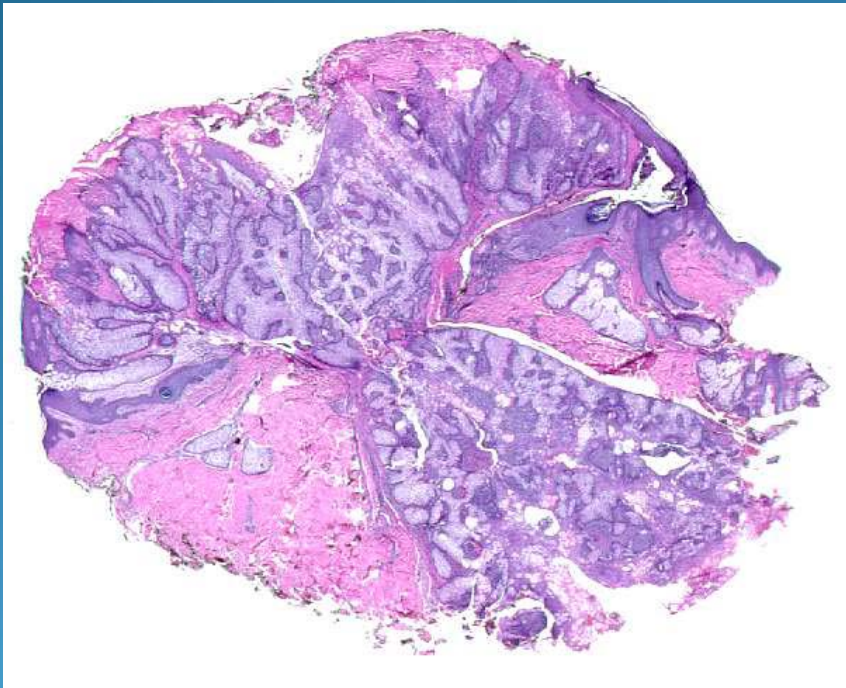


Sebaceous Adenoma

Pearls



- Well defined lobular pattern with smooth round borders
- Mixture of germinative and sebaceous cells
- Mitoses are ok