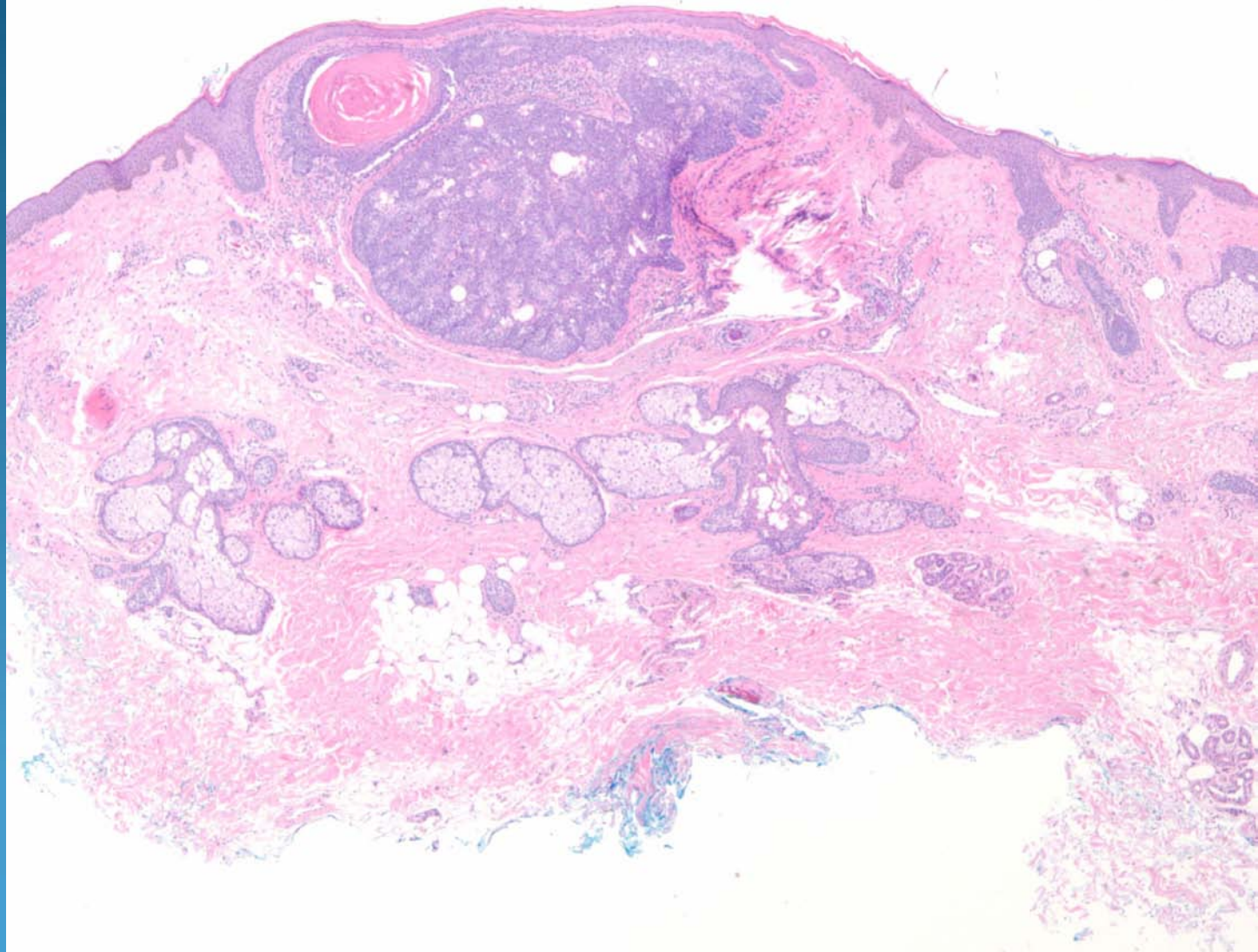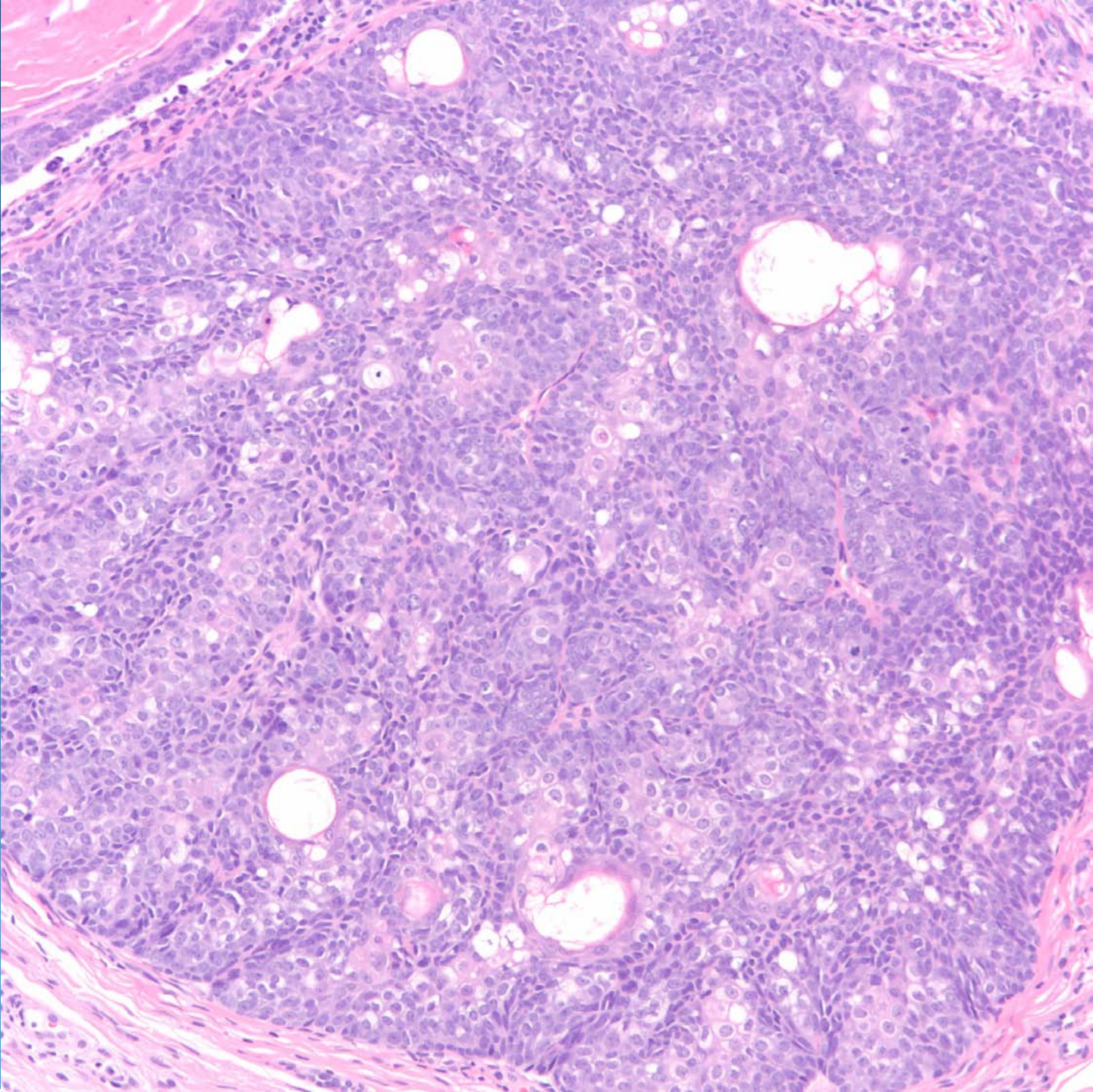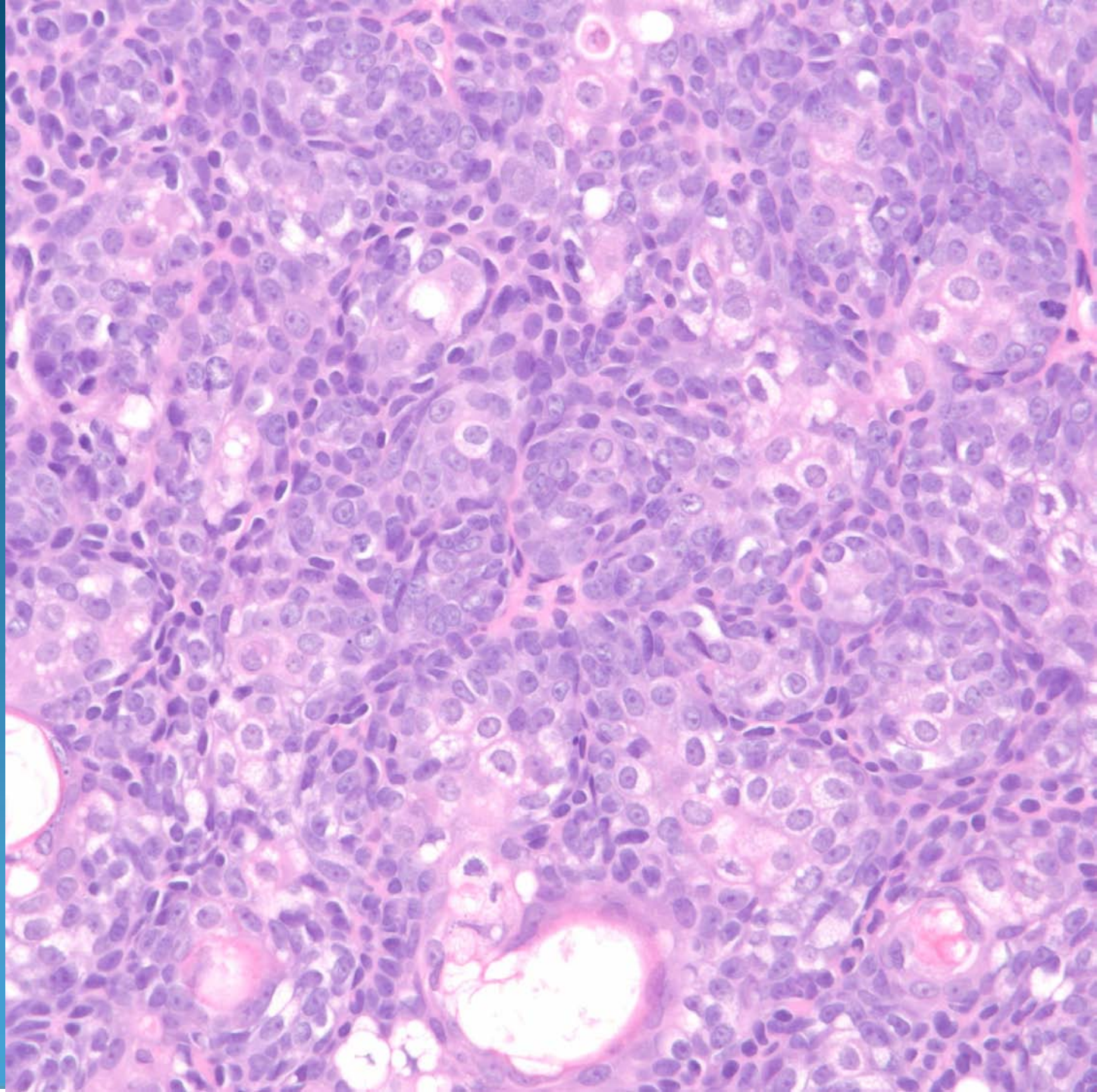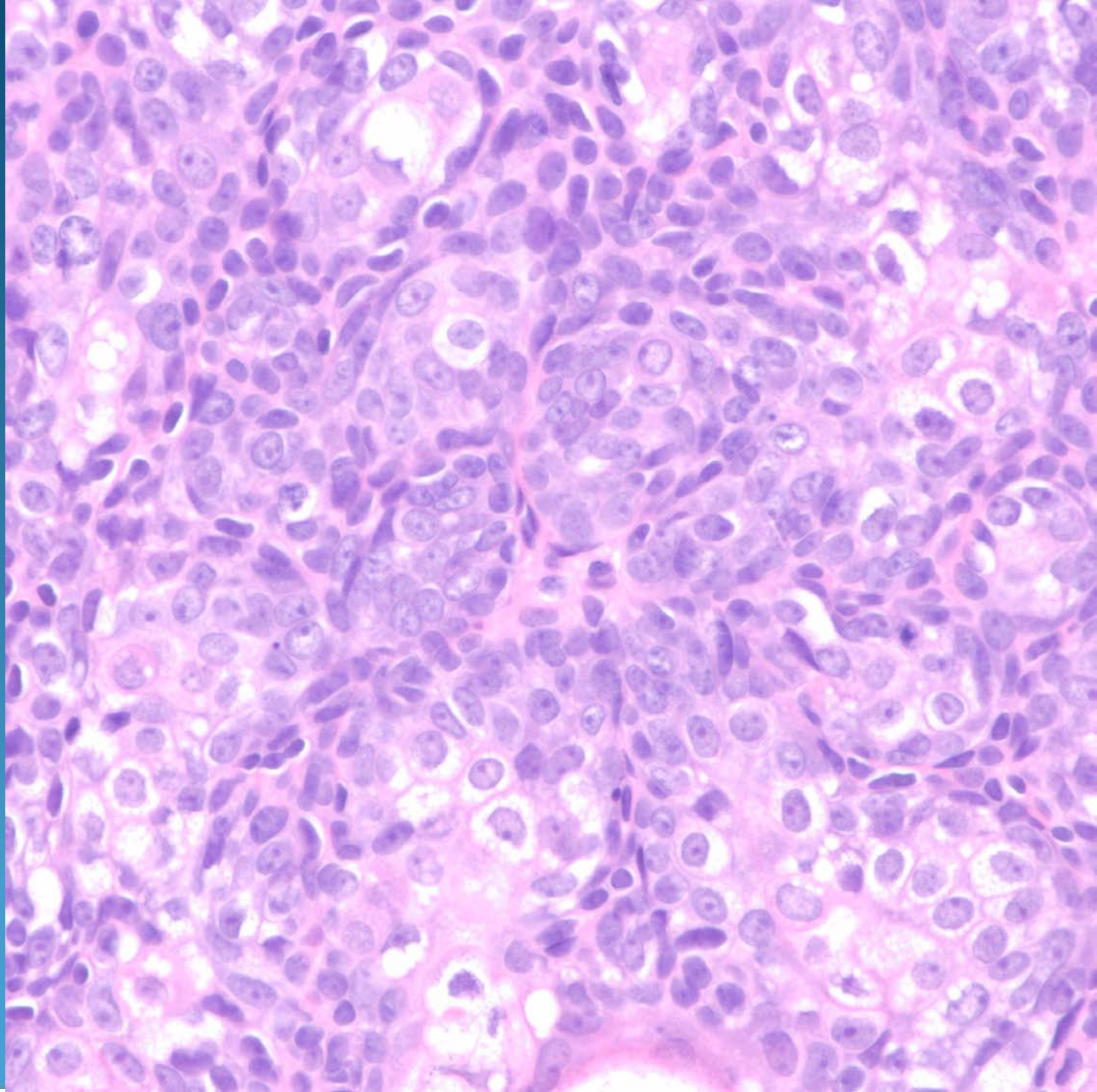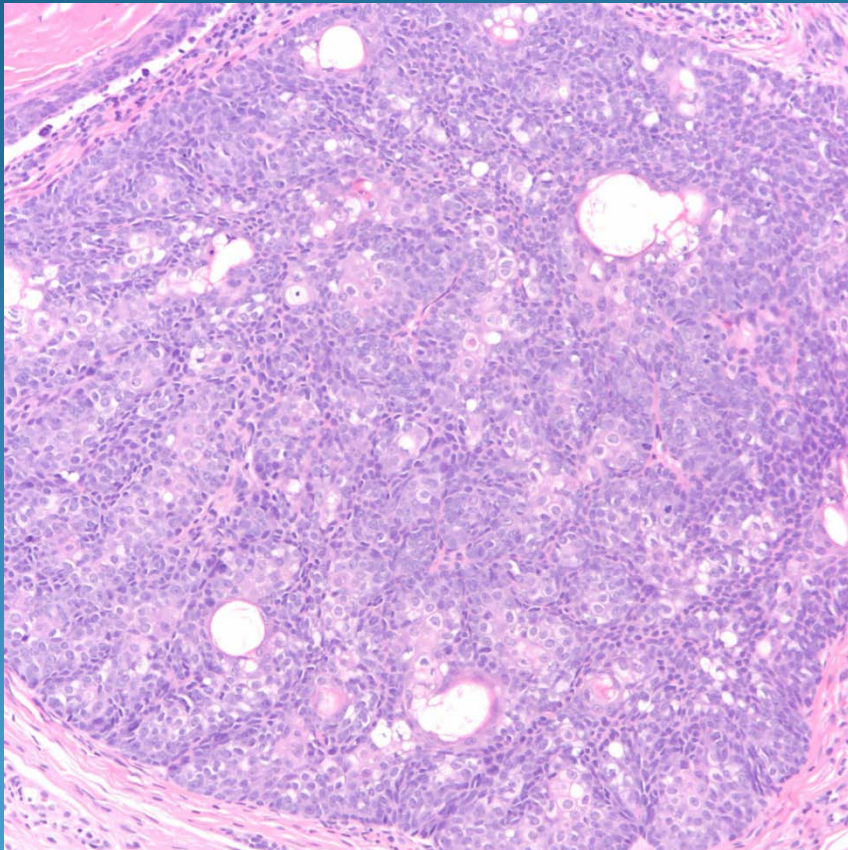


Sebaceous Adenoma

Pearls



- Circumscribed basaloid neoplasm attached to undersurface of epidermis
- Orderly maturation of sebocytes from periphery to inner layer of basaloid cells
- Rare non-atypical mitotic figures