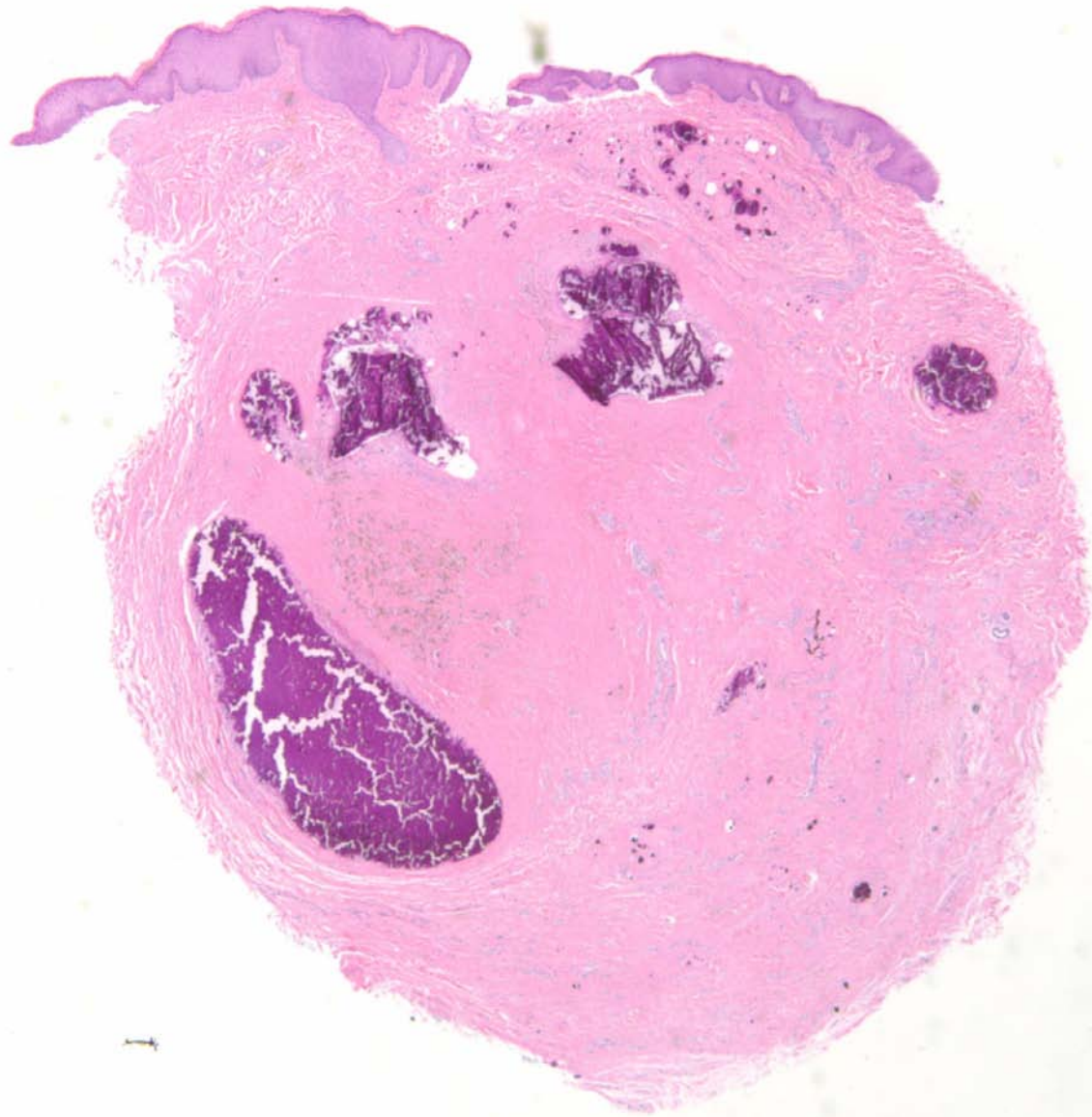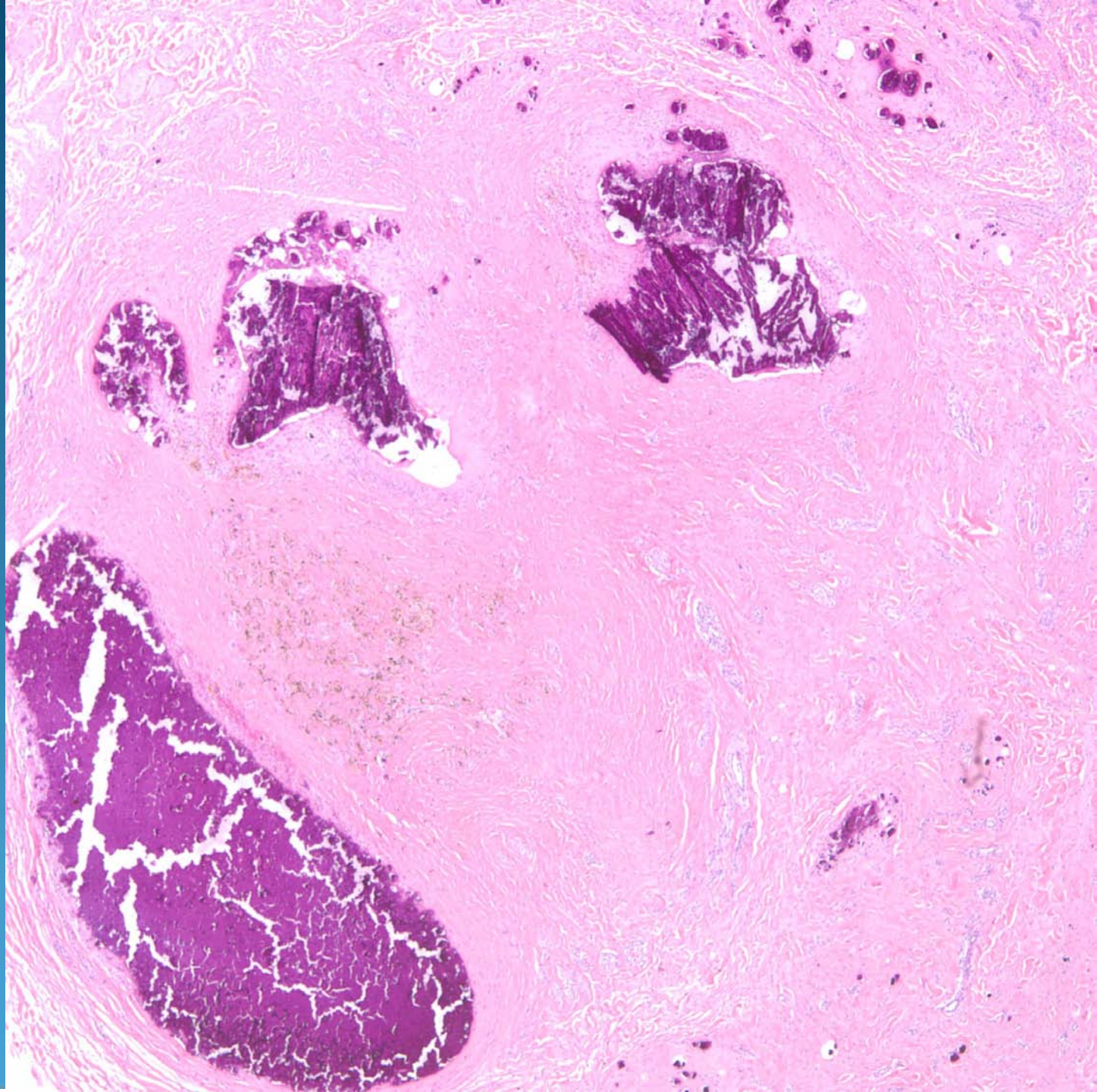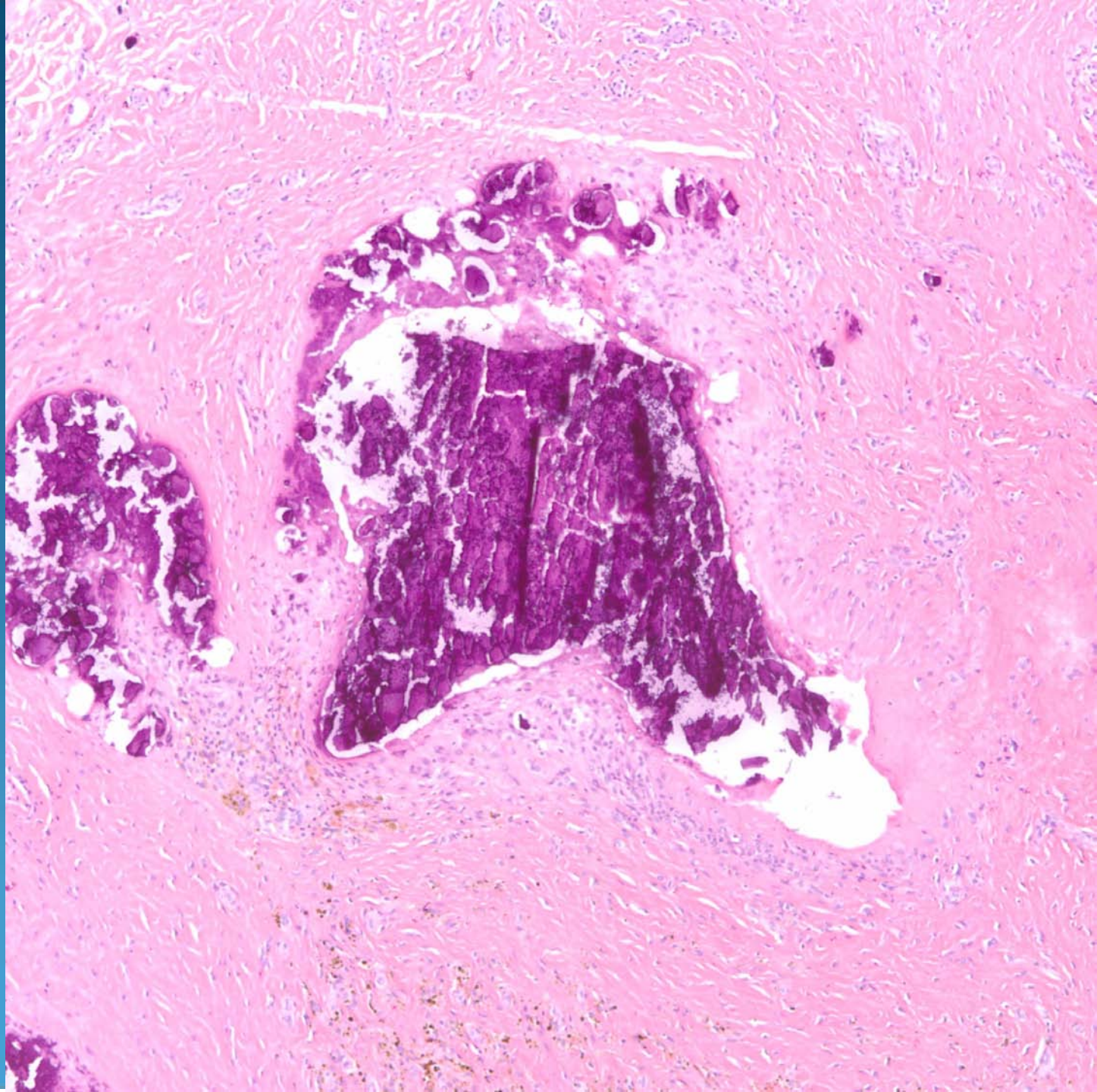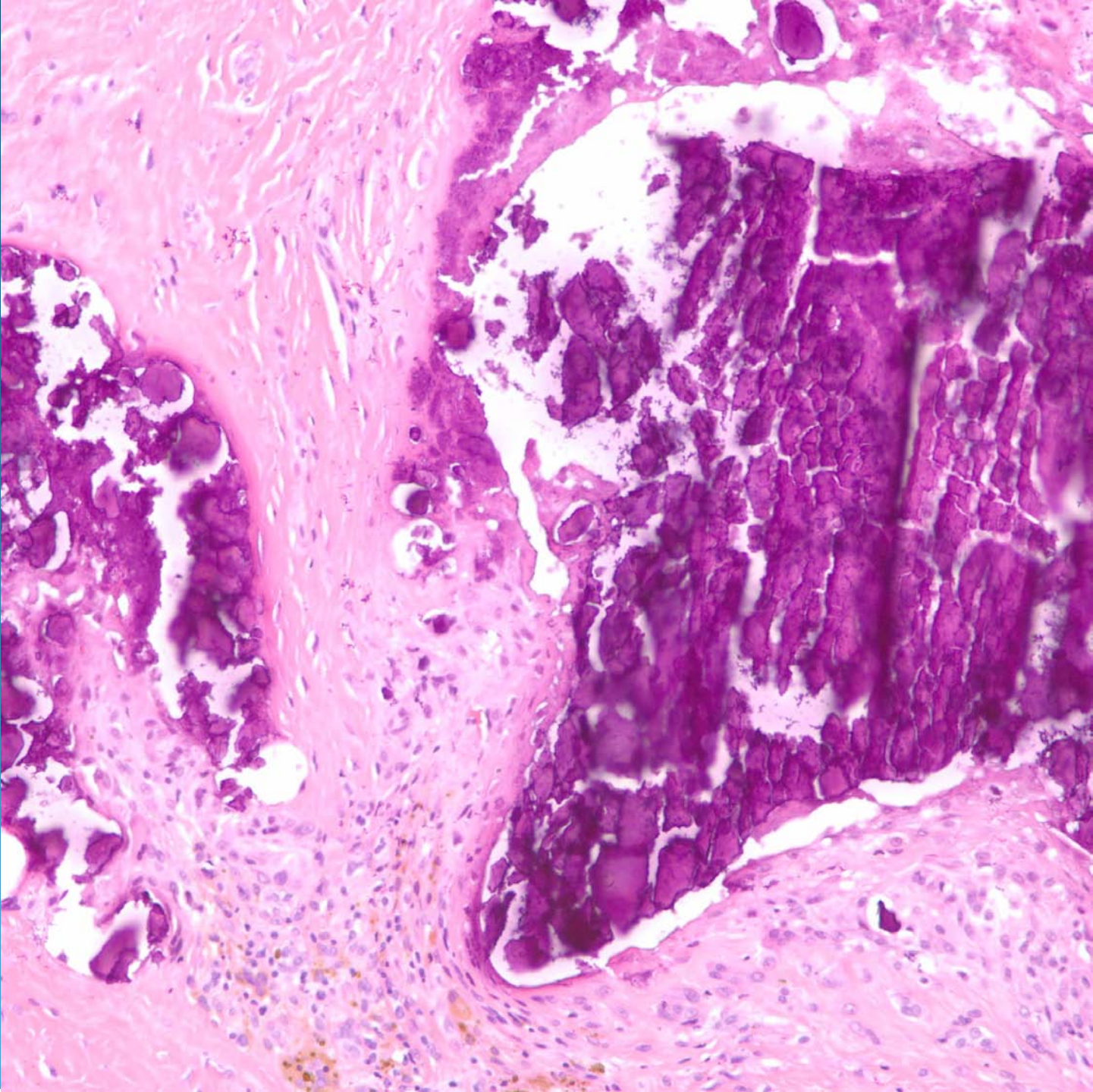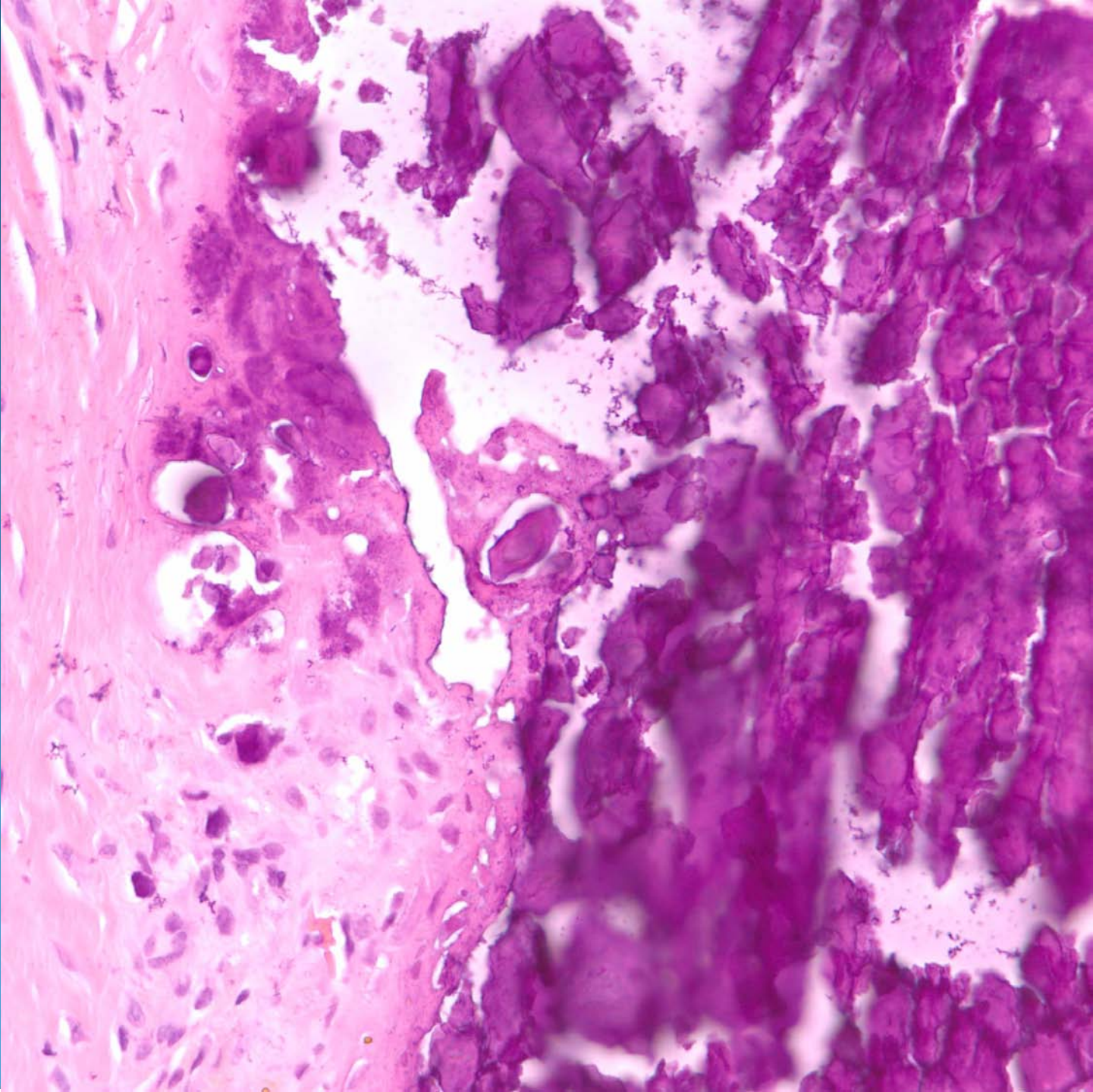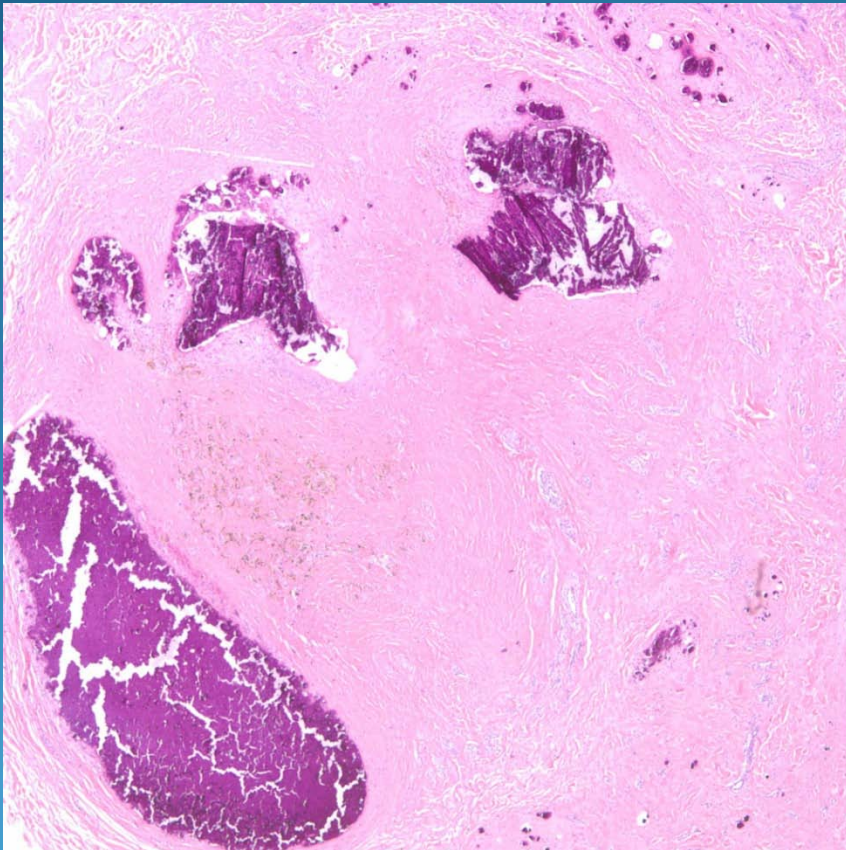


Scrotal Calcinosis

Pearls



- Amorphous blue-red collections of calcium
- No cyst lining but surrounded by foreign-body type giant cells and scar
- Identical to tumoral calcinosis