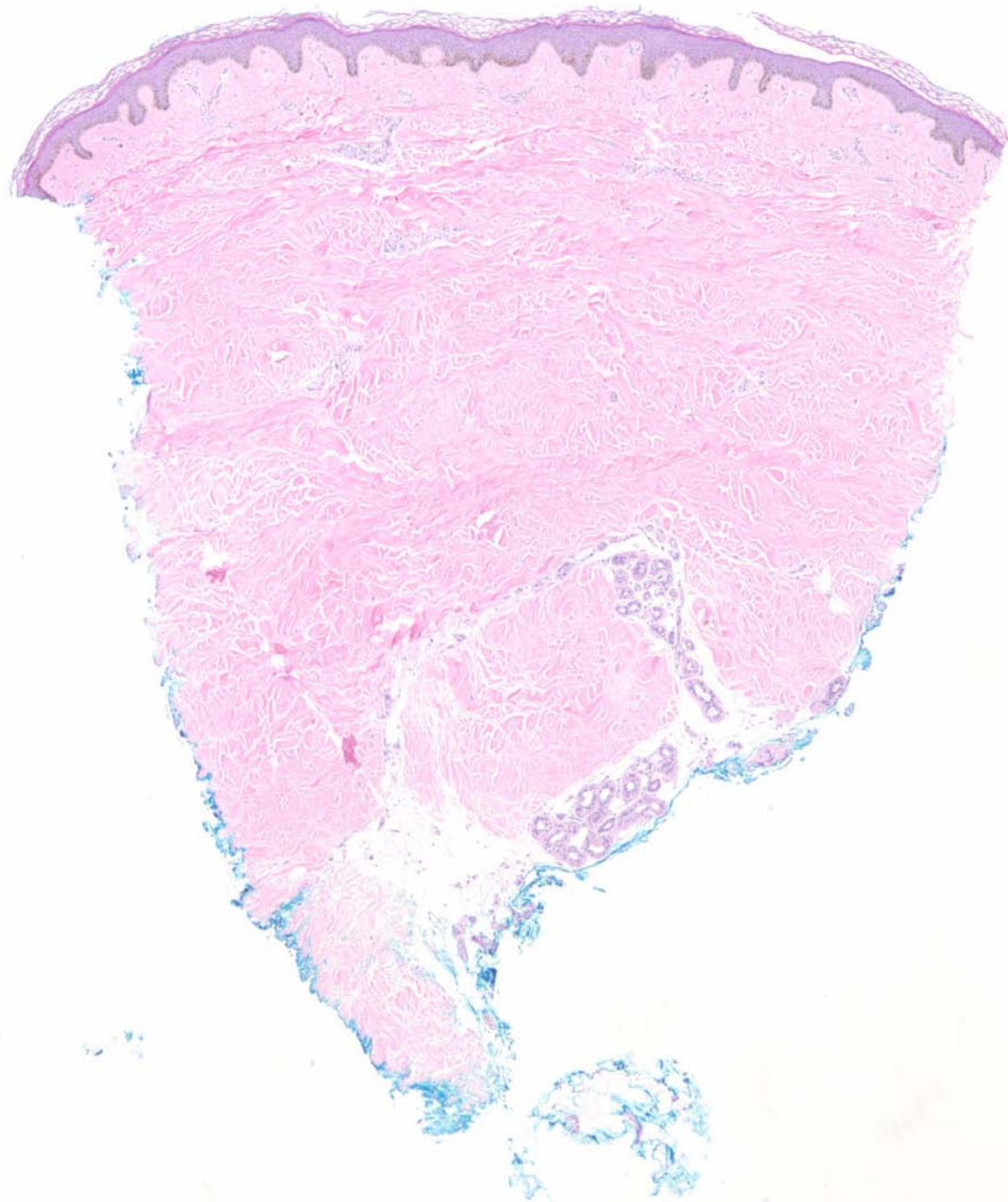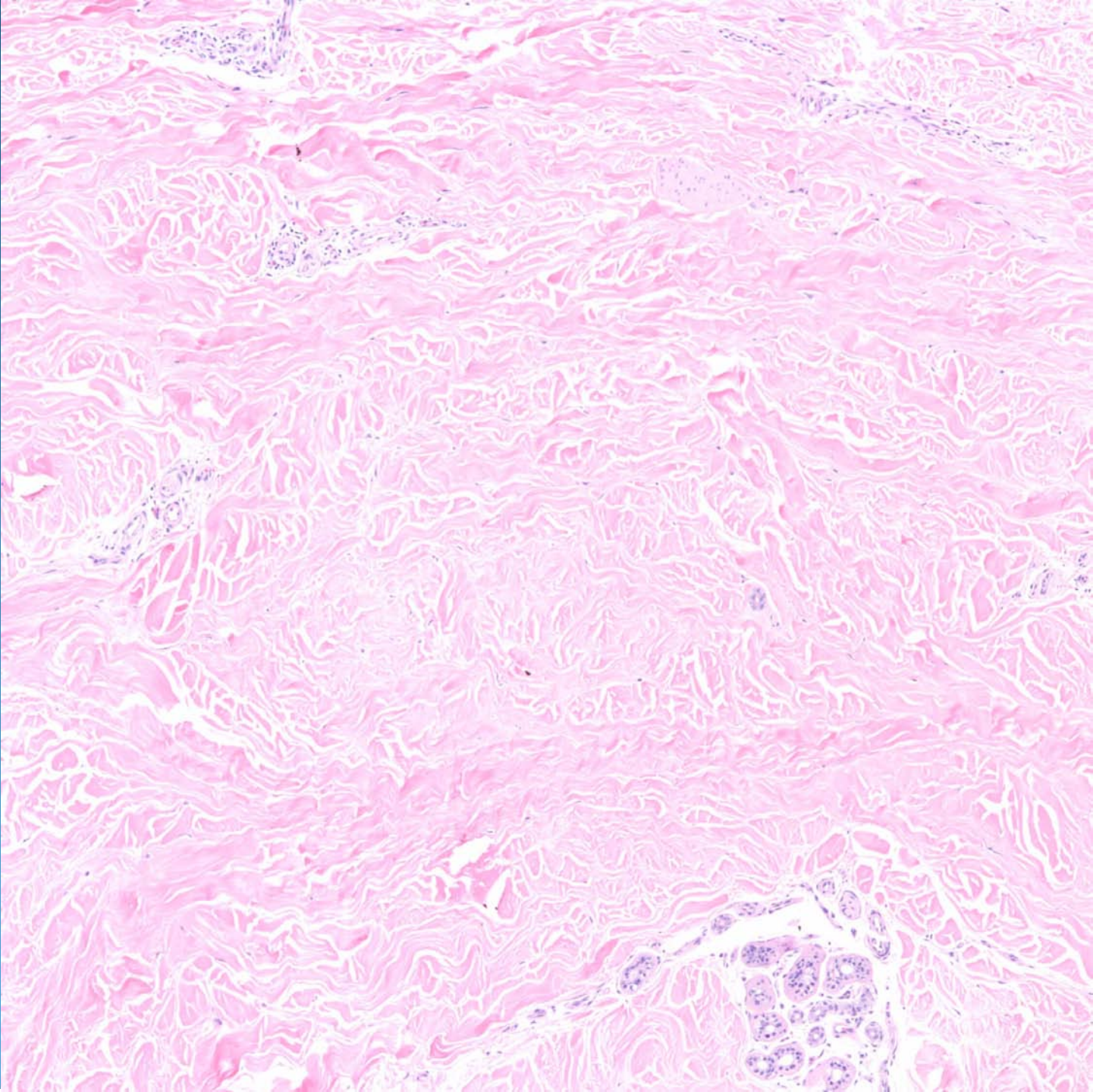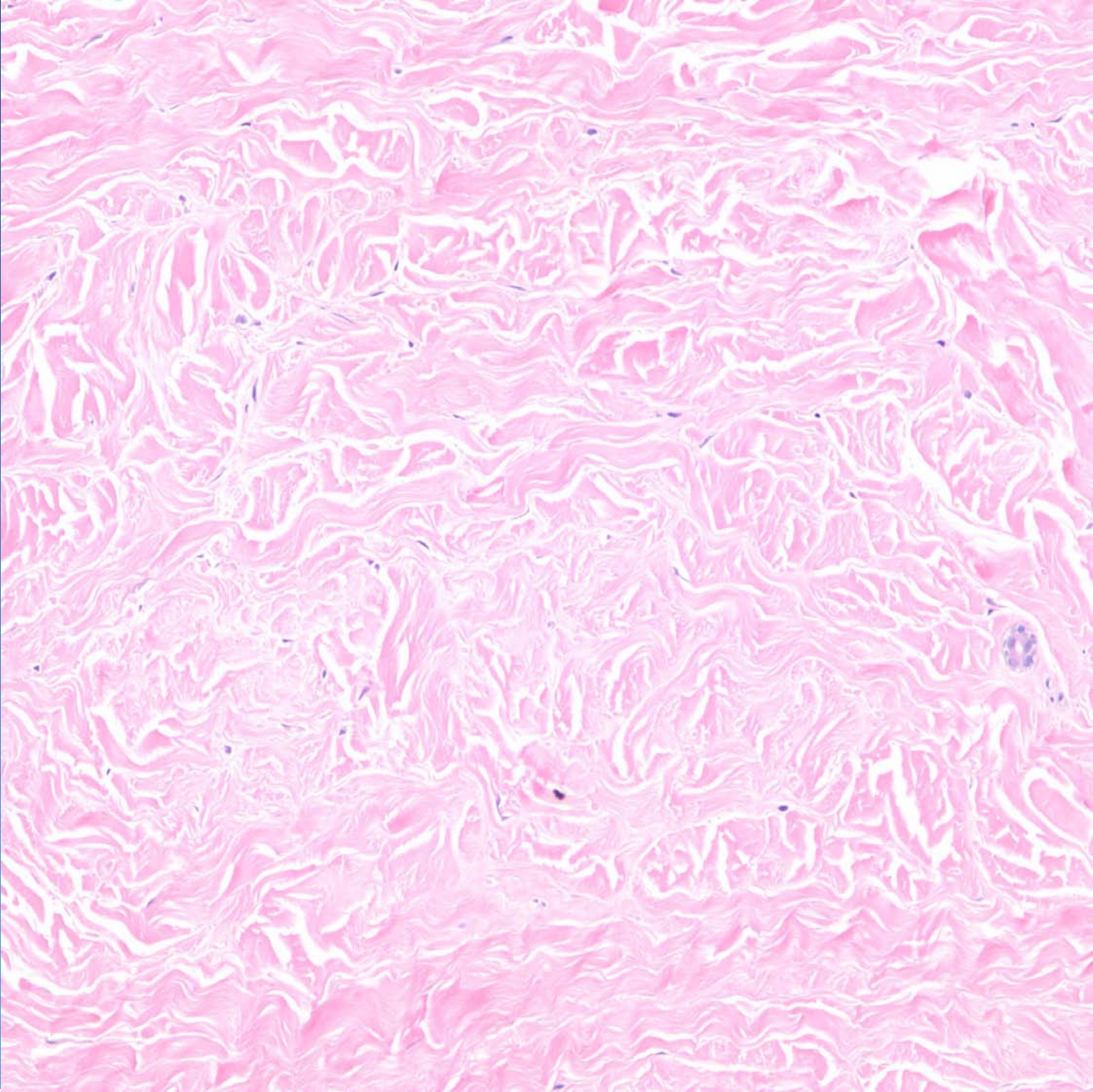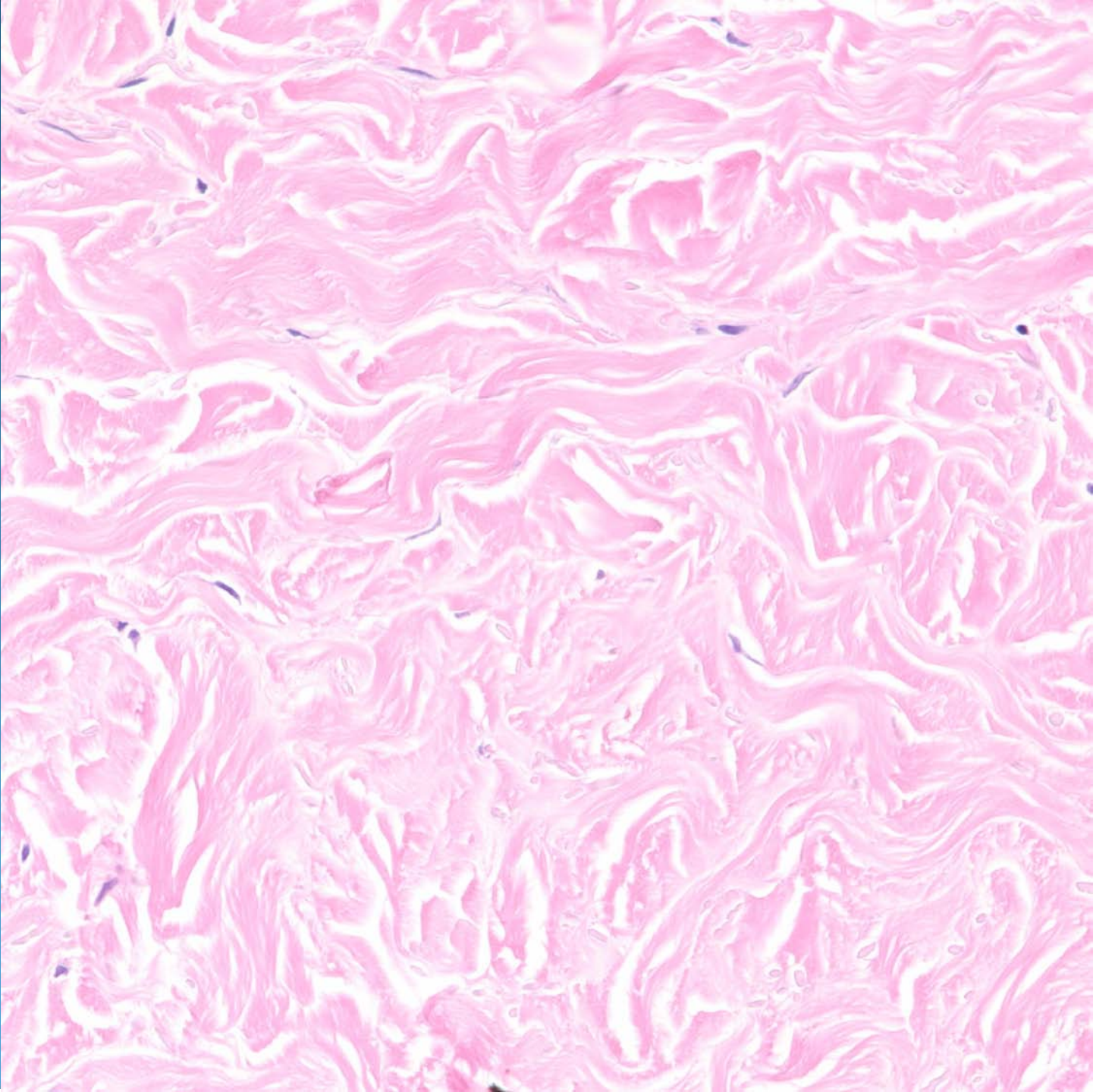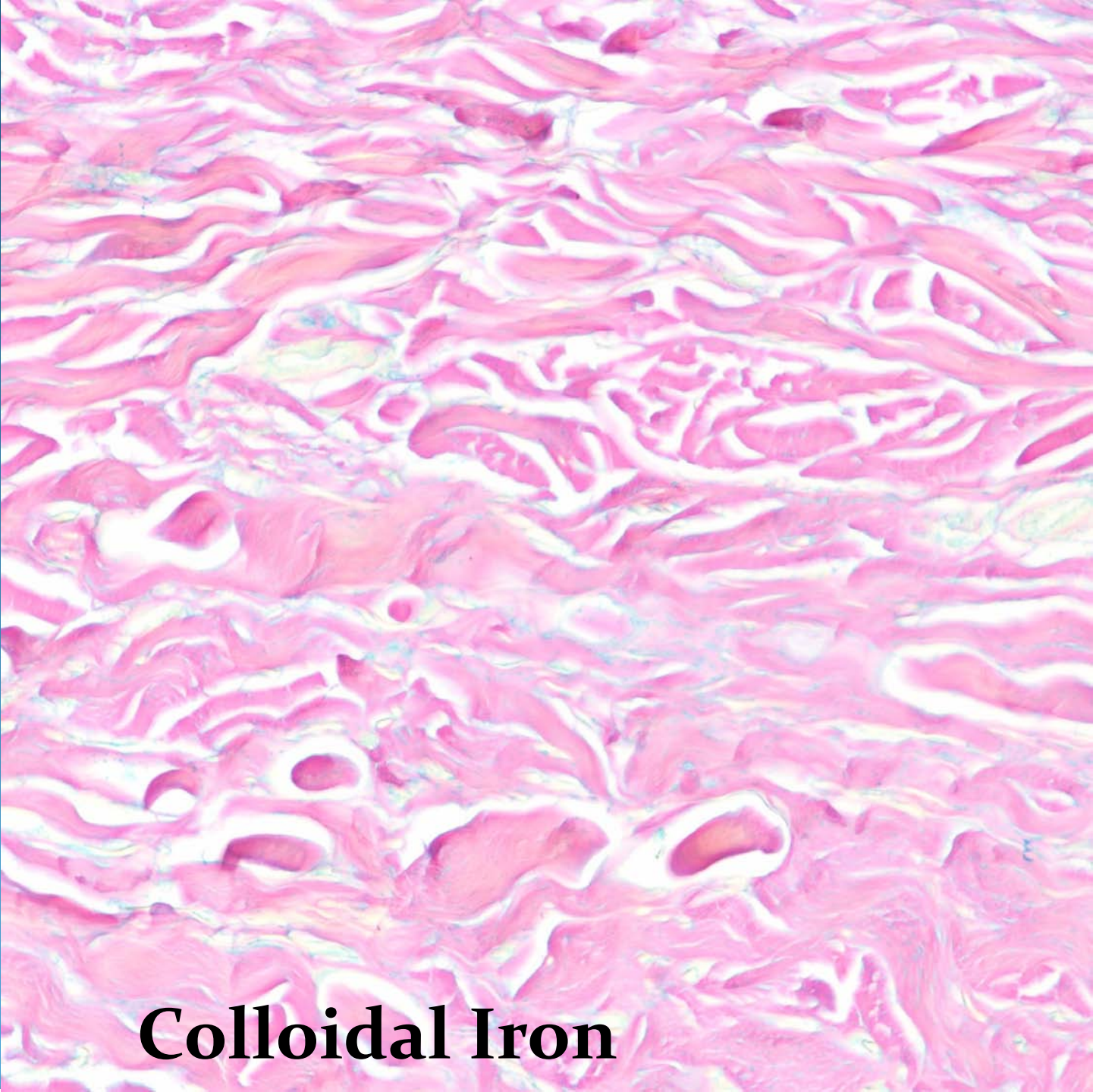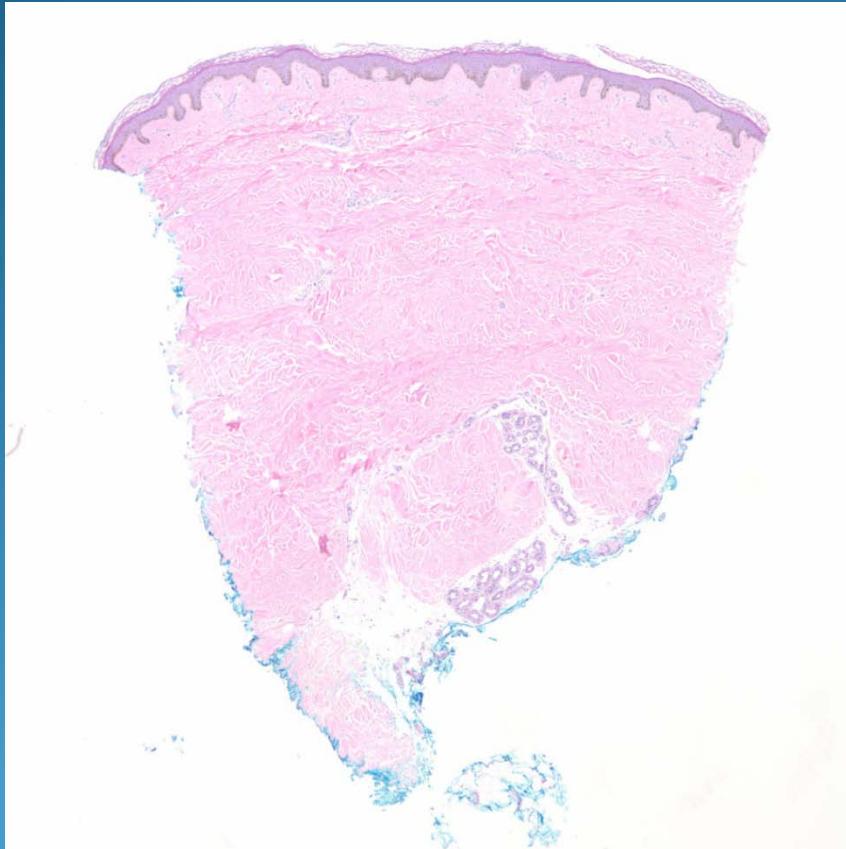


Colloidal Iron

Scleredema

Pearls



- Square biopsy with dermal sclerosis
- Slits in dermis with subtle wispy mucin, confirm with colloidal iron
- Minimal to absent inflammatory infiltrate