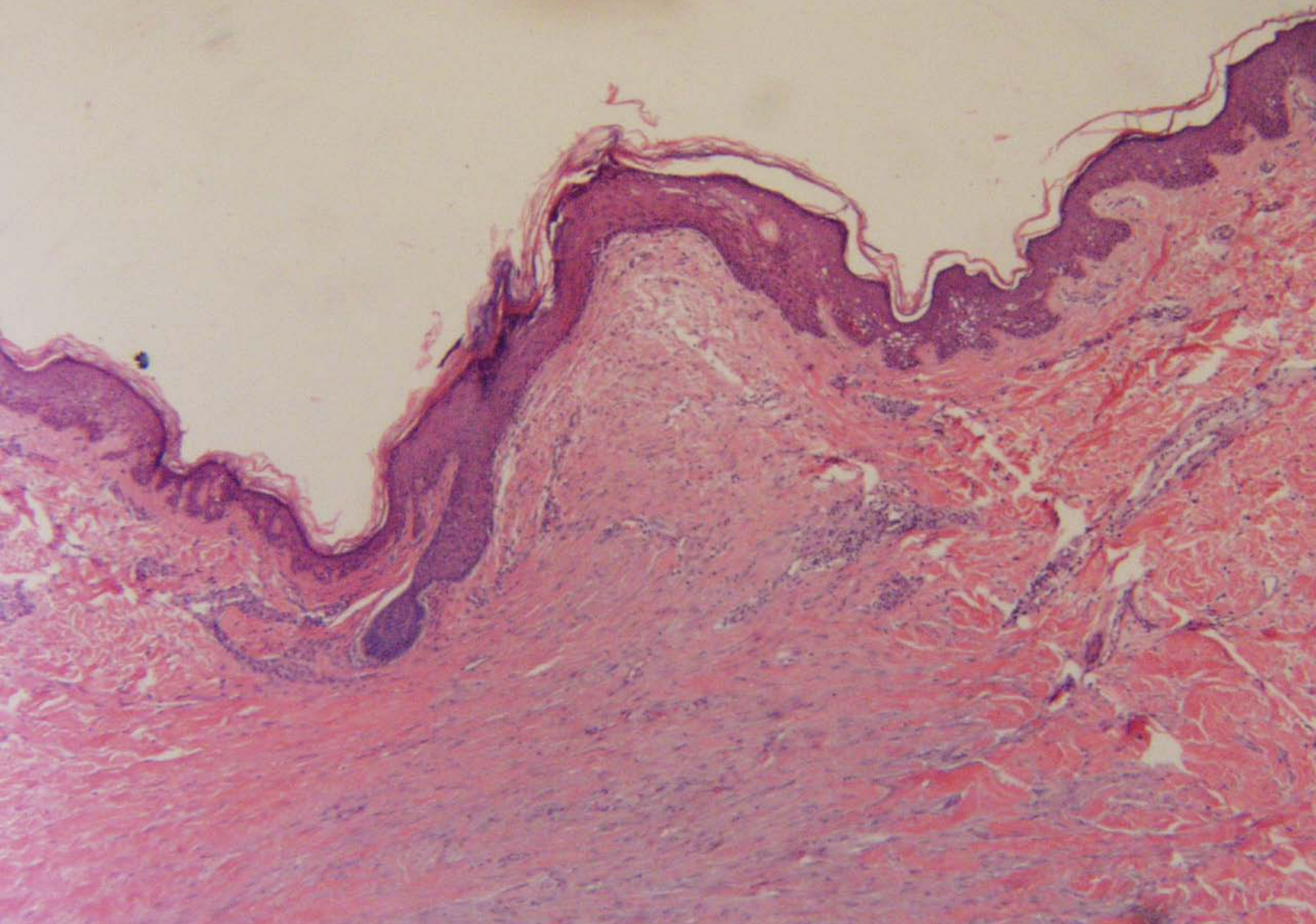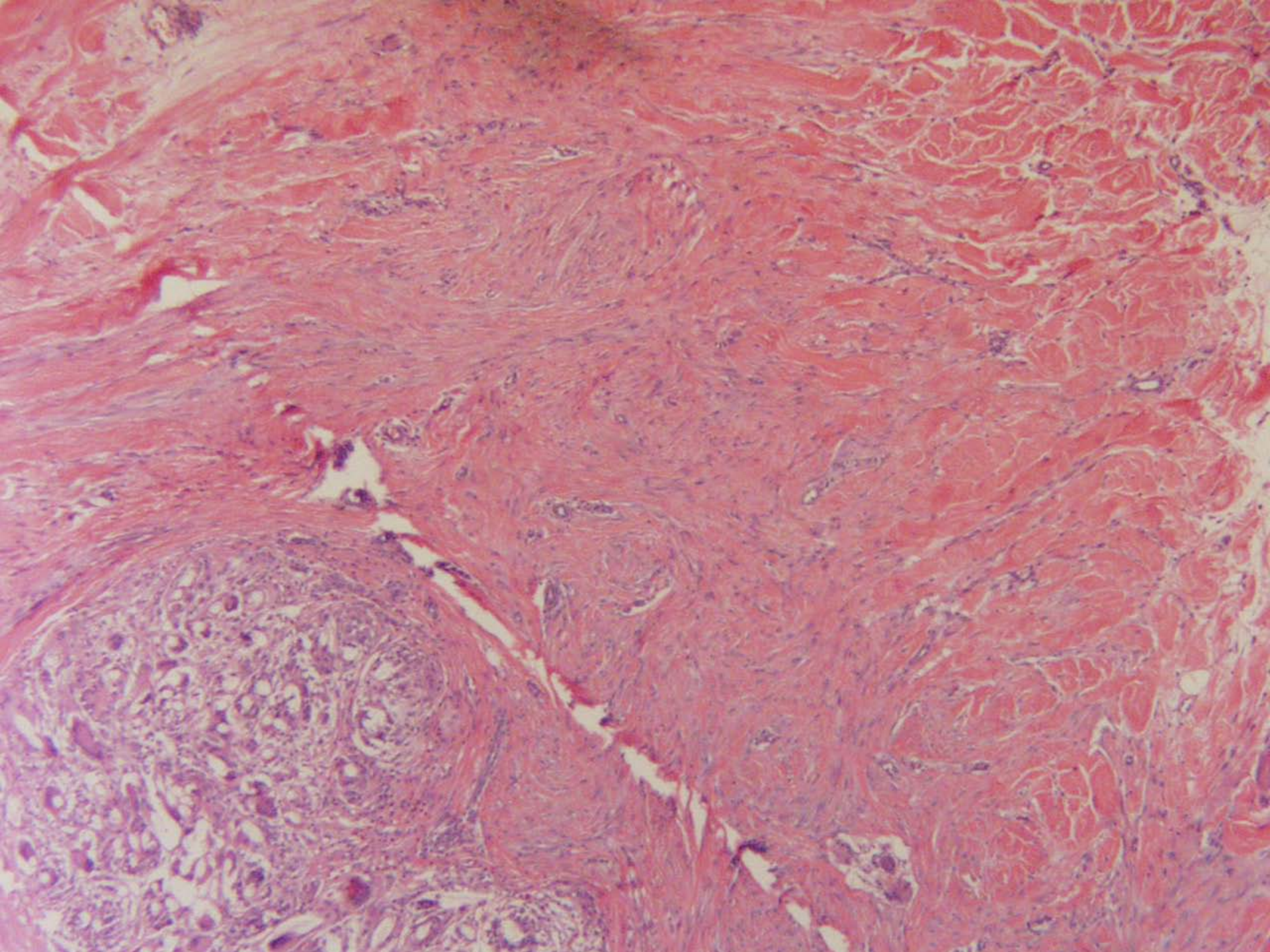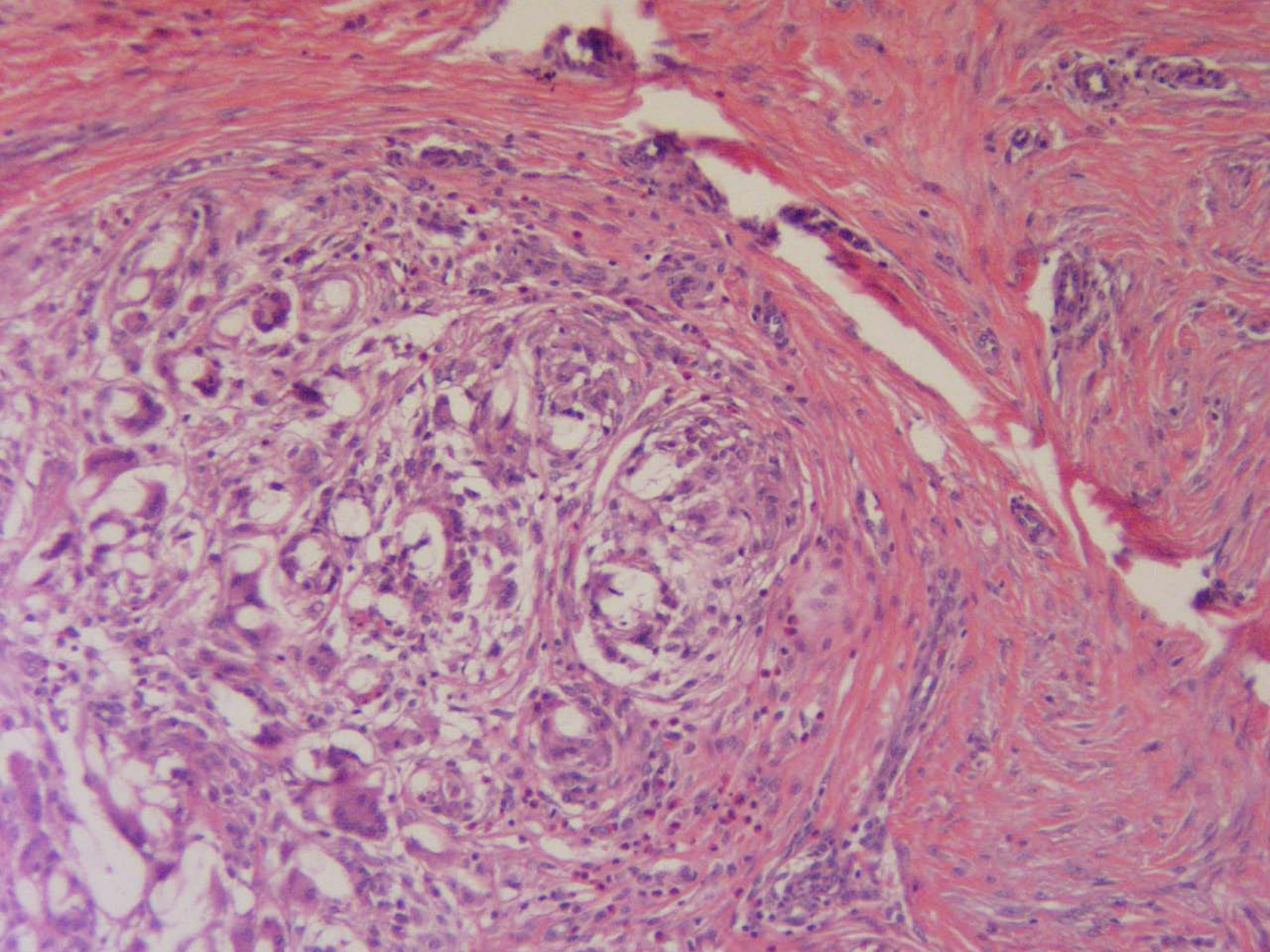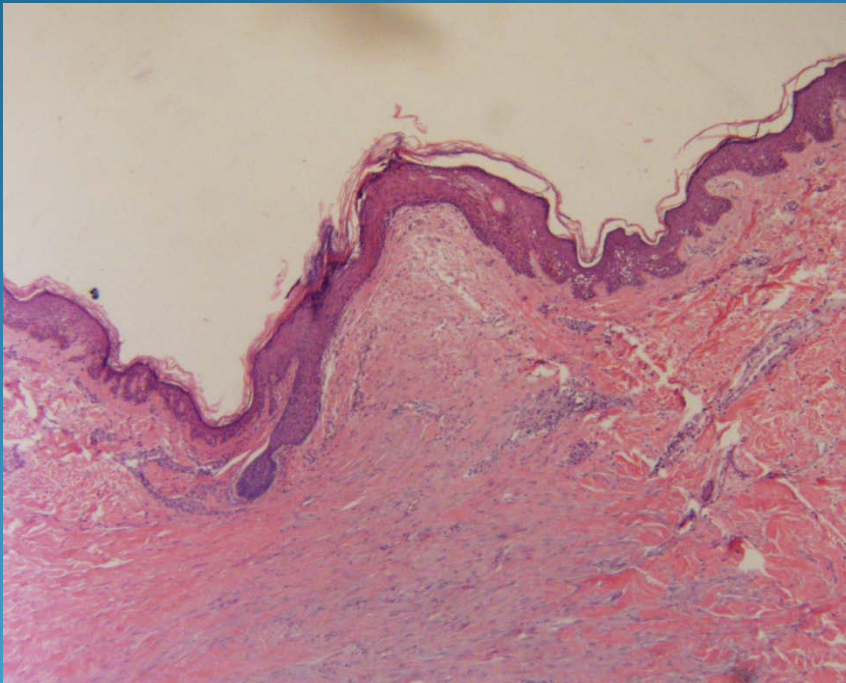


# Scar with Suture Granuloma

# Pearls



- Dermal fibroplasia with vessels oriented perpendicular to epidermis
- Flattening of rete ridges overlying scar
- May show “knife chatter” or skipping due to hard cutting surface of tissue