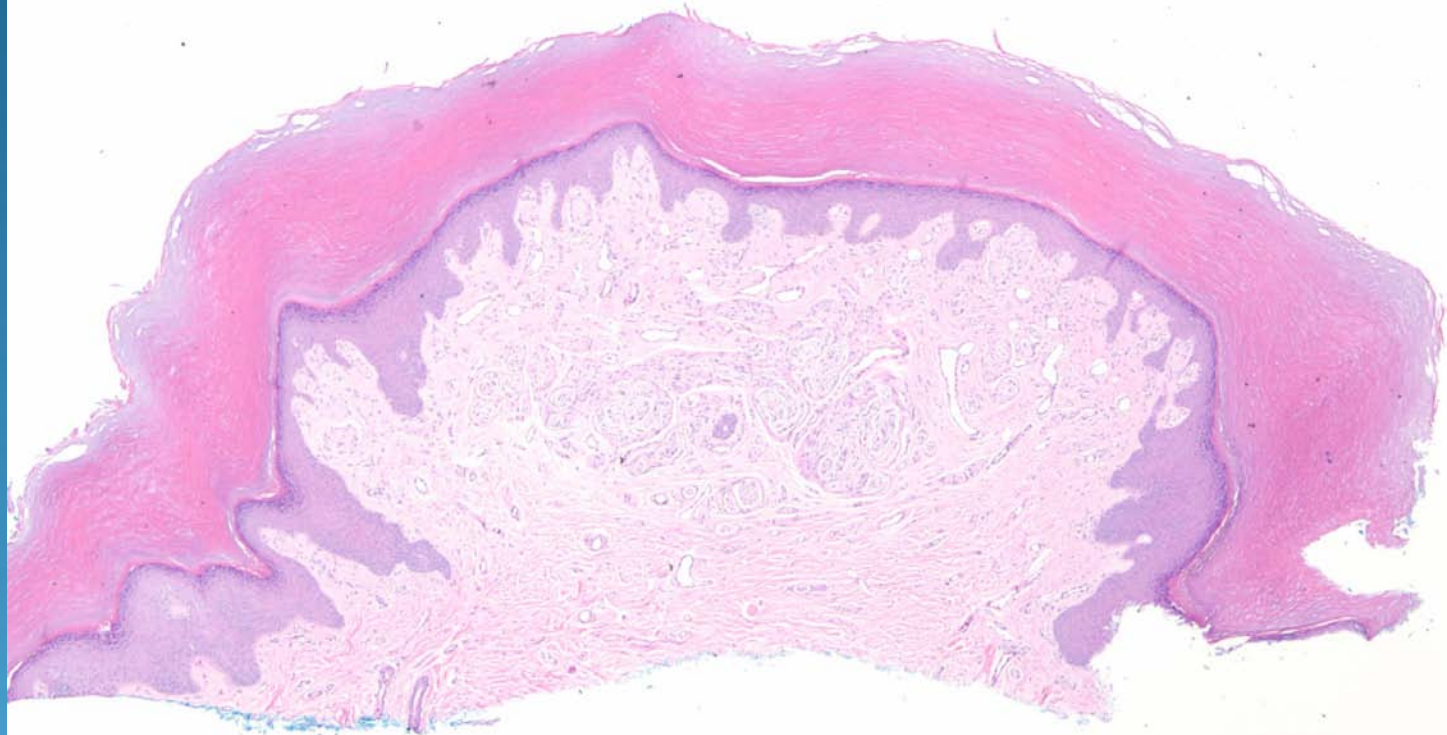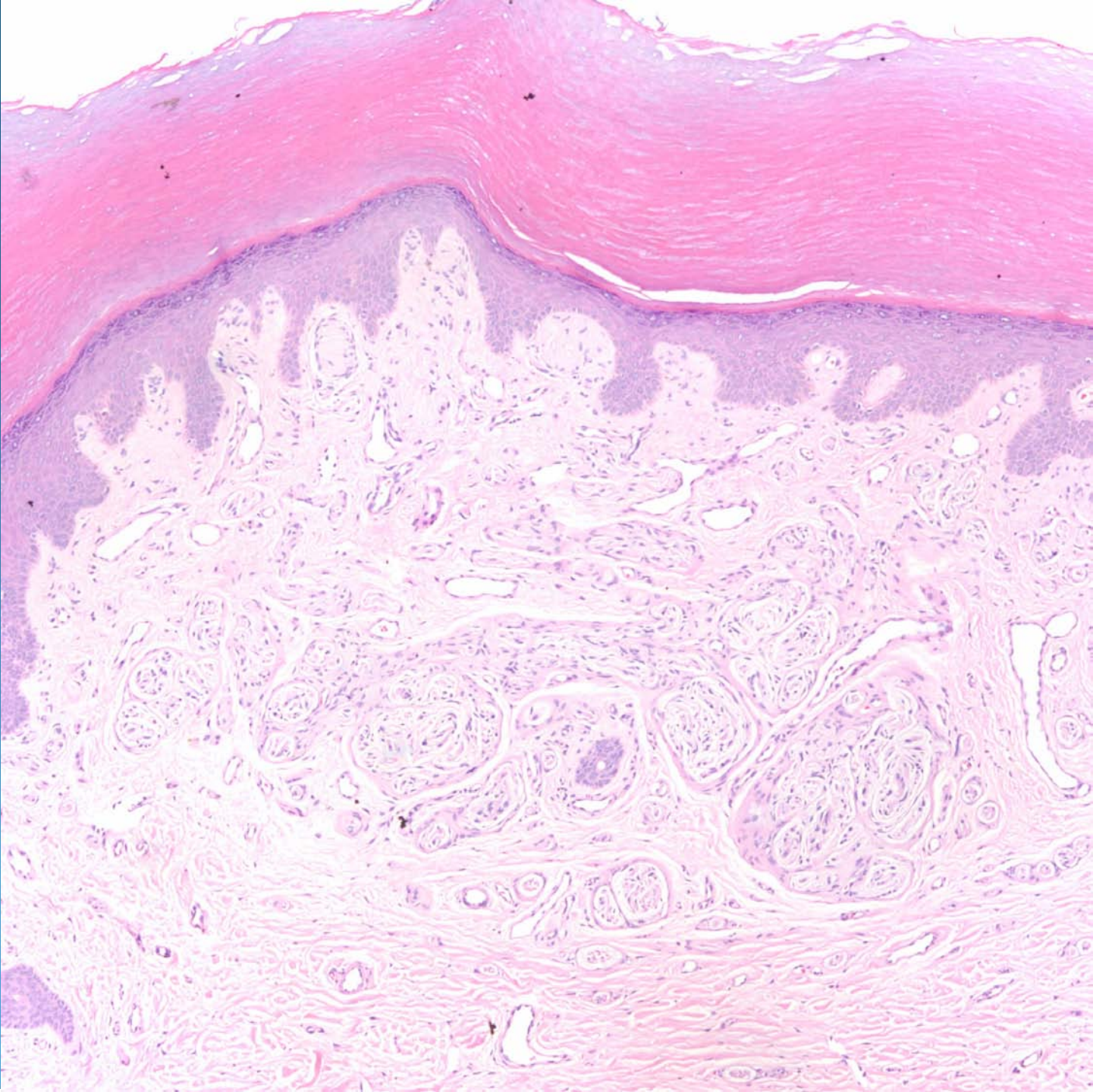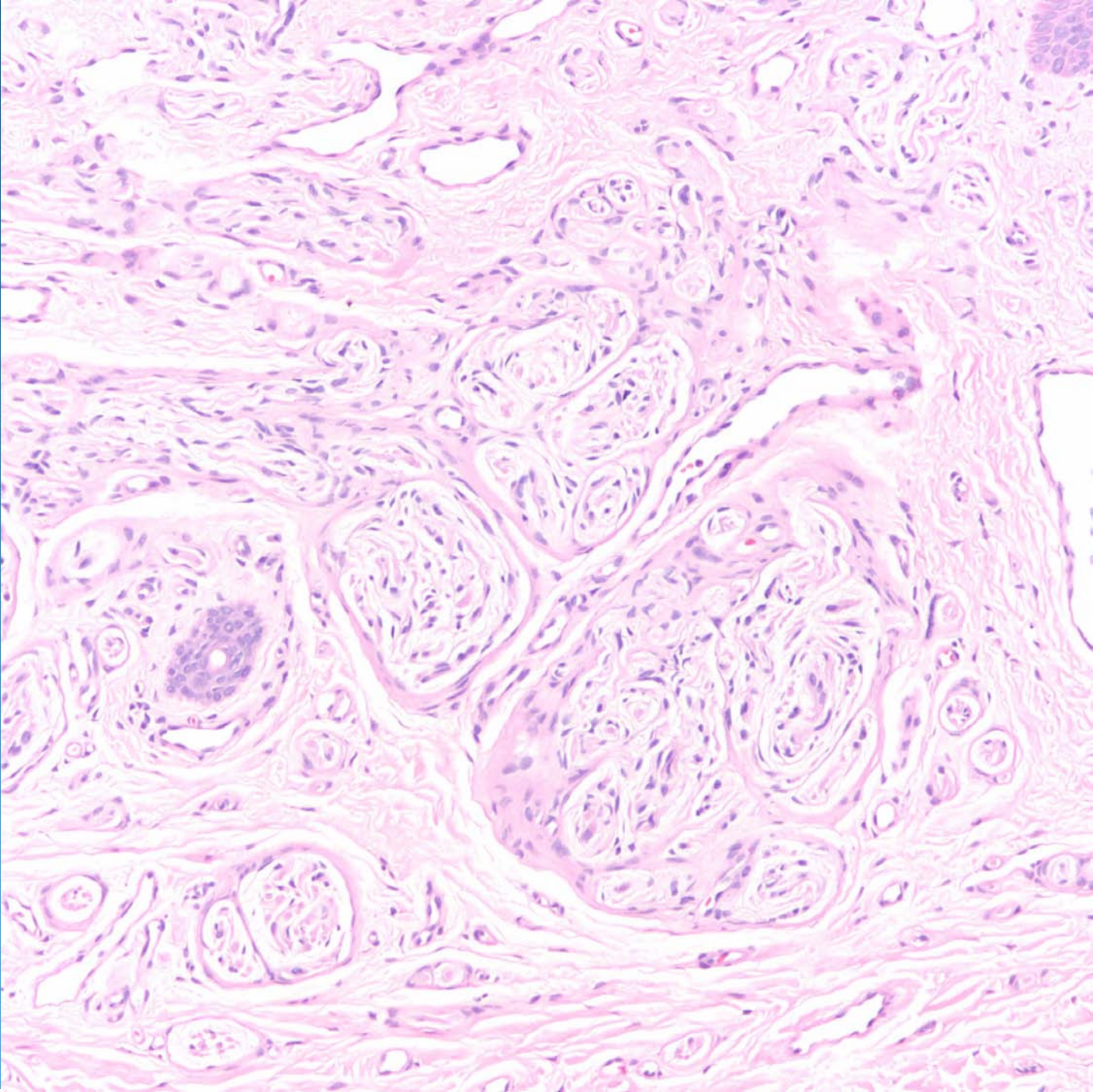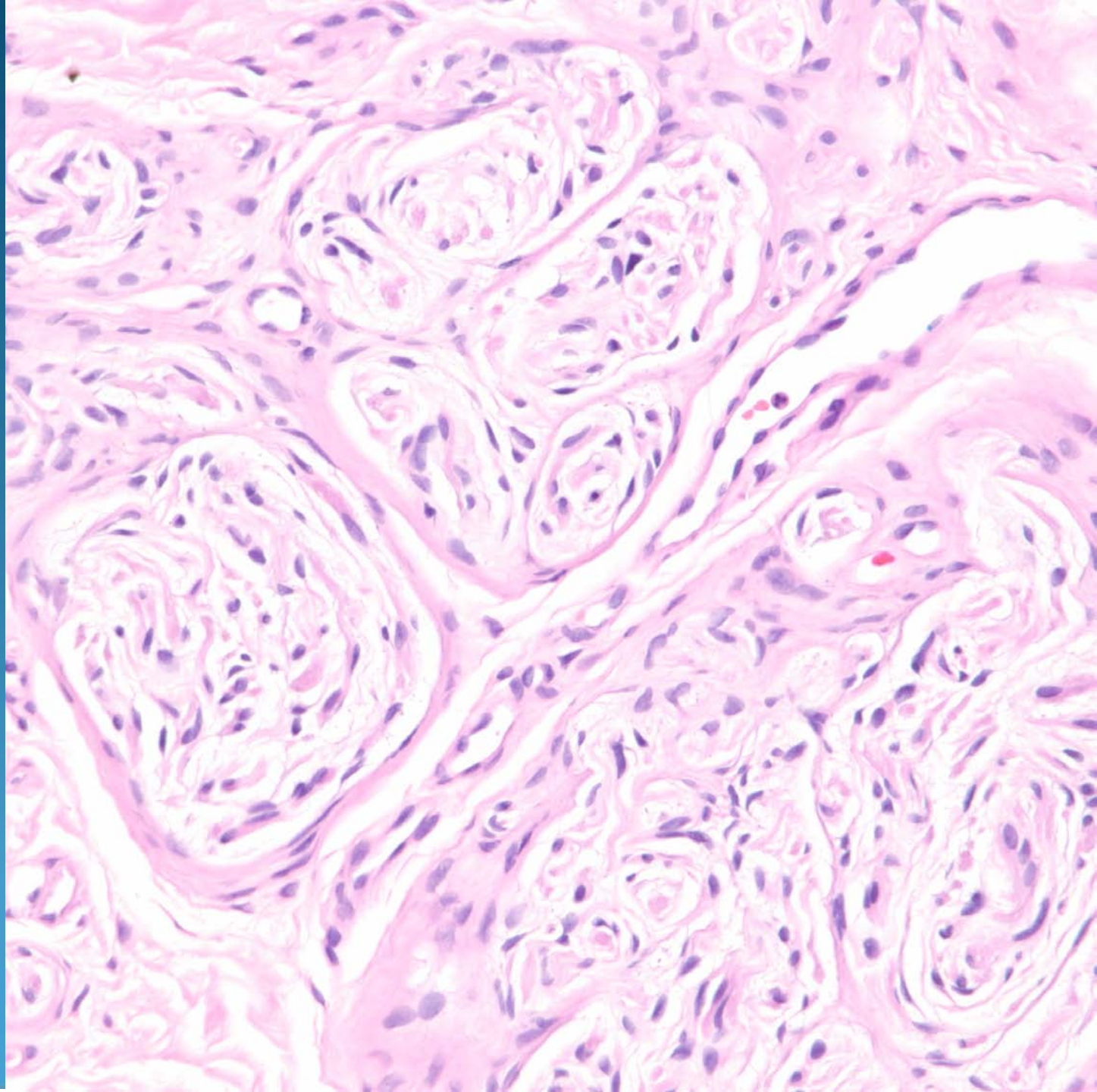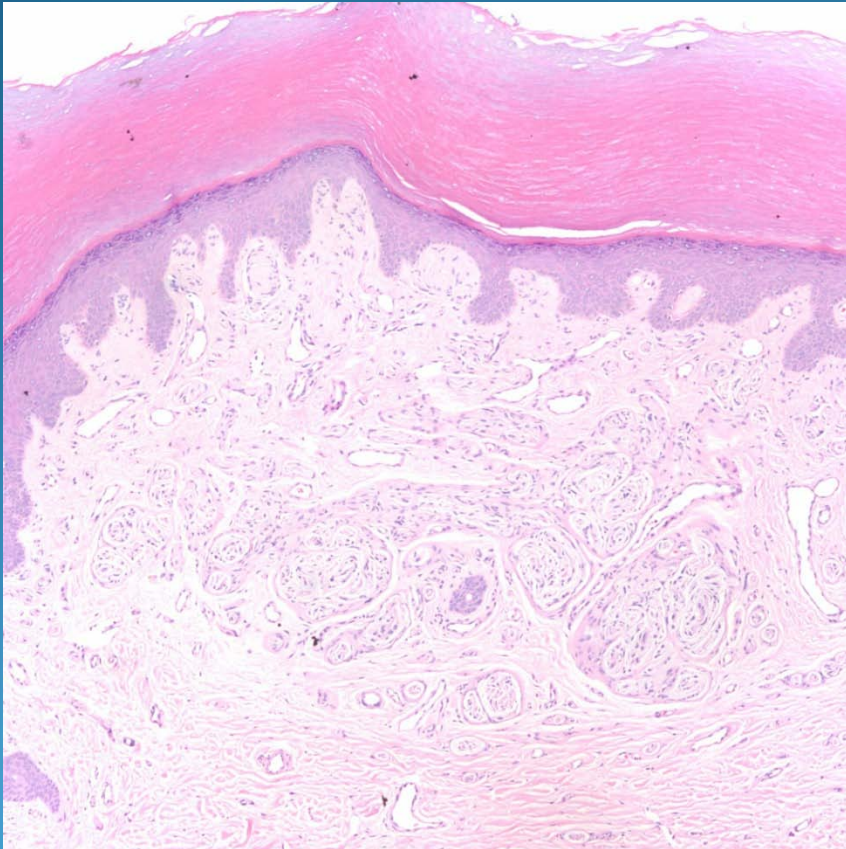


Rudimentary Polydactyly  
(Supernumerary Digit)

# Pearls



- Acral location and clinical correlation
- Varying collection of myelinated nerve bundles, may be interrupted by fibrosis
- Localized in superficial dermis
- May be a variant of accessory digit (supernumerary digit)