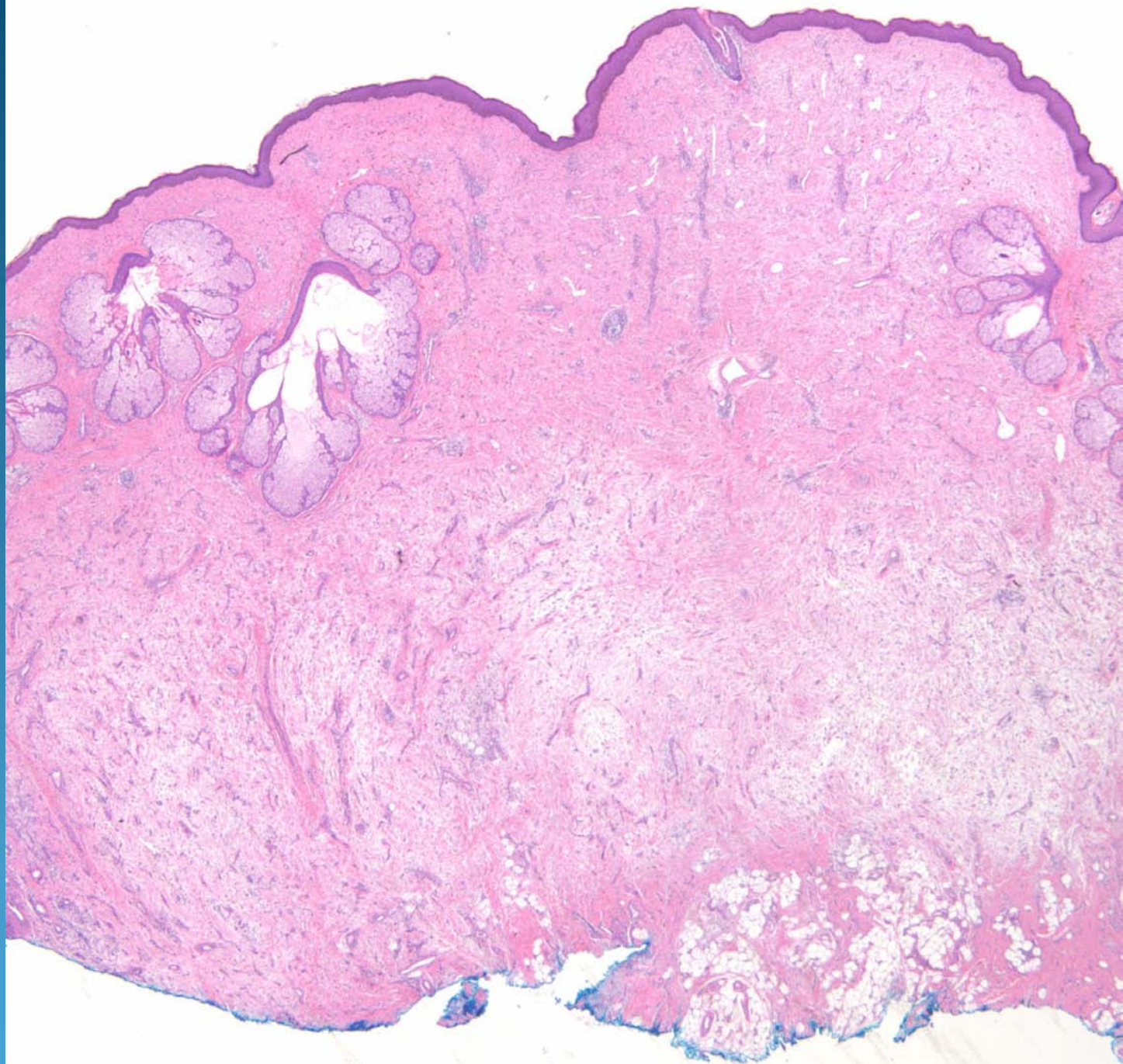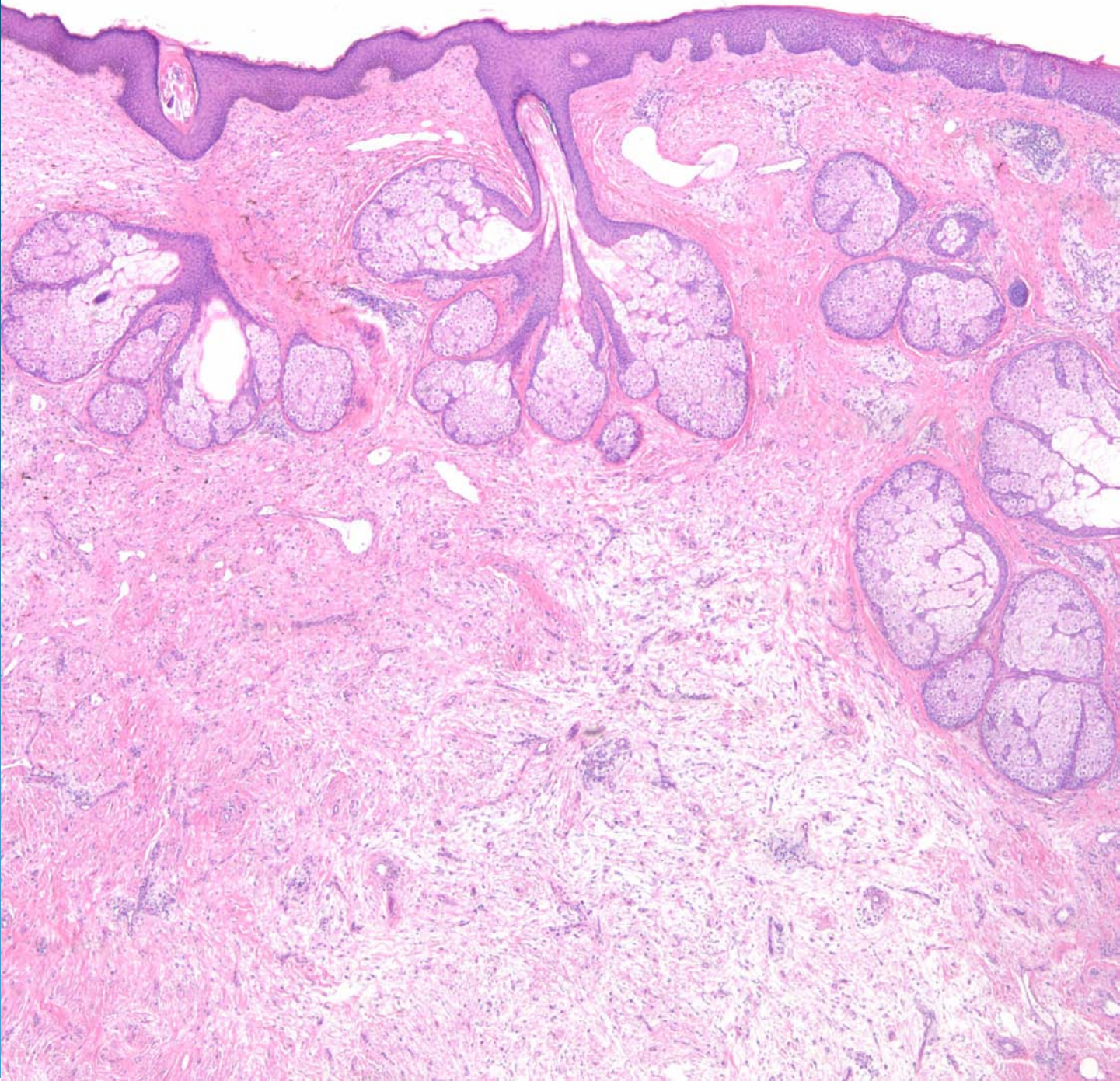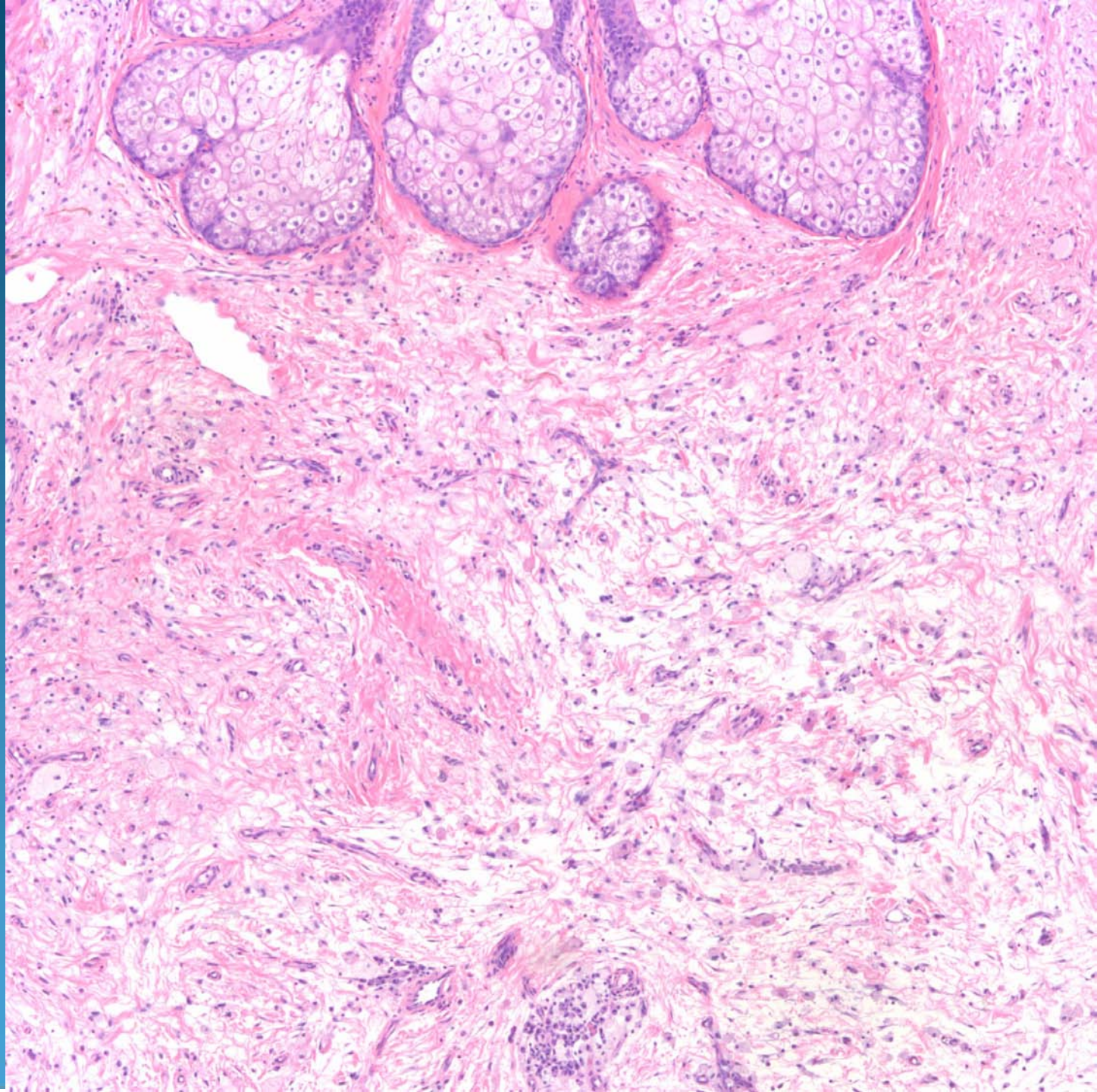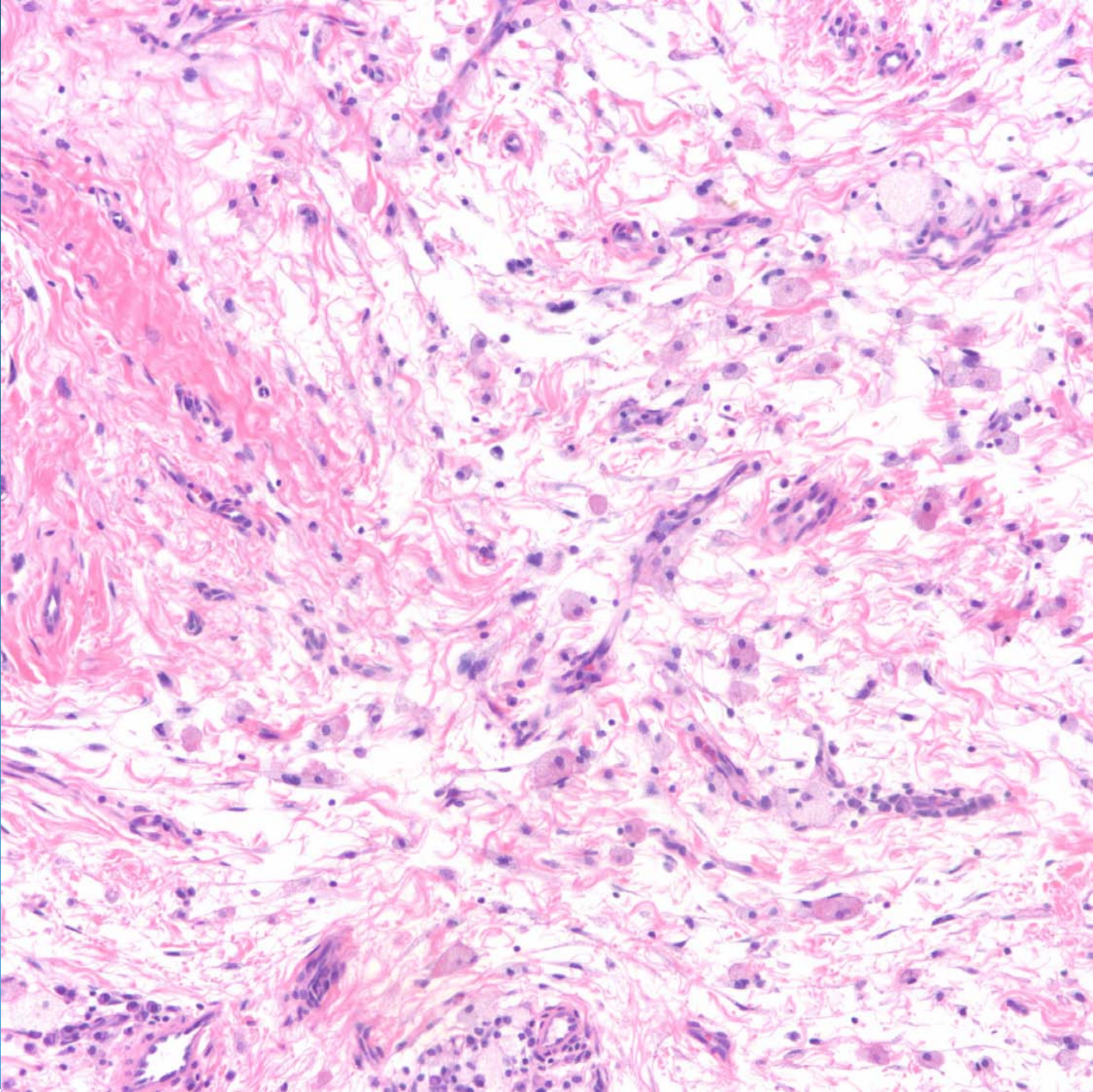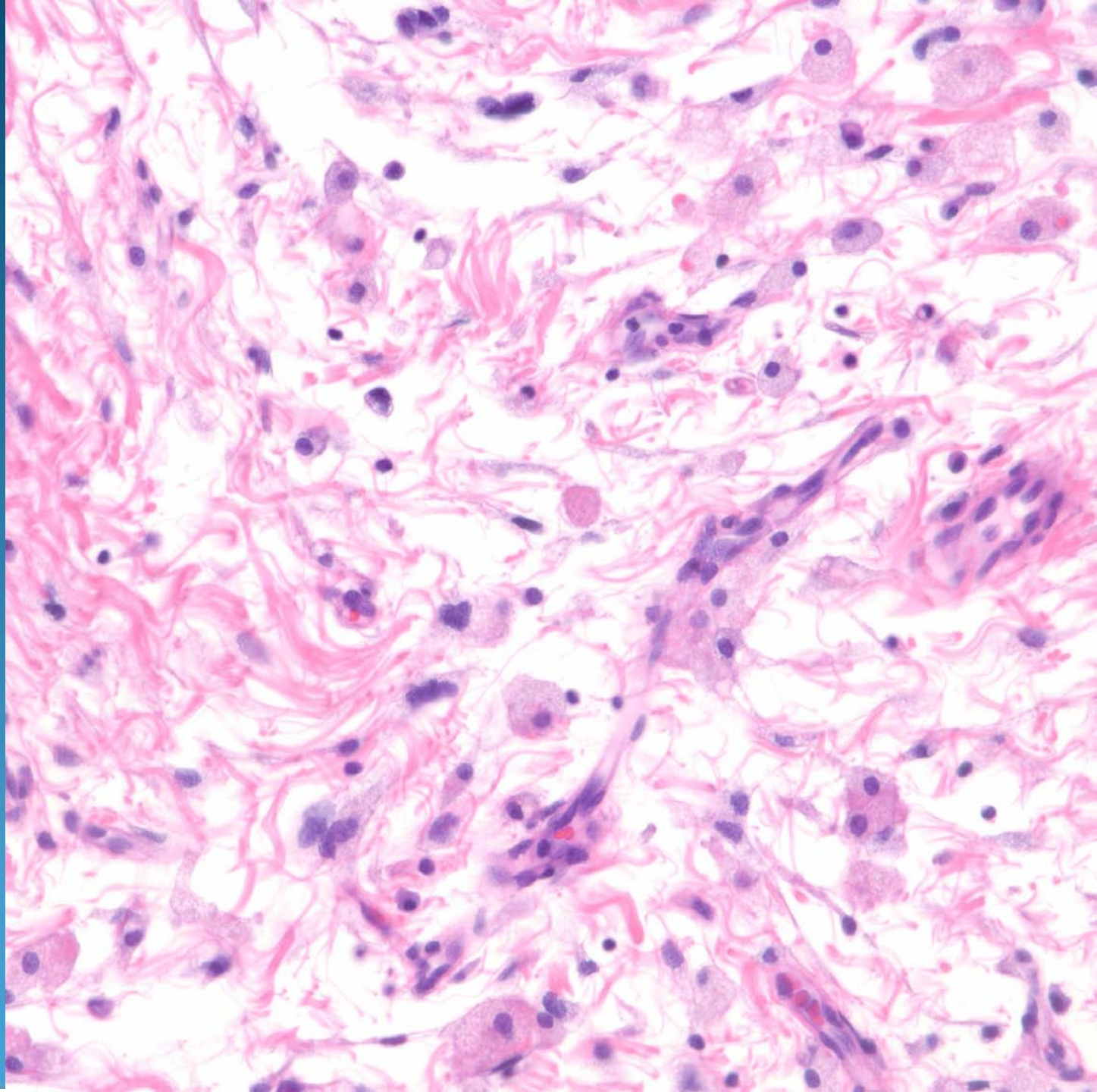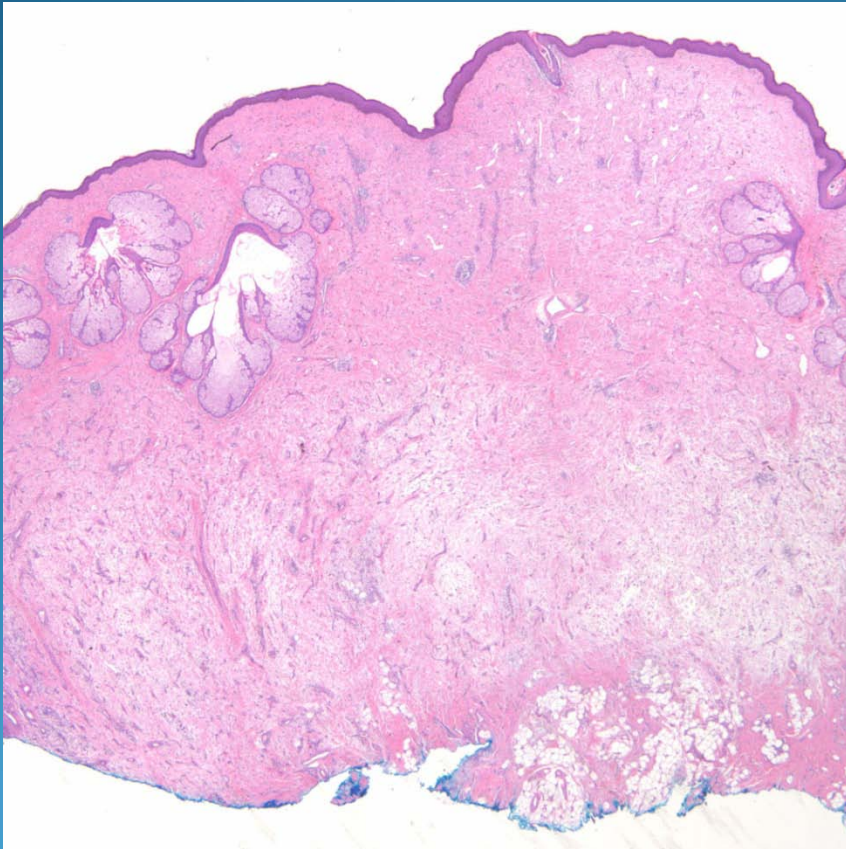


Rhinophyma

Pearls



- Variable depending upon severity but usually polypoid
- Edema, scarring, and varying sebaceous gland hyperplasia
- Variable evidence of chronic folliculitis and rosacea