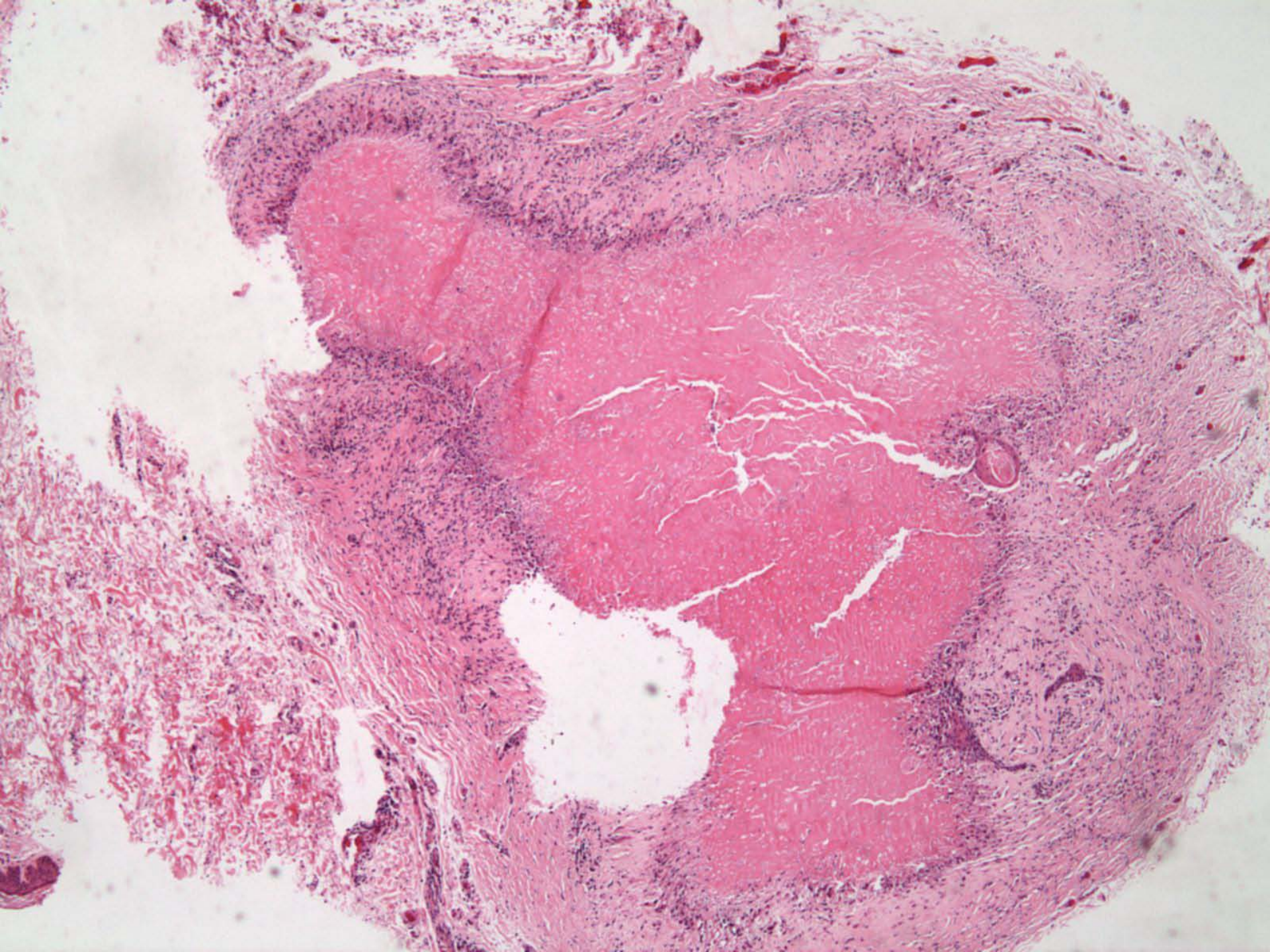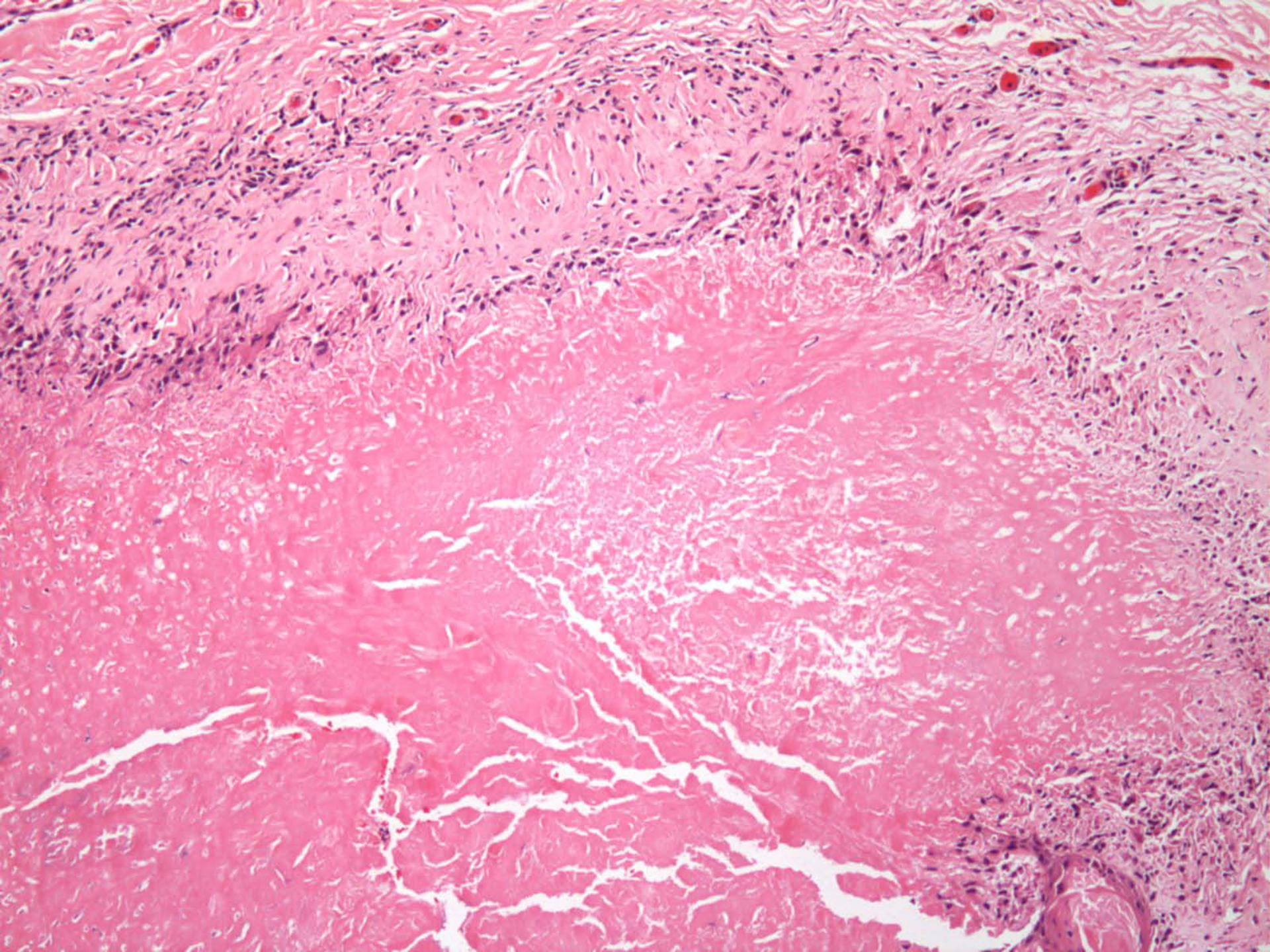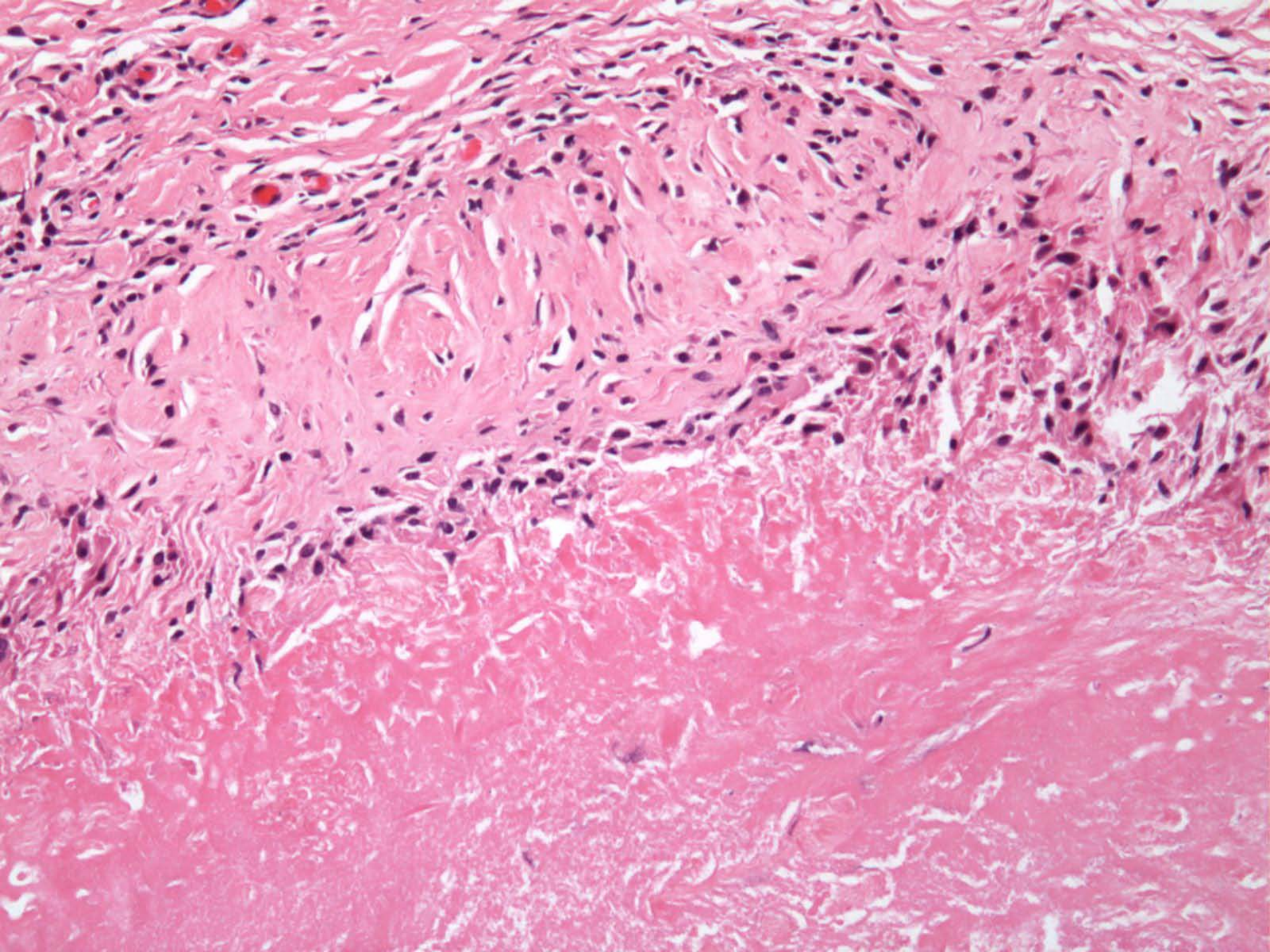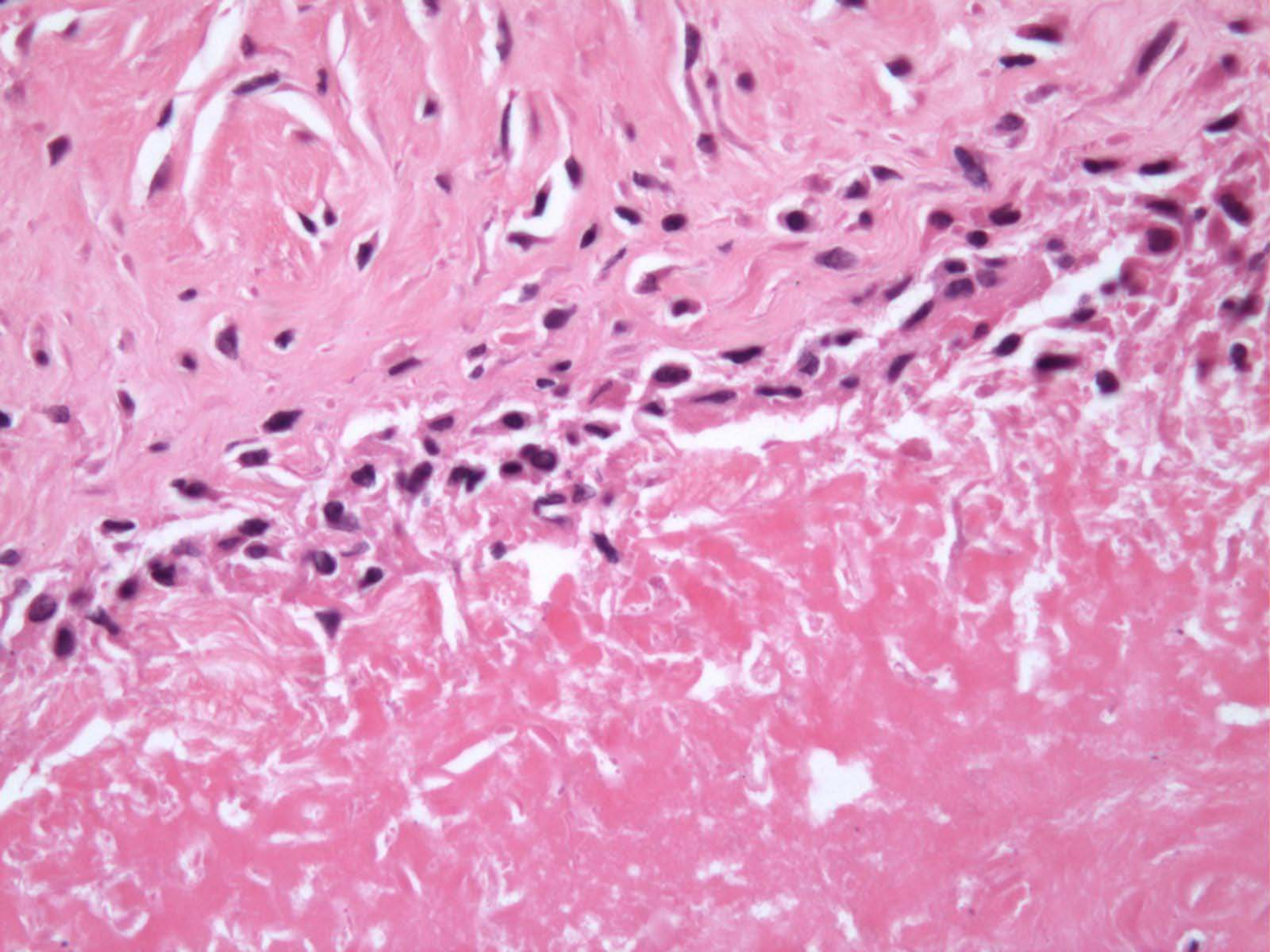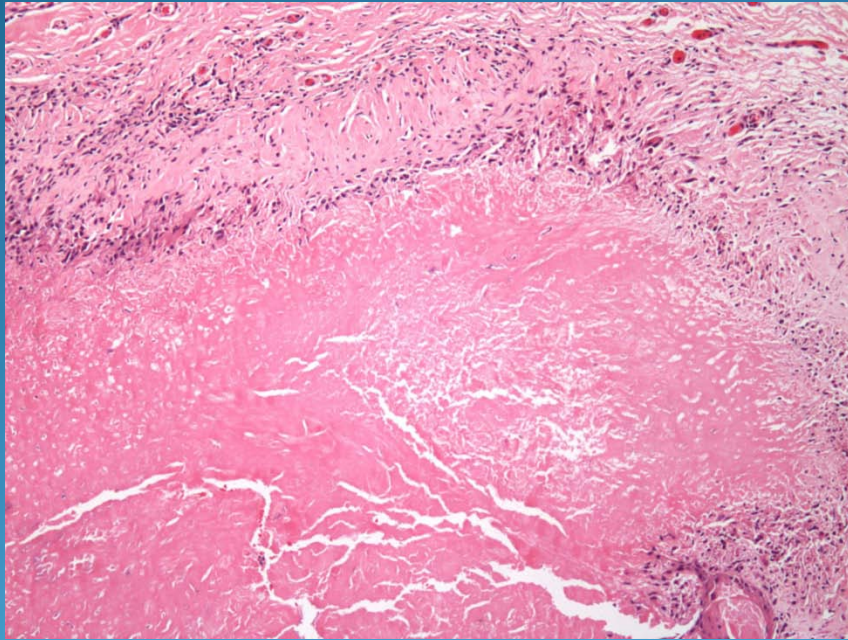


Rheumatoid Nodule

Pearls



- Deep lesion
- Histiocytes surrounding necrobiosis
- Cannot distinguish from deep GA