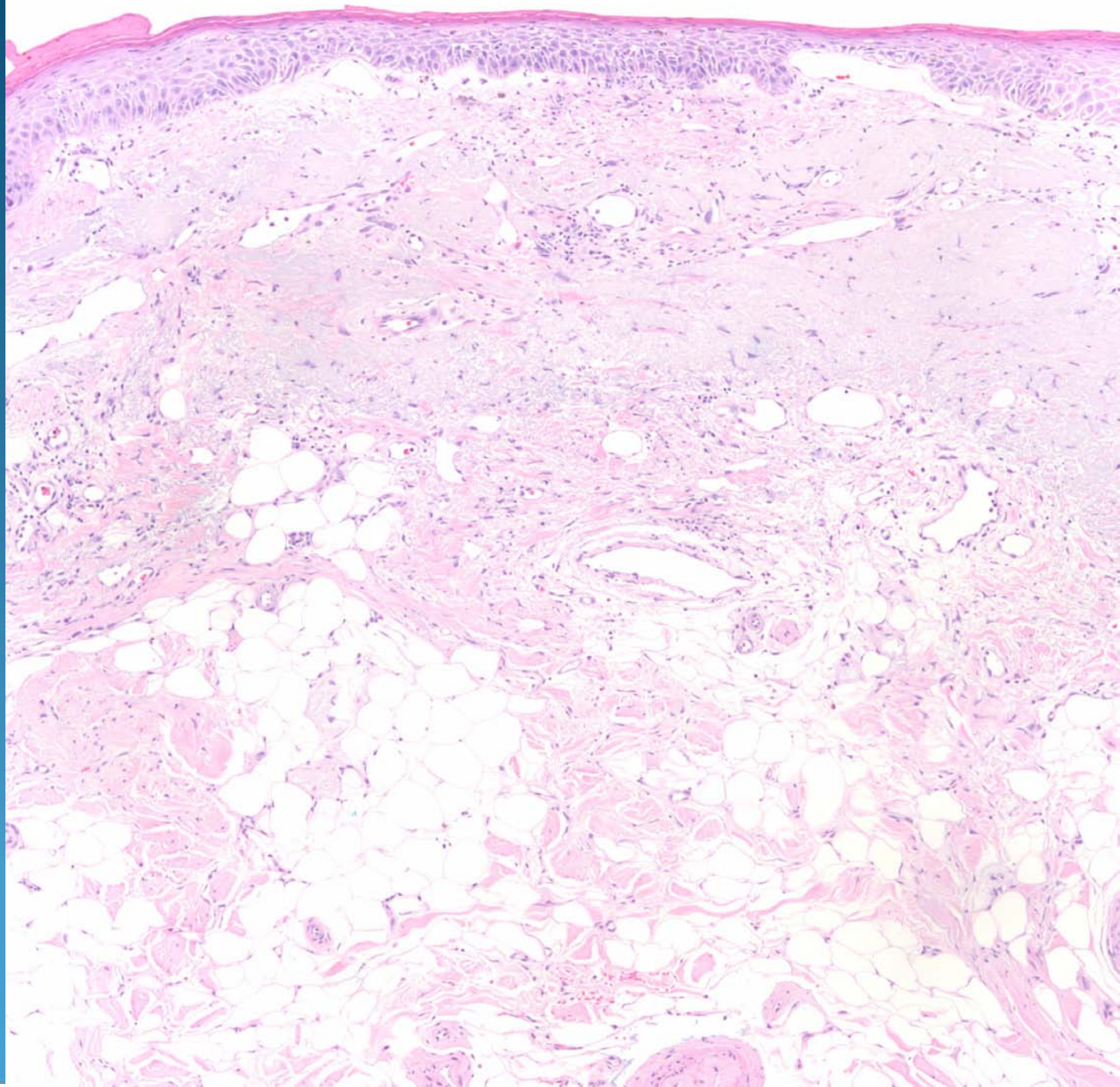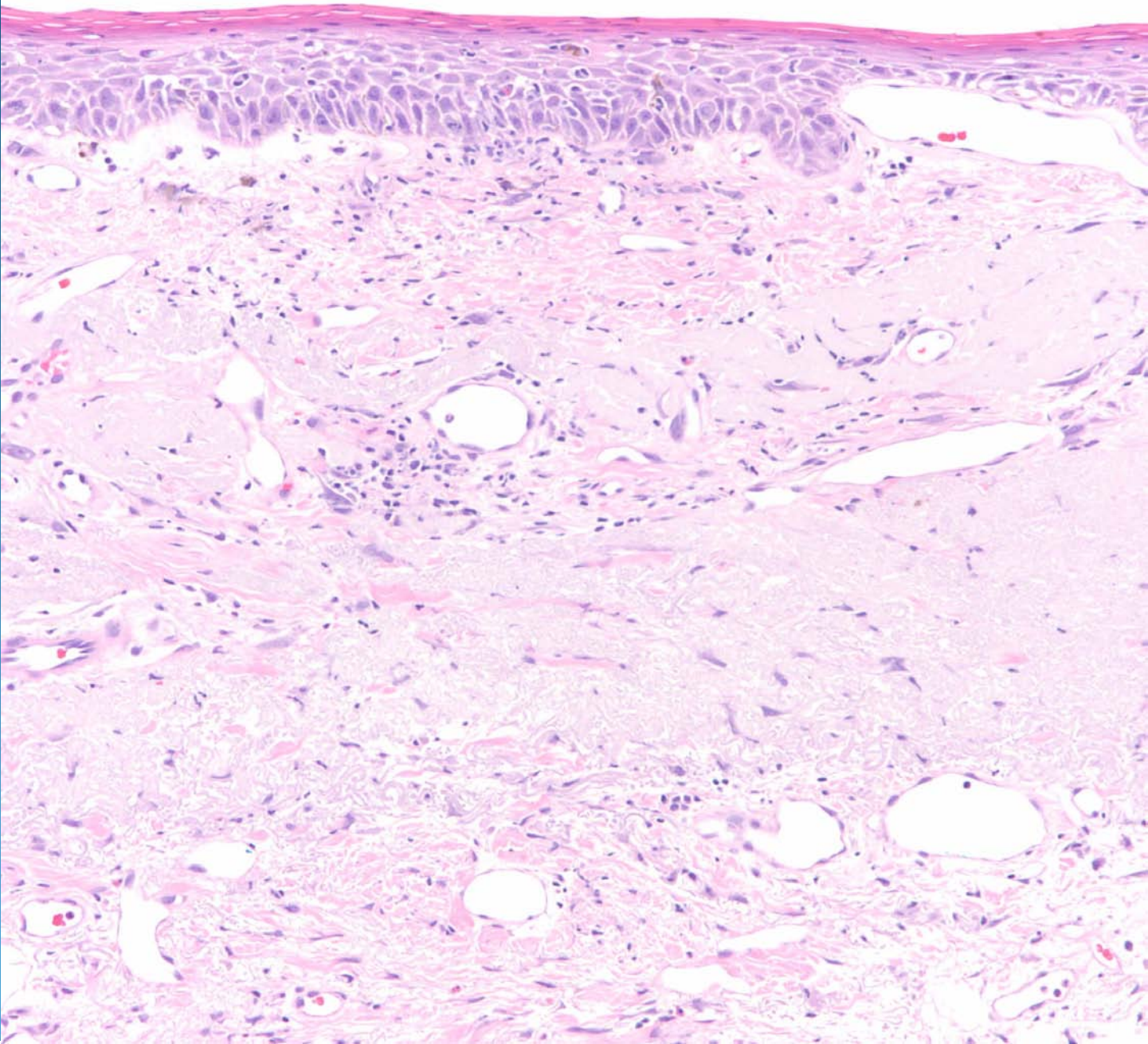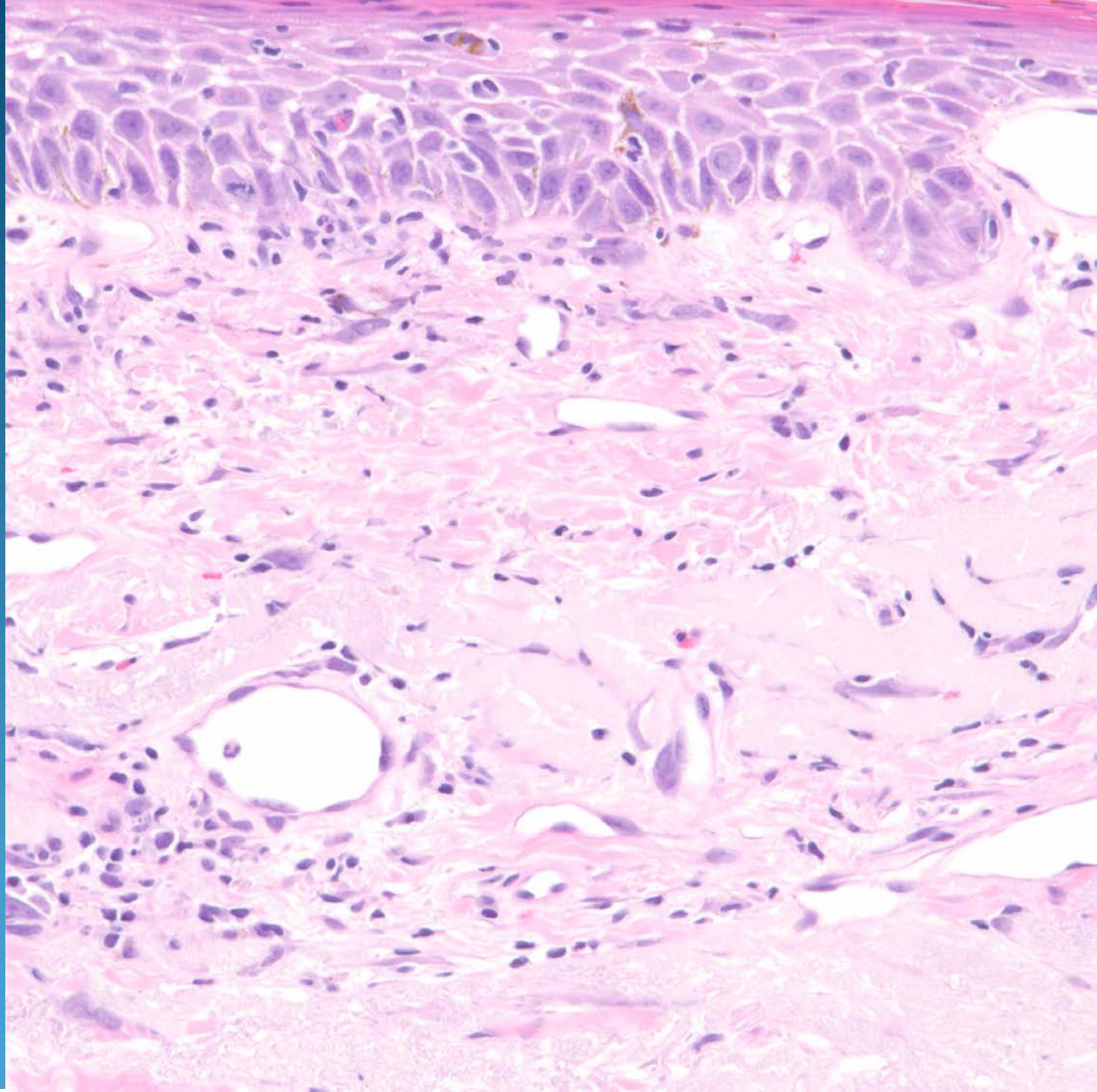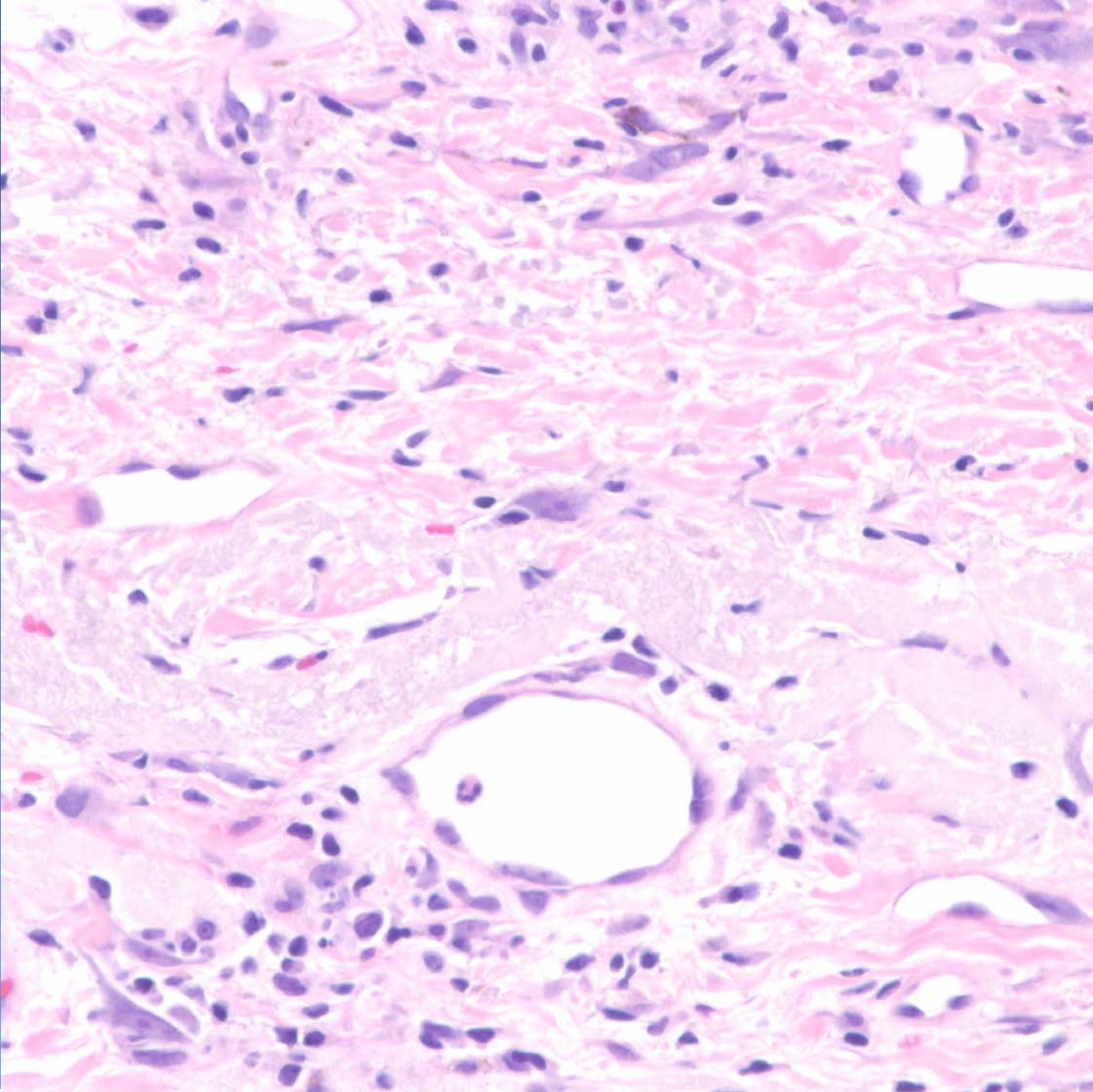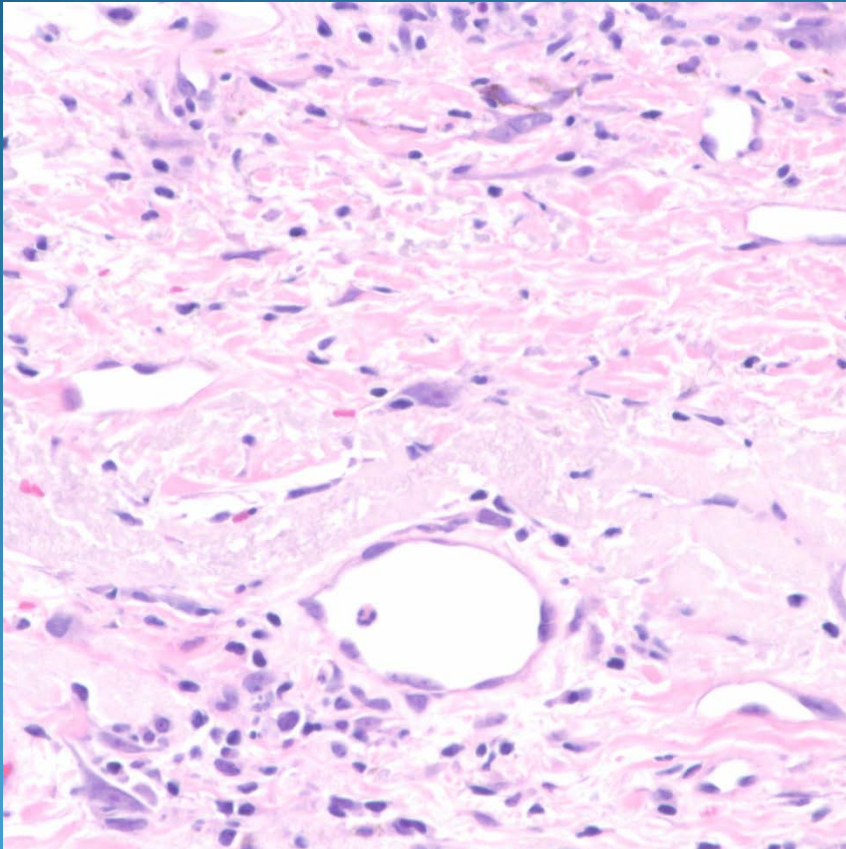


Radiation Dermatitis, Subacute

Pearls



- Variable histopathology but usually edema with focal hemorrhage
- Dilated capillary sized vessels
- Scattered atypical fibroblasts with hyperchromatic nuclei with “smudged” nuclear chromatin