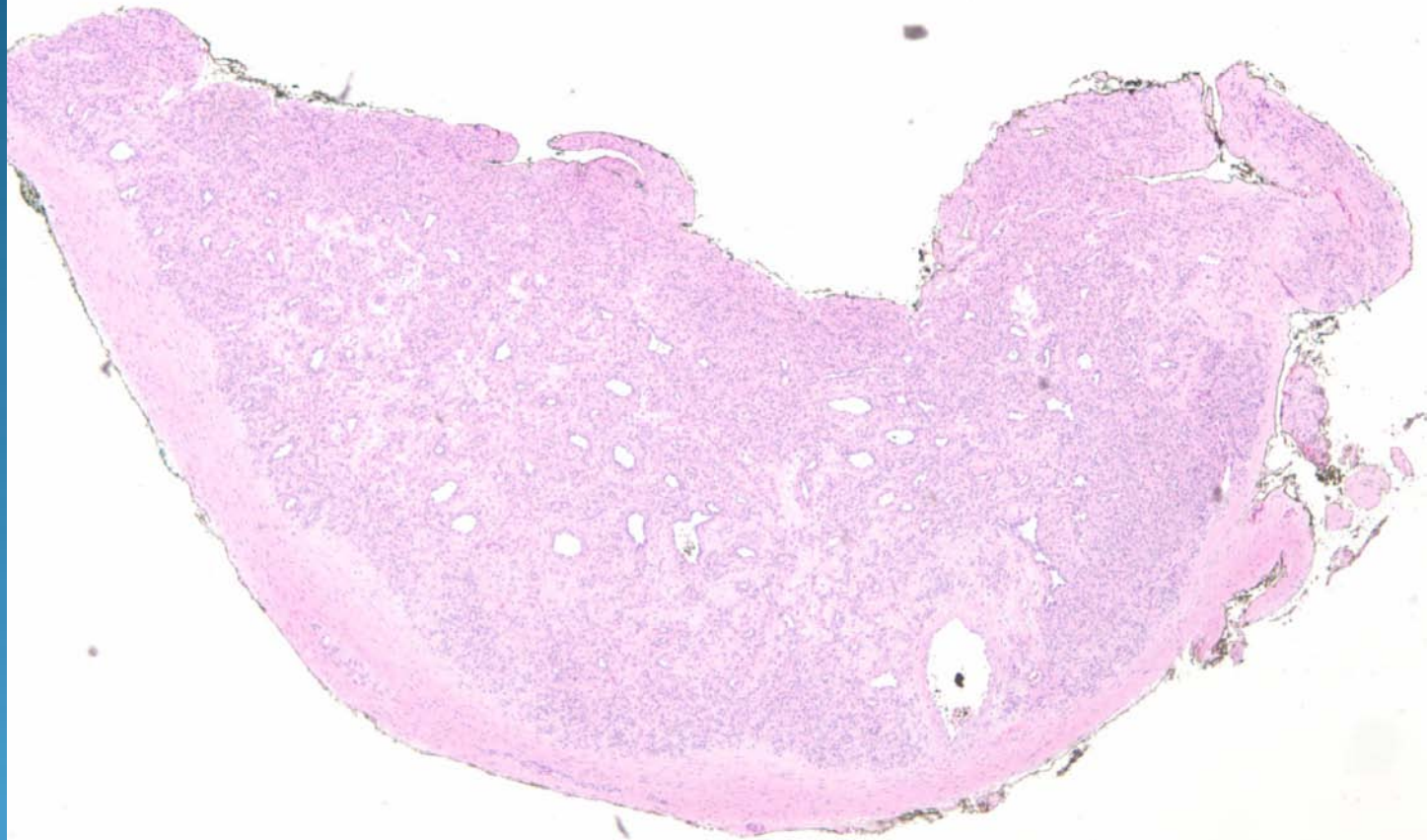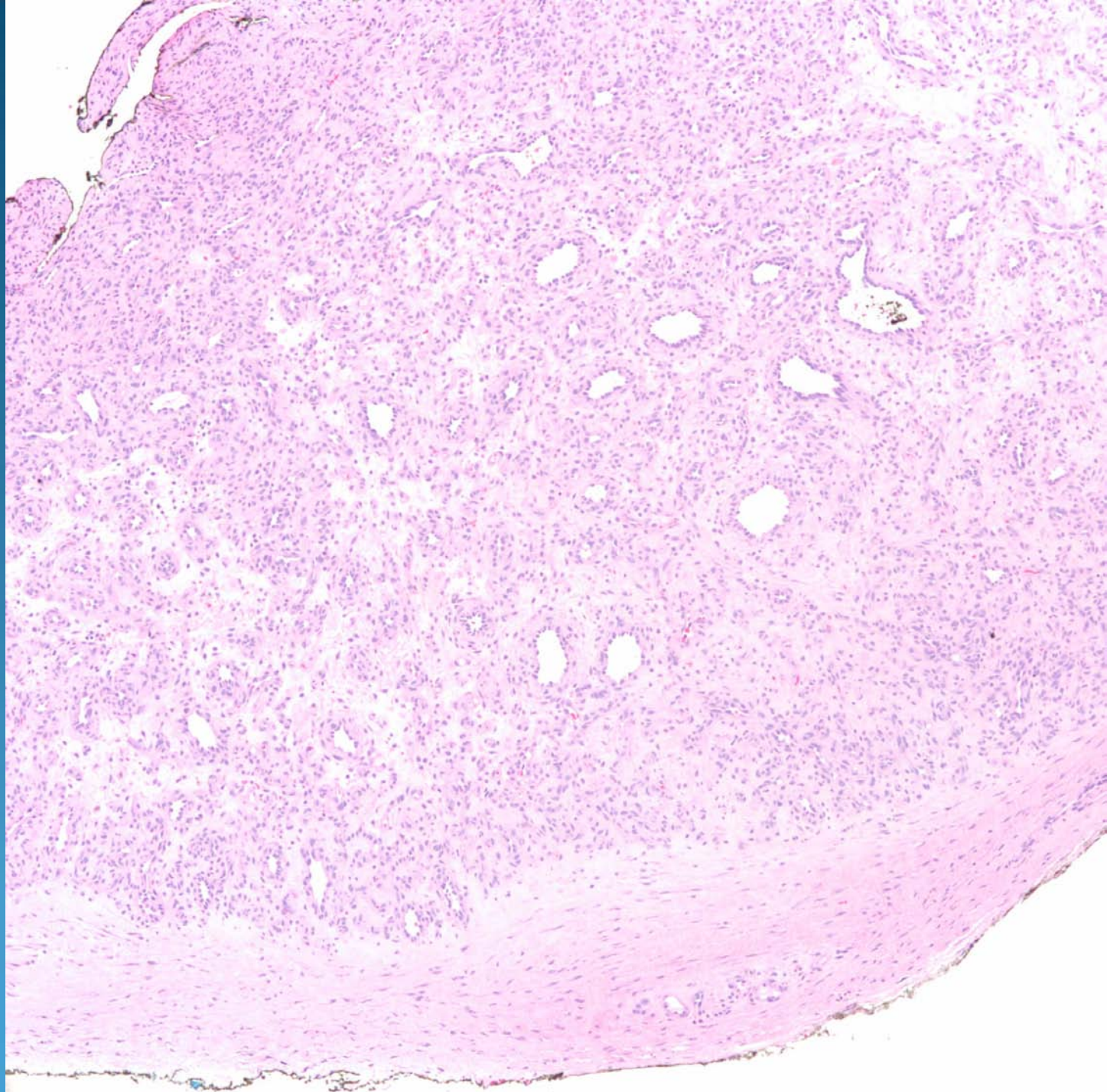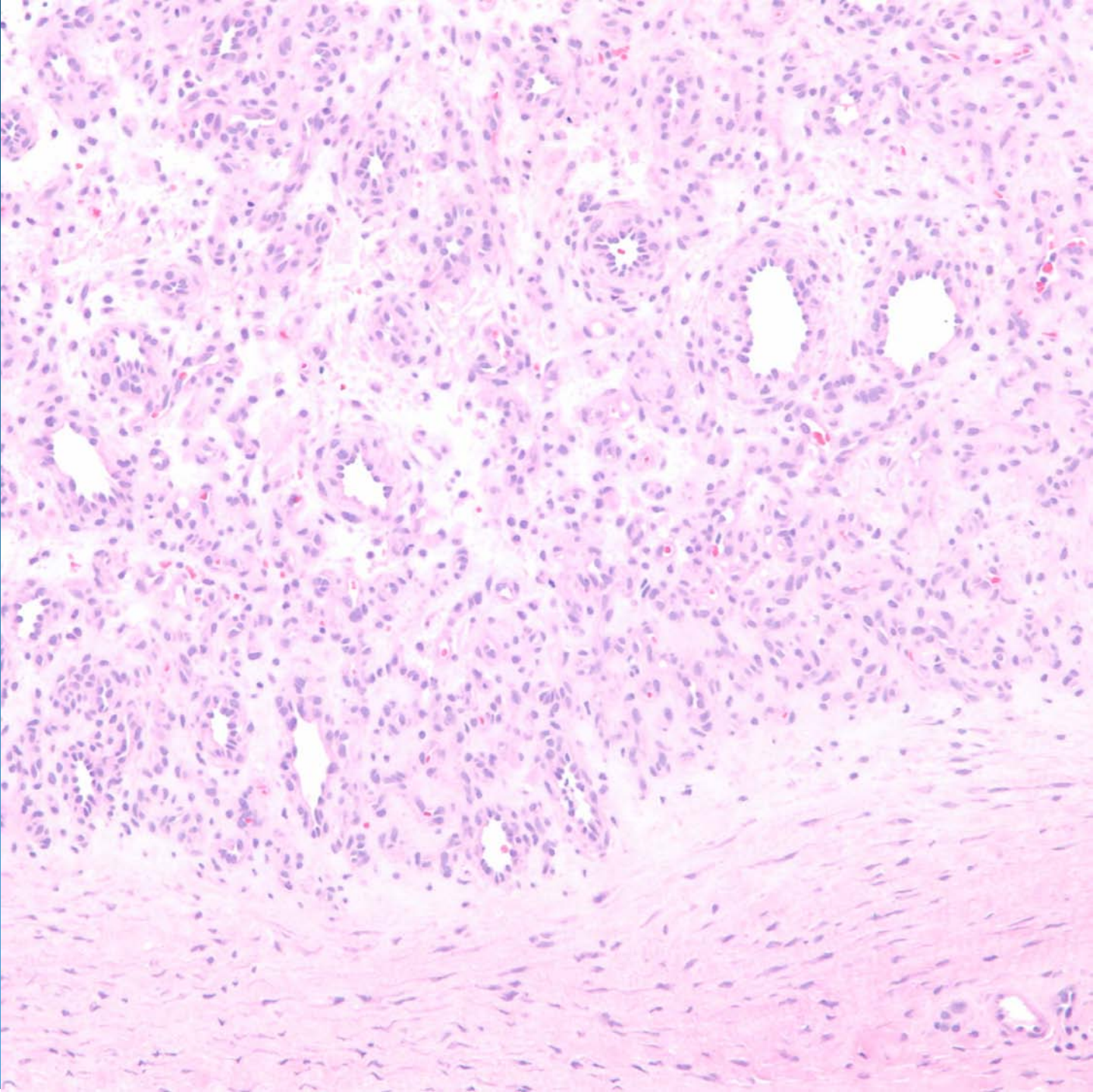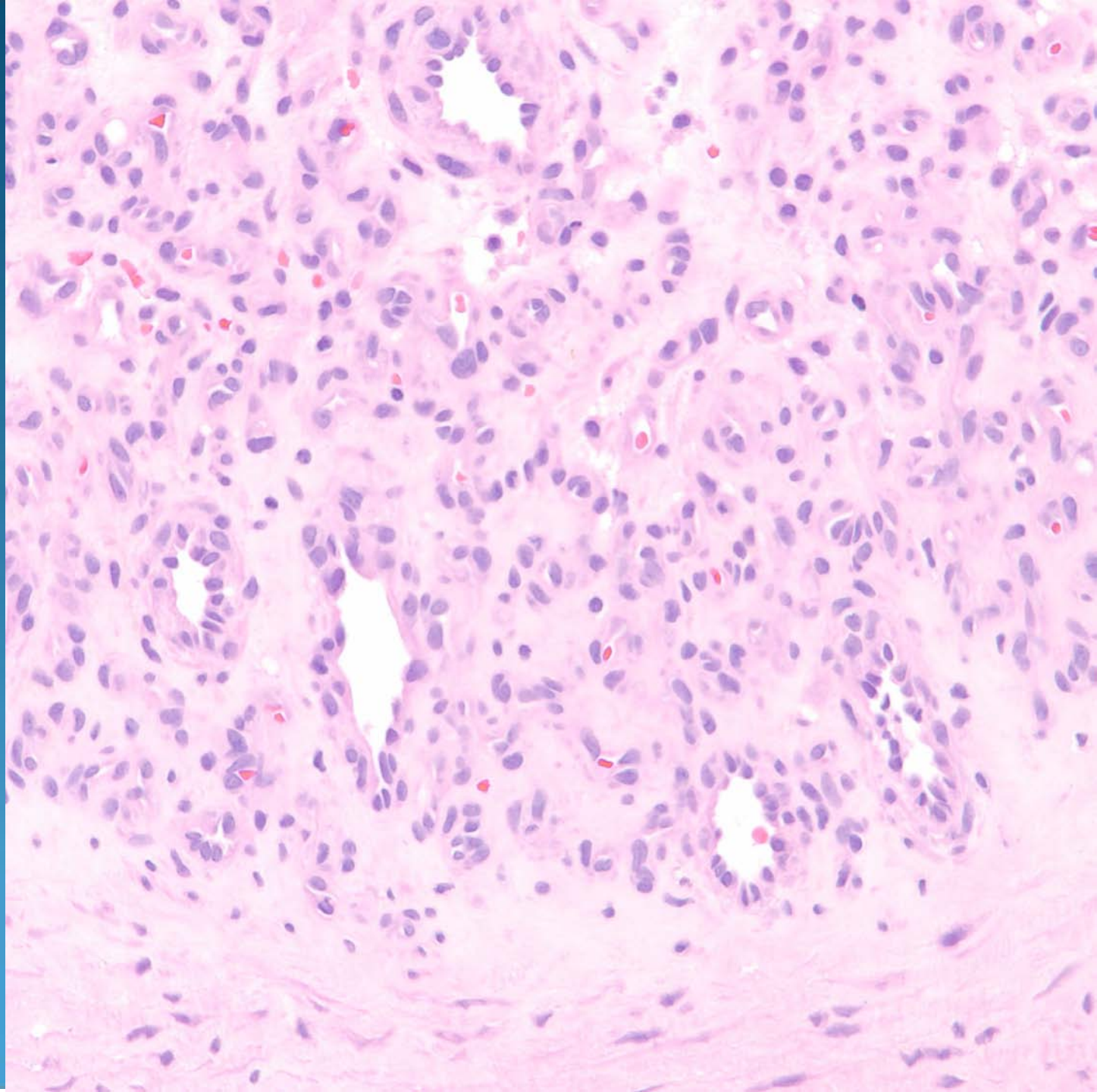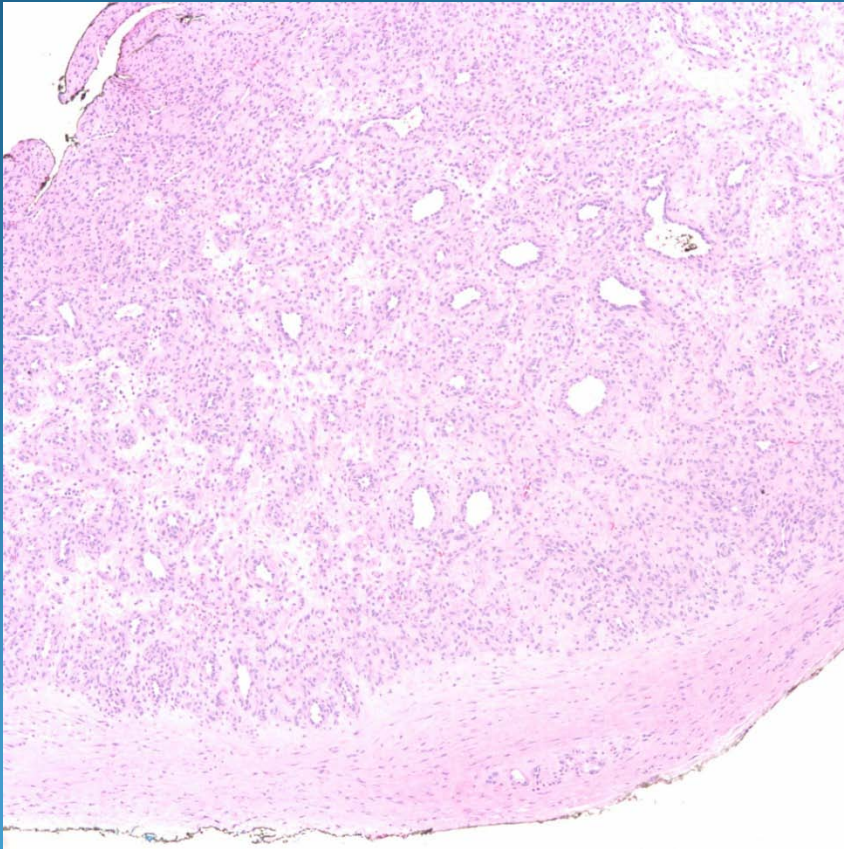


Intravascular Pyogenic Granuloma

Pearls



- Low Power Intravascular proliferation, look for thick vessel wall
- Interior of vessel with lobular proliferation of capillary sized vessels