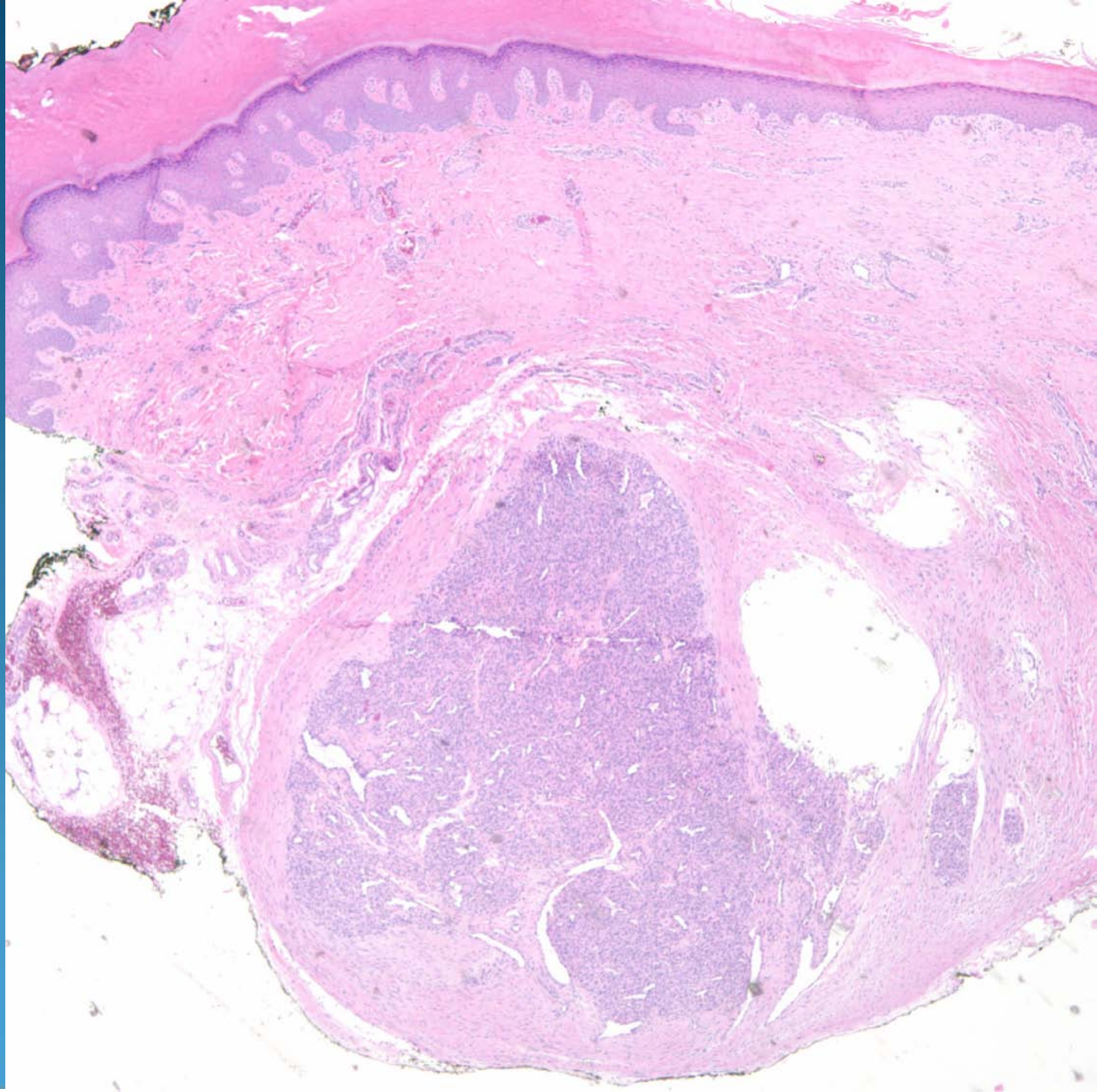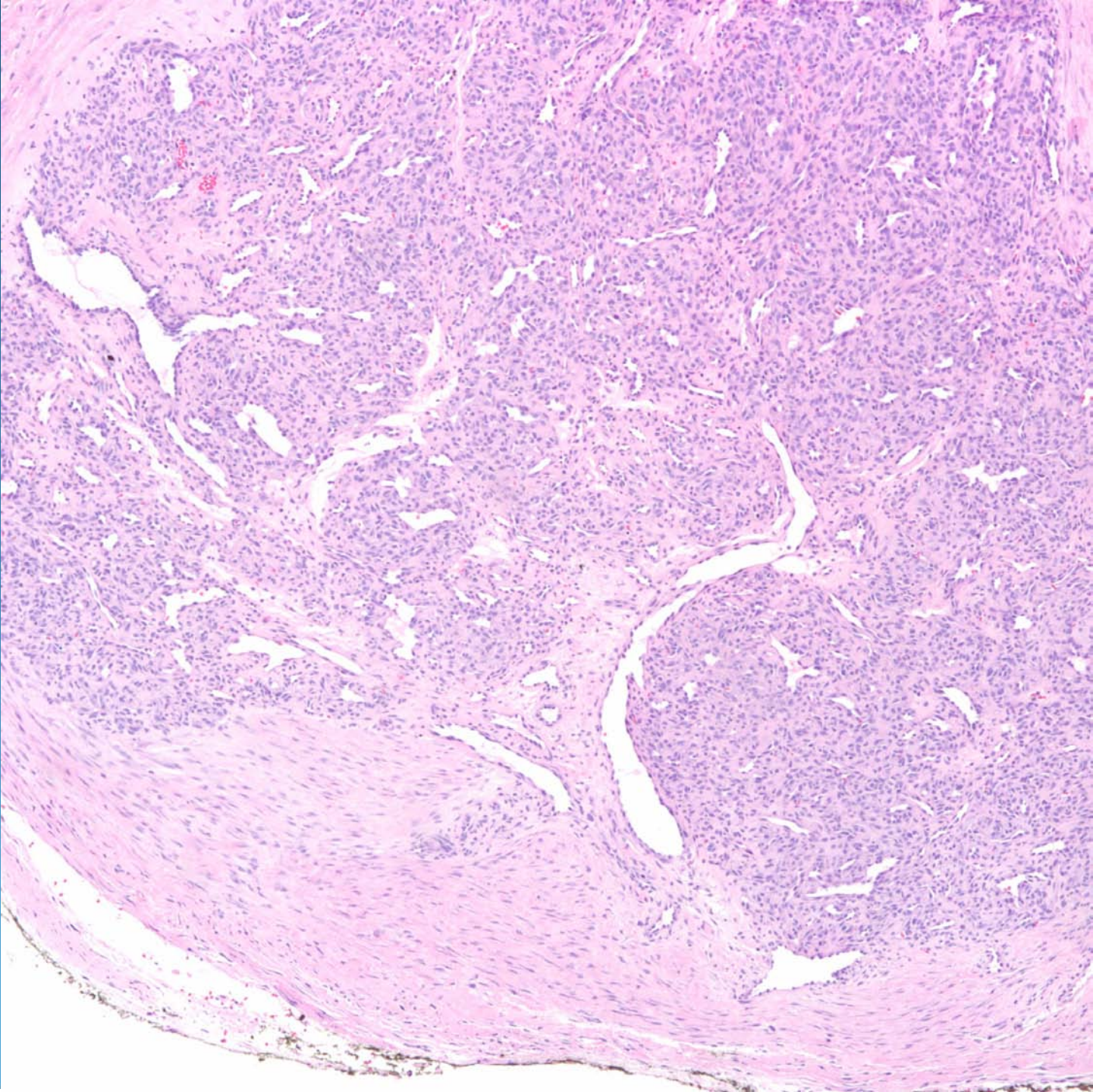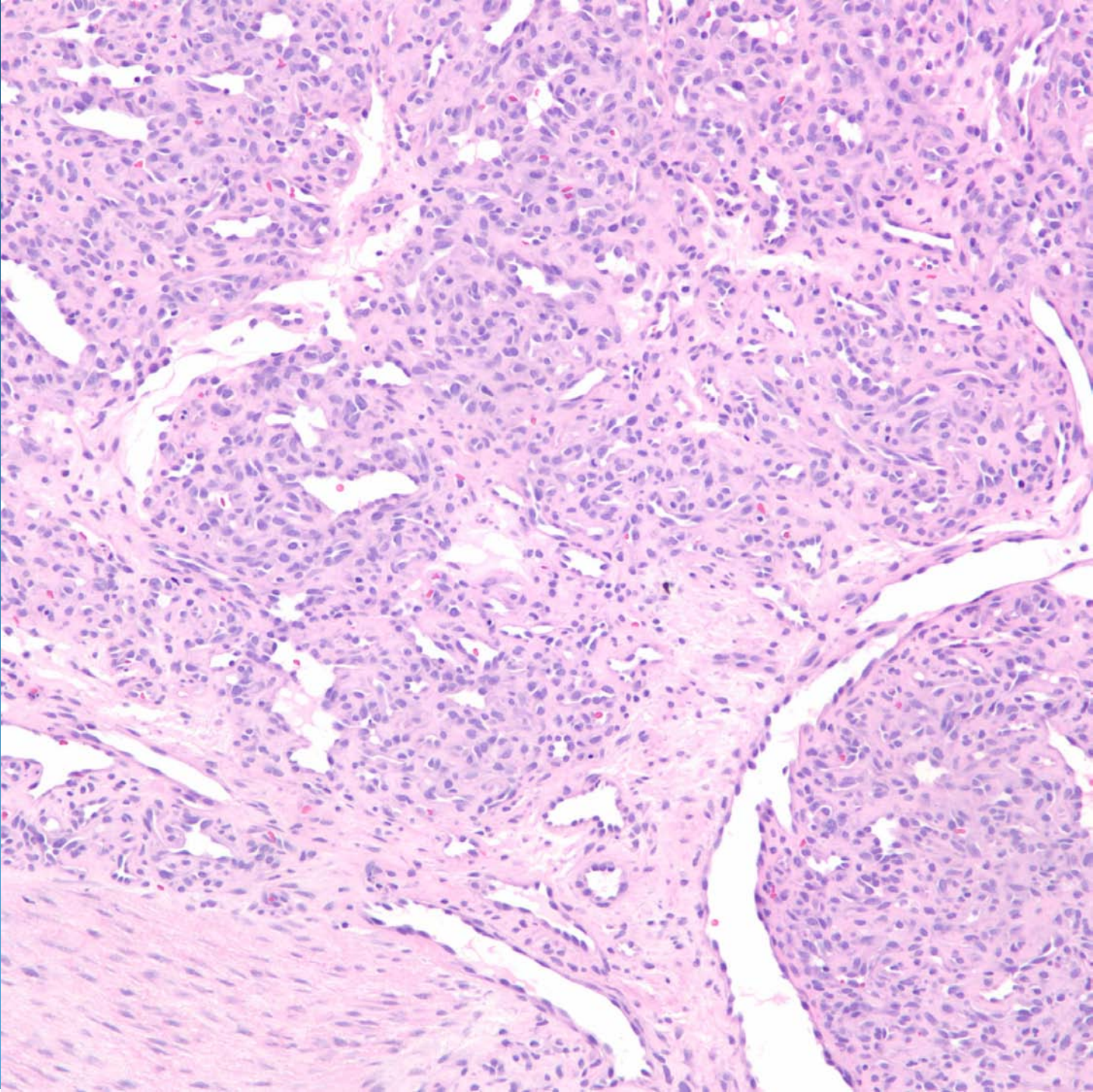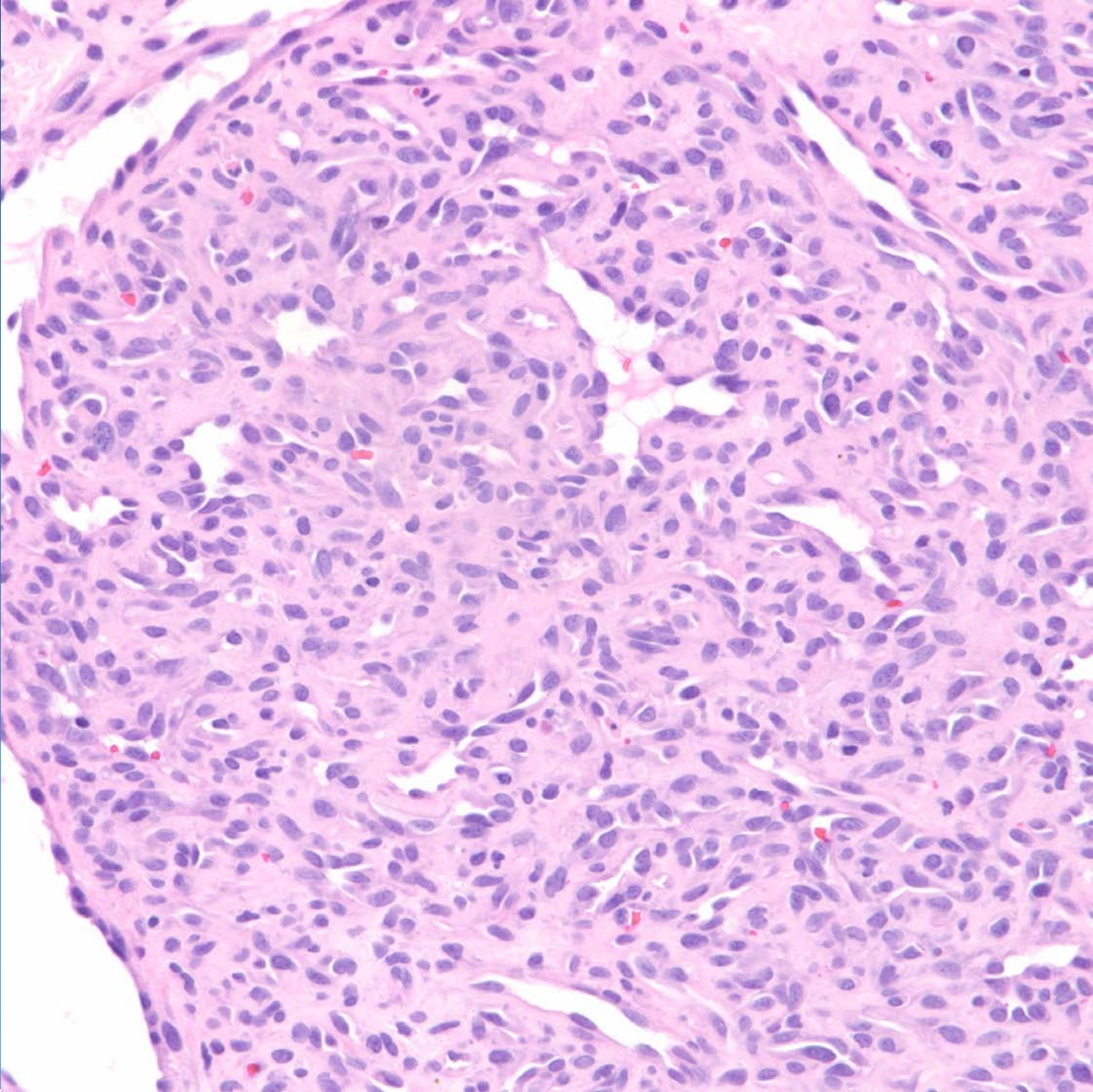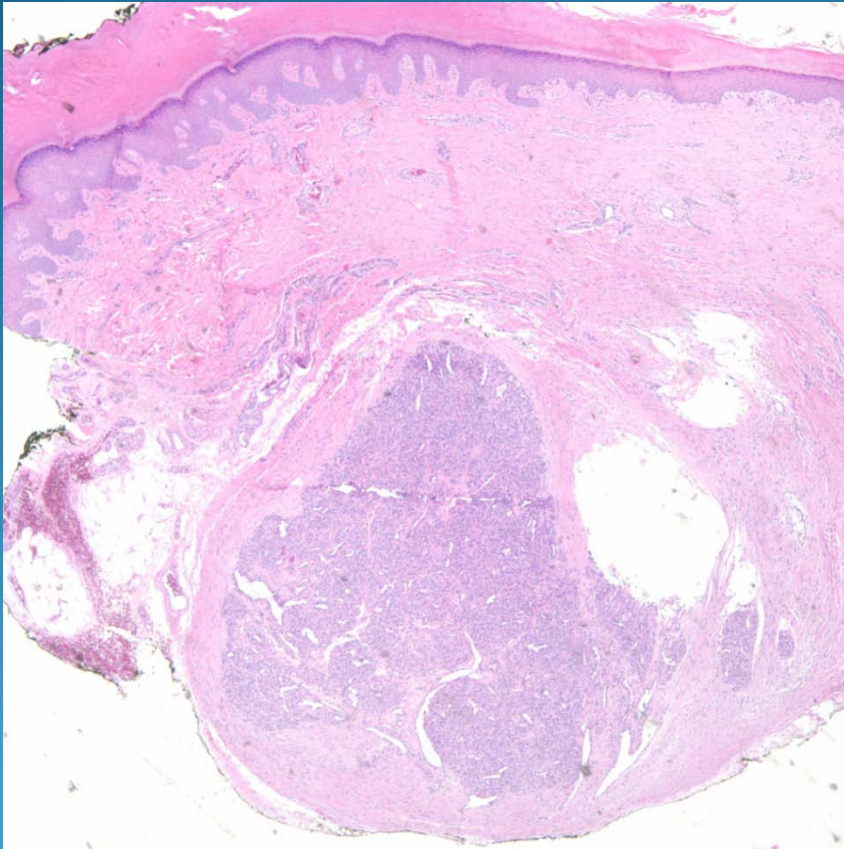


Intravascular Pyogenic Granuloma

Pearls



- Circumscribed intravascular proliferation of capillary-sized vessels arranged in lobular configuration
- Resembles an organizing thrombus but more lobular architecture