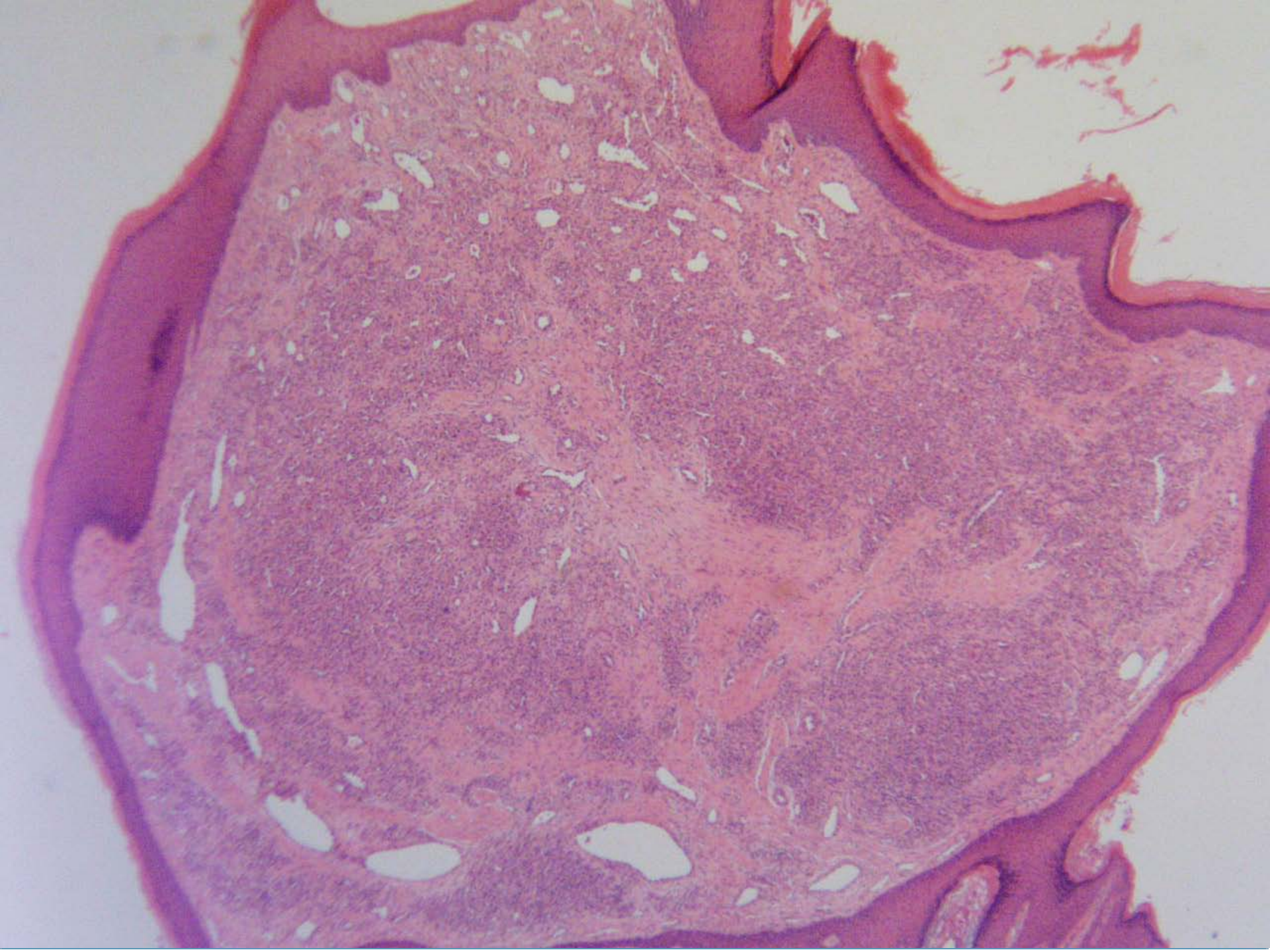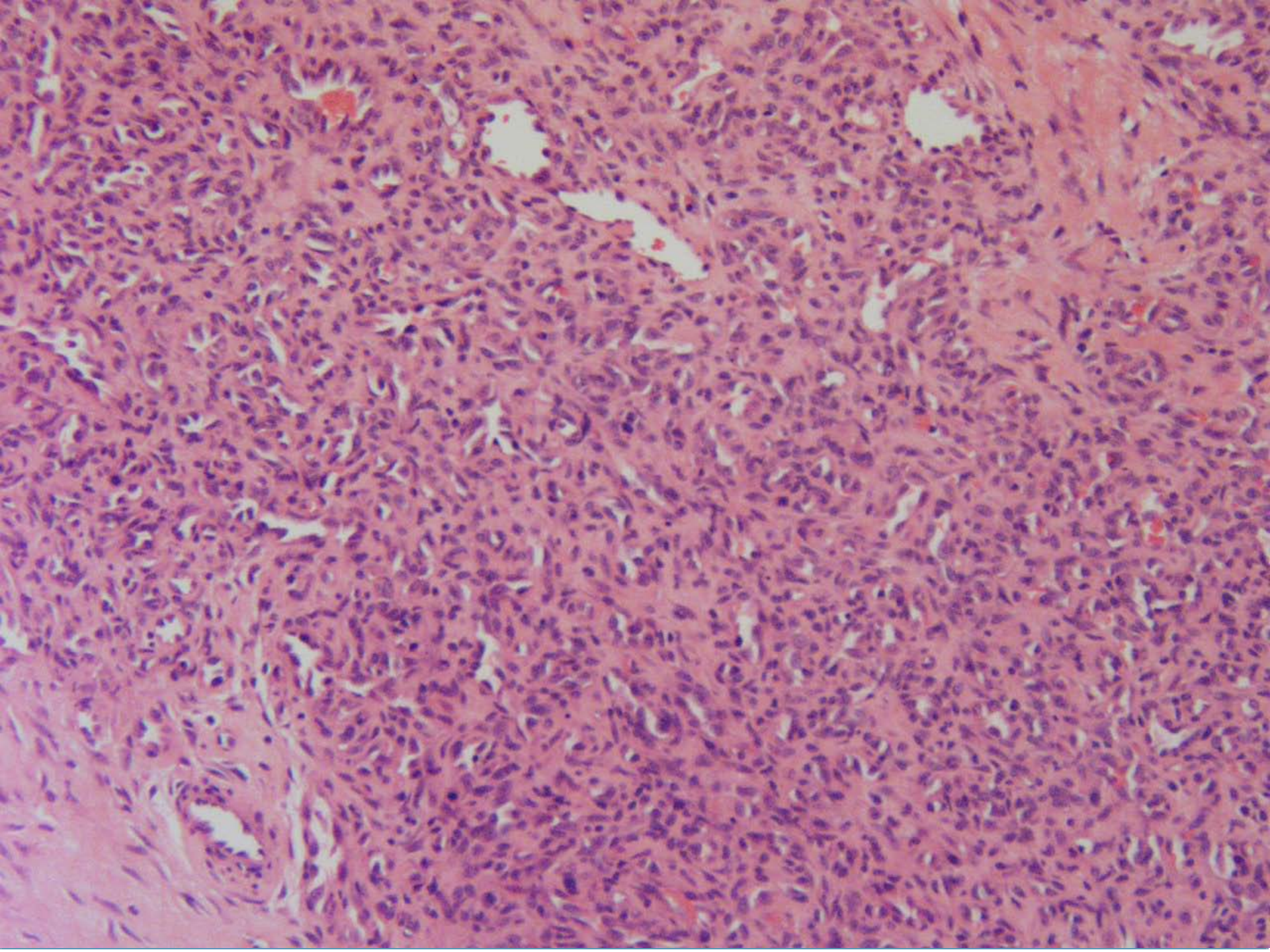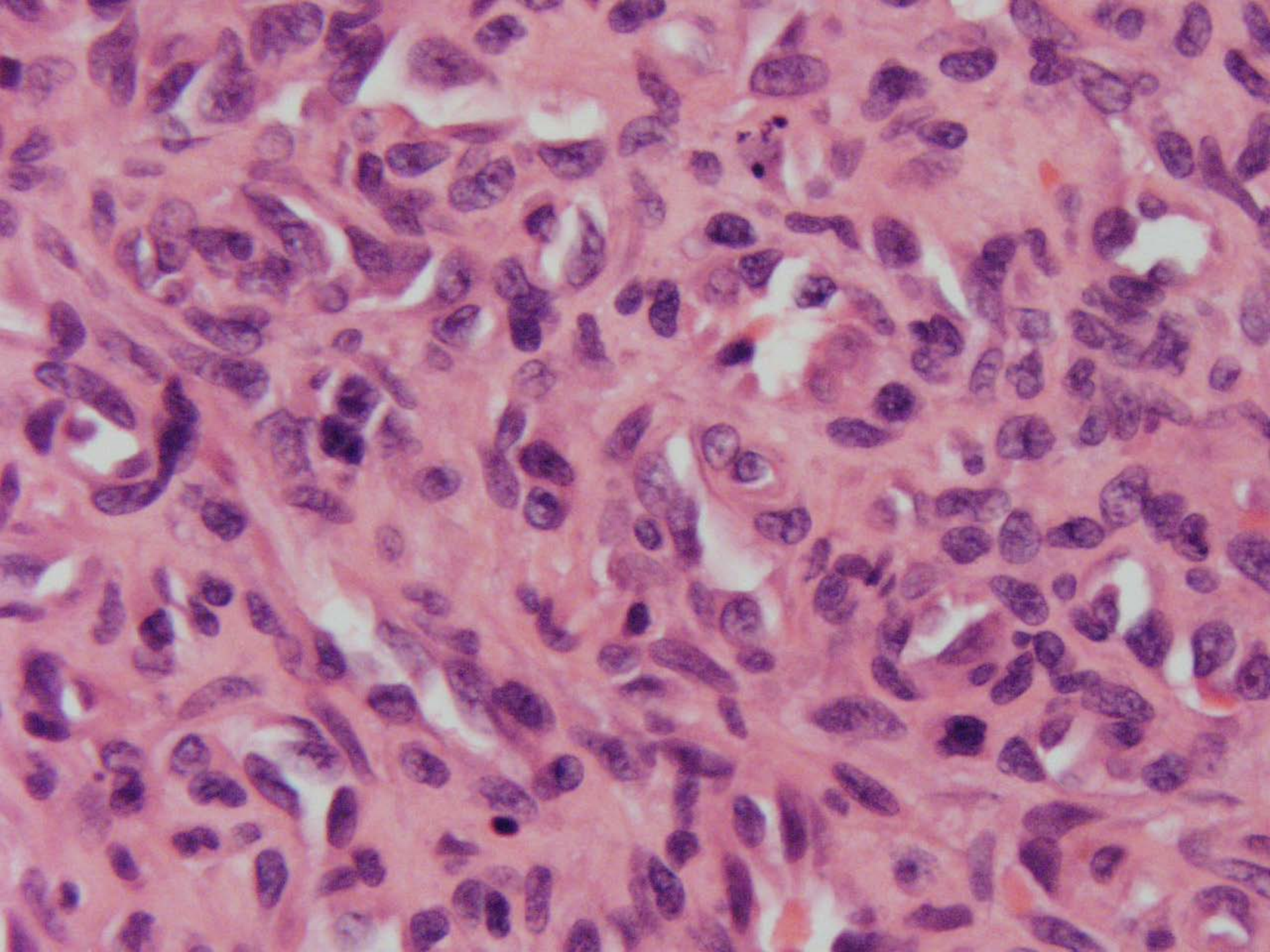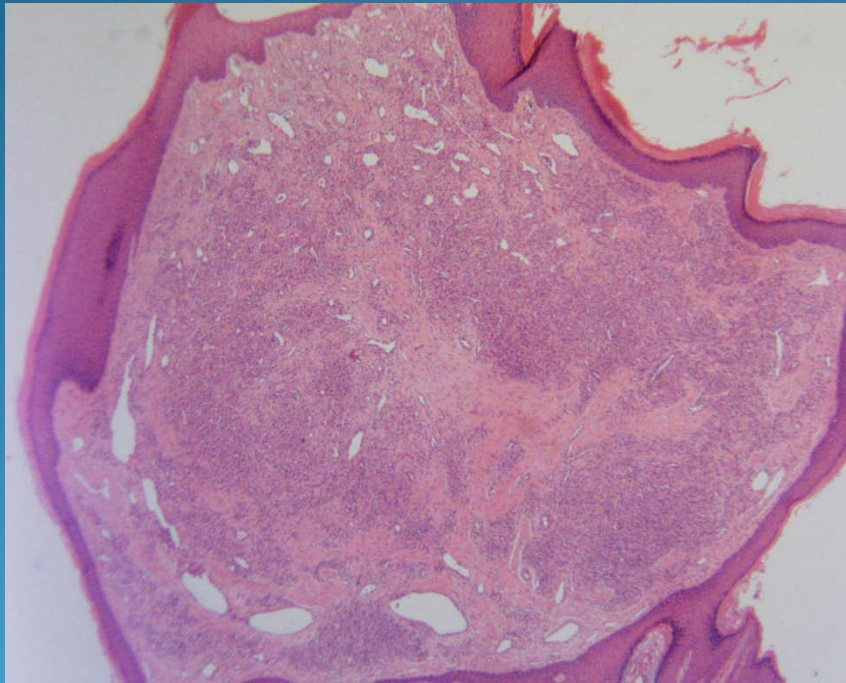


Pyogenic Granuloma- Lobular Capillary Hemangioma

Pearls



- Spindle cell proliferation with no rbc trapping
- Tufted collection of small round vessels
- Neutrophils if ulcerated
- Consider bacillary angiomatosis if increased neutrophils but no ulcer