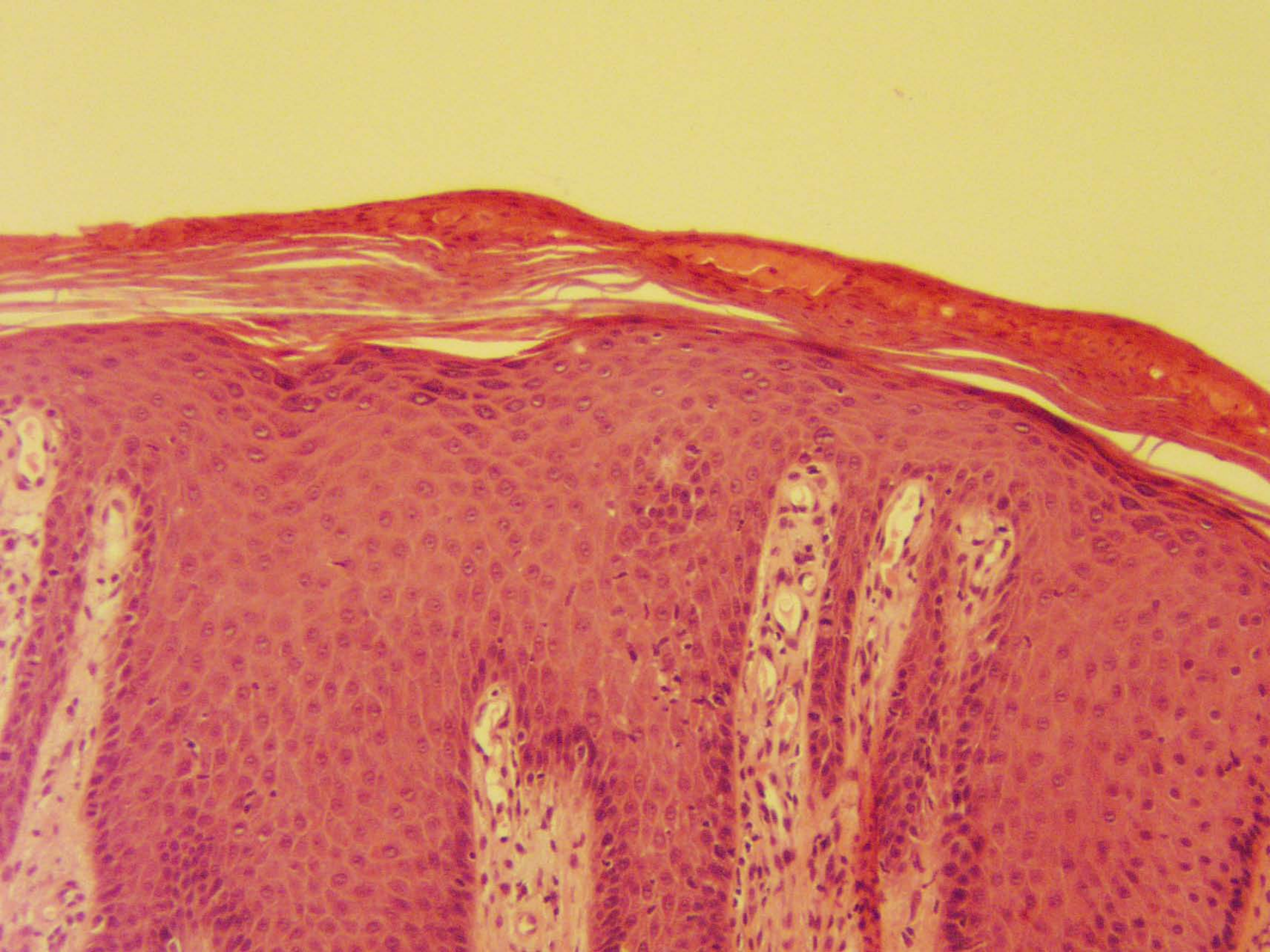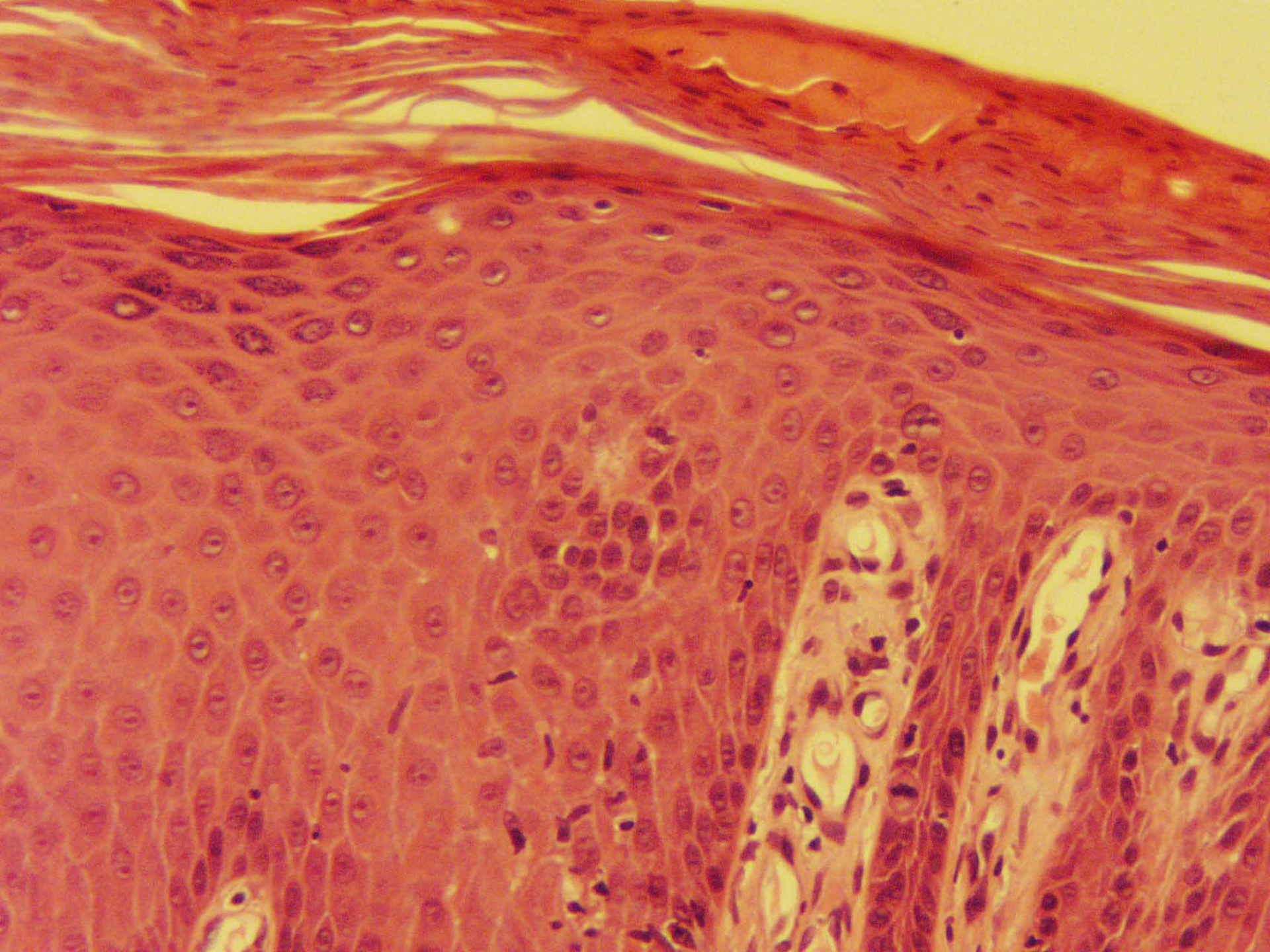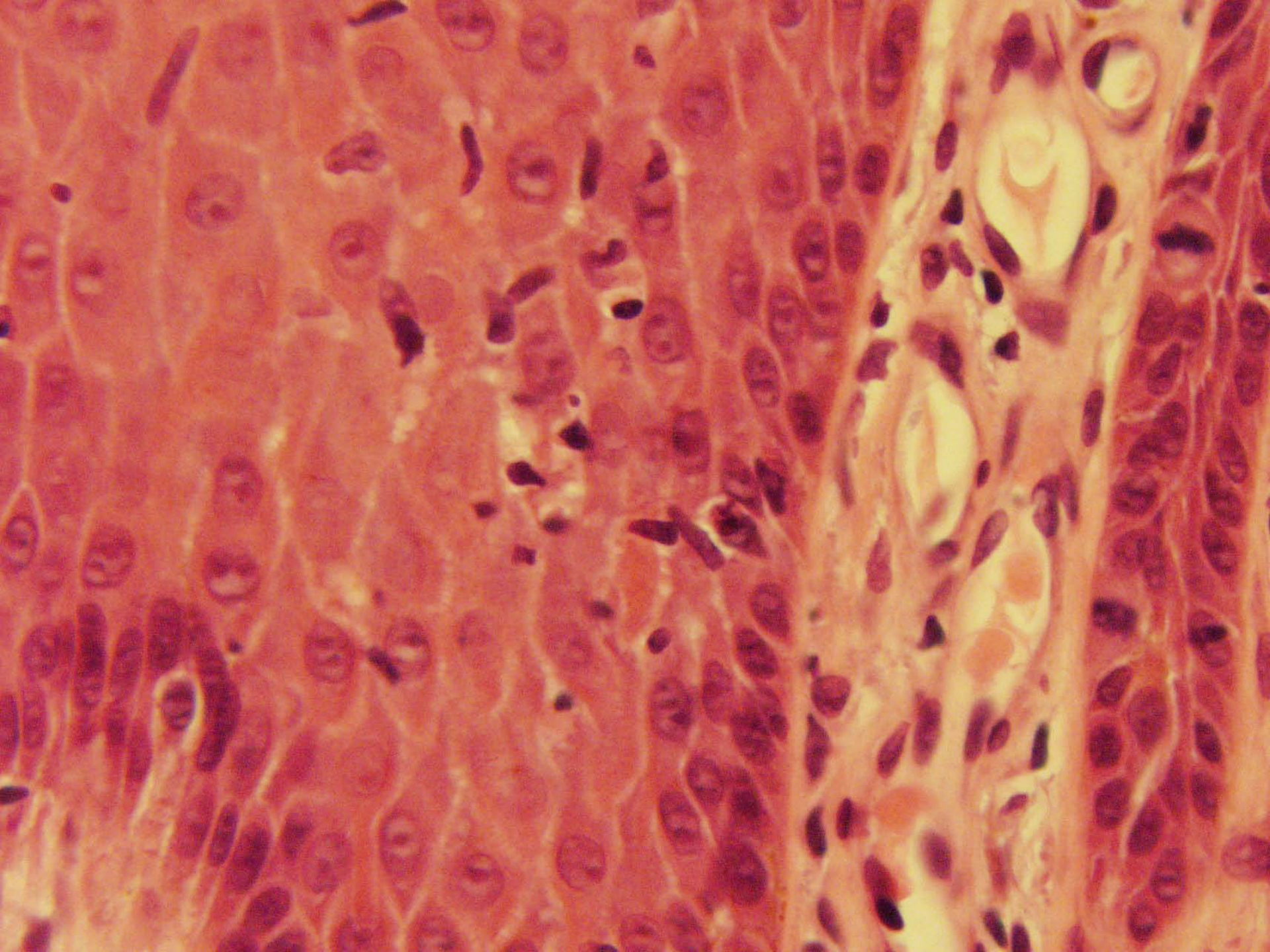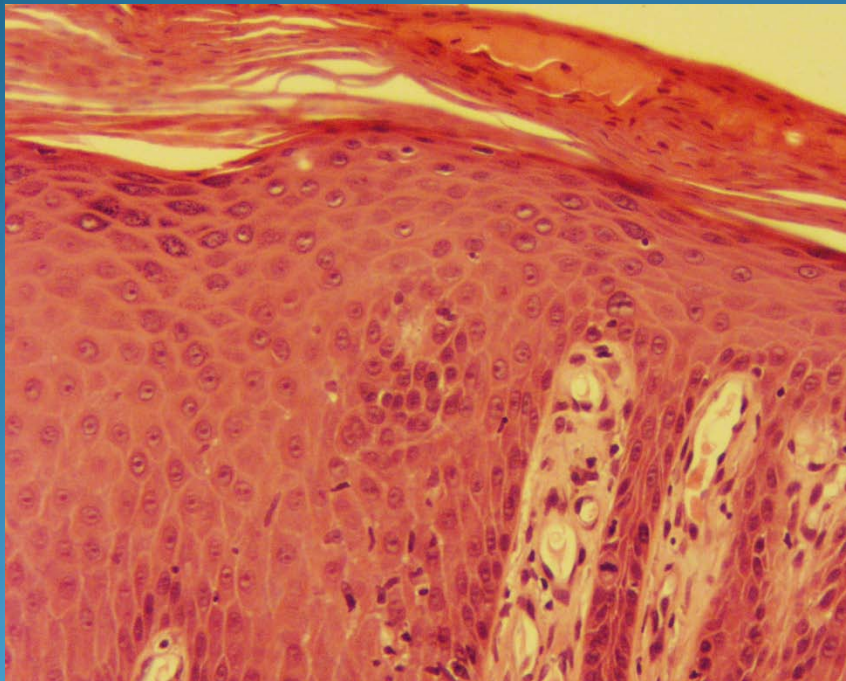


Psoriasis Vulgaris

Pearls



- Multilayered wafer scale with neutrophils in stratum corneum (Munro microabscess)
- Pallor of upper 1/3 of epidermis
- Spongiform pustule of Kogoj
- Hypogranulosis
- If plasma cells think syphilis