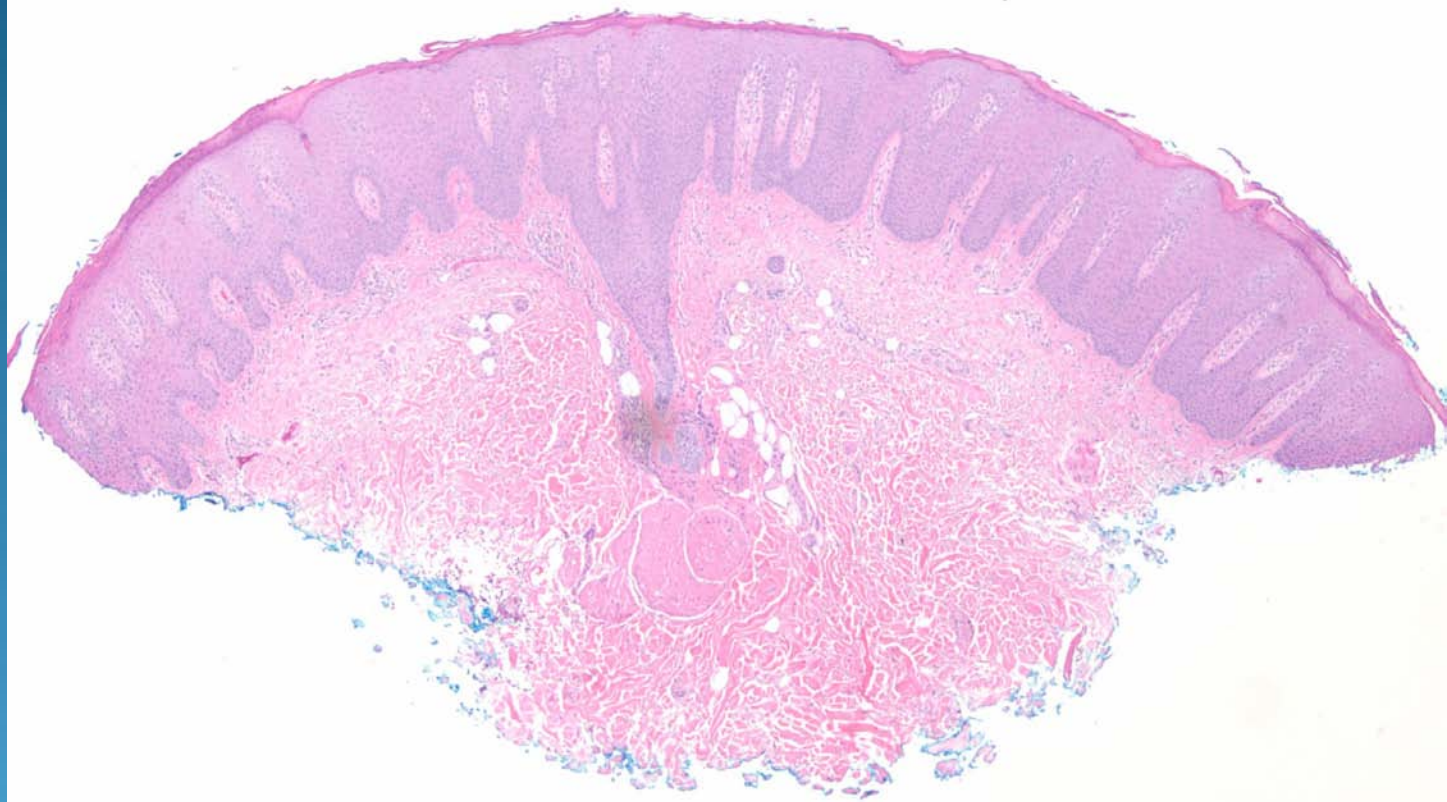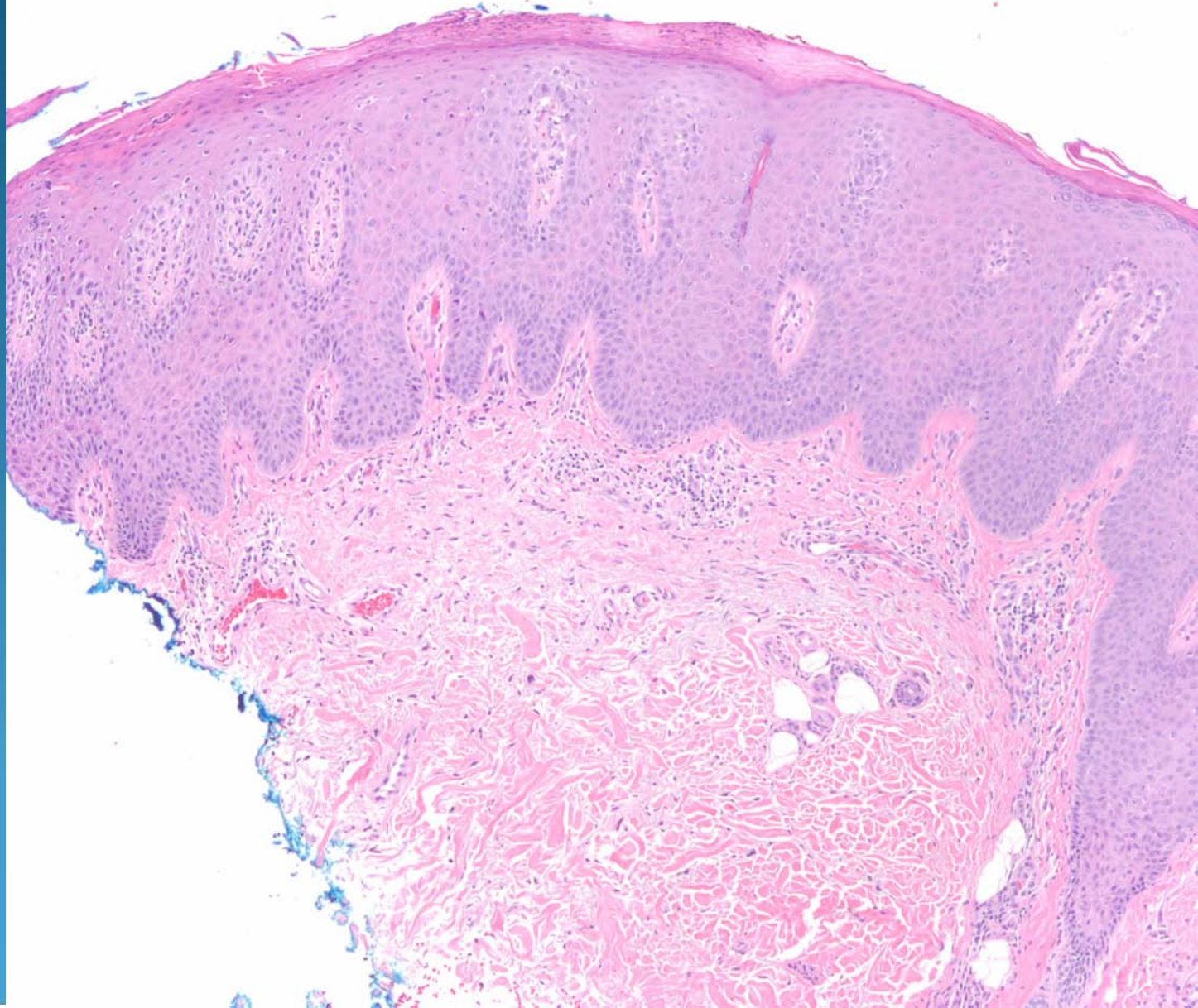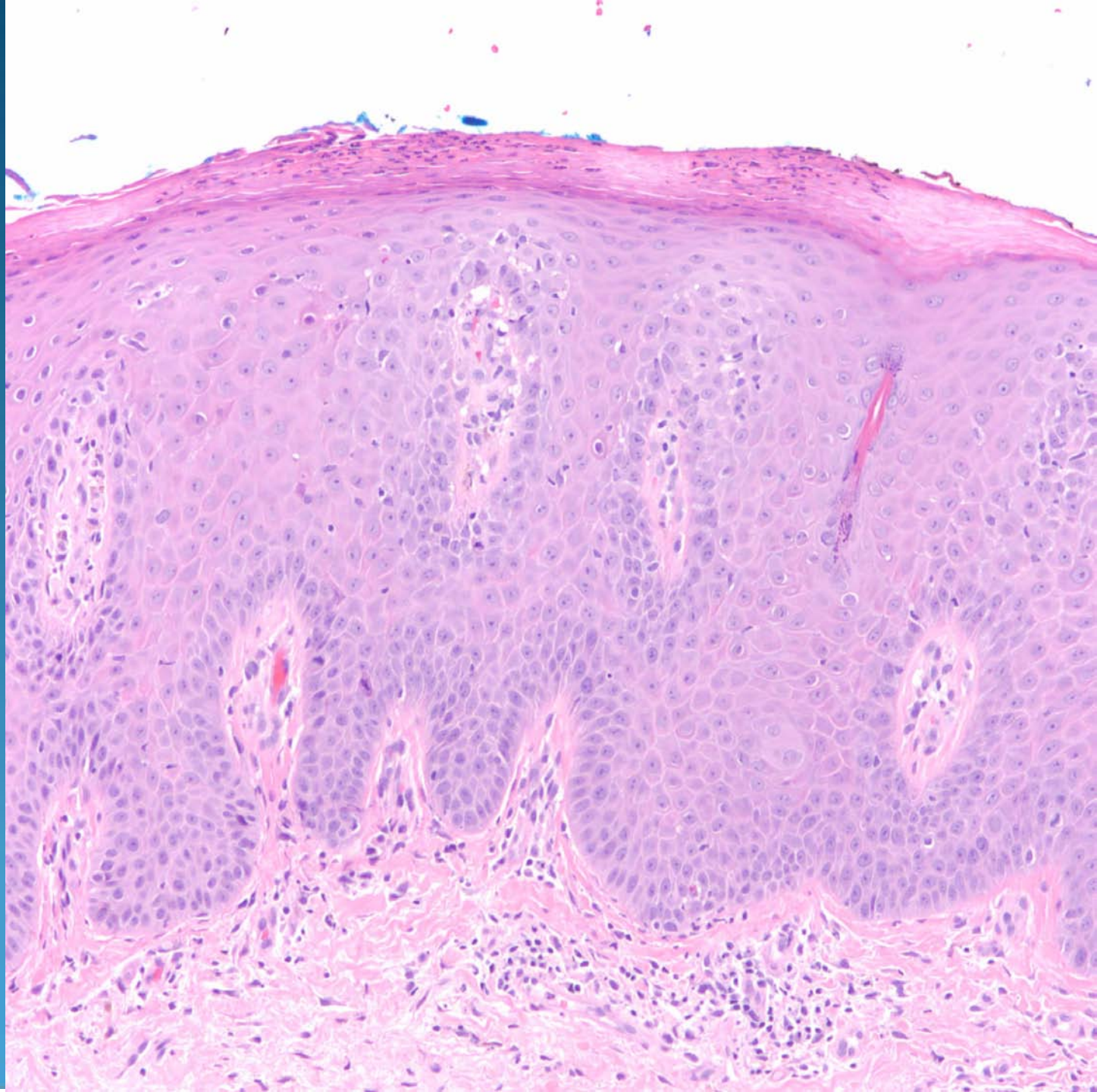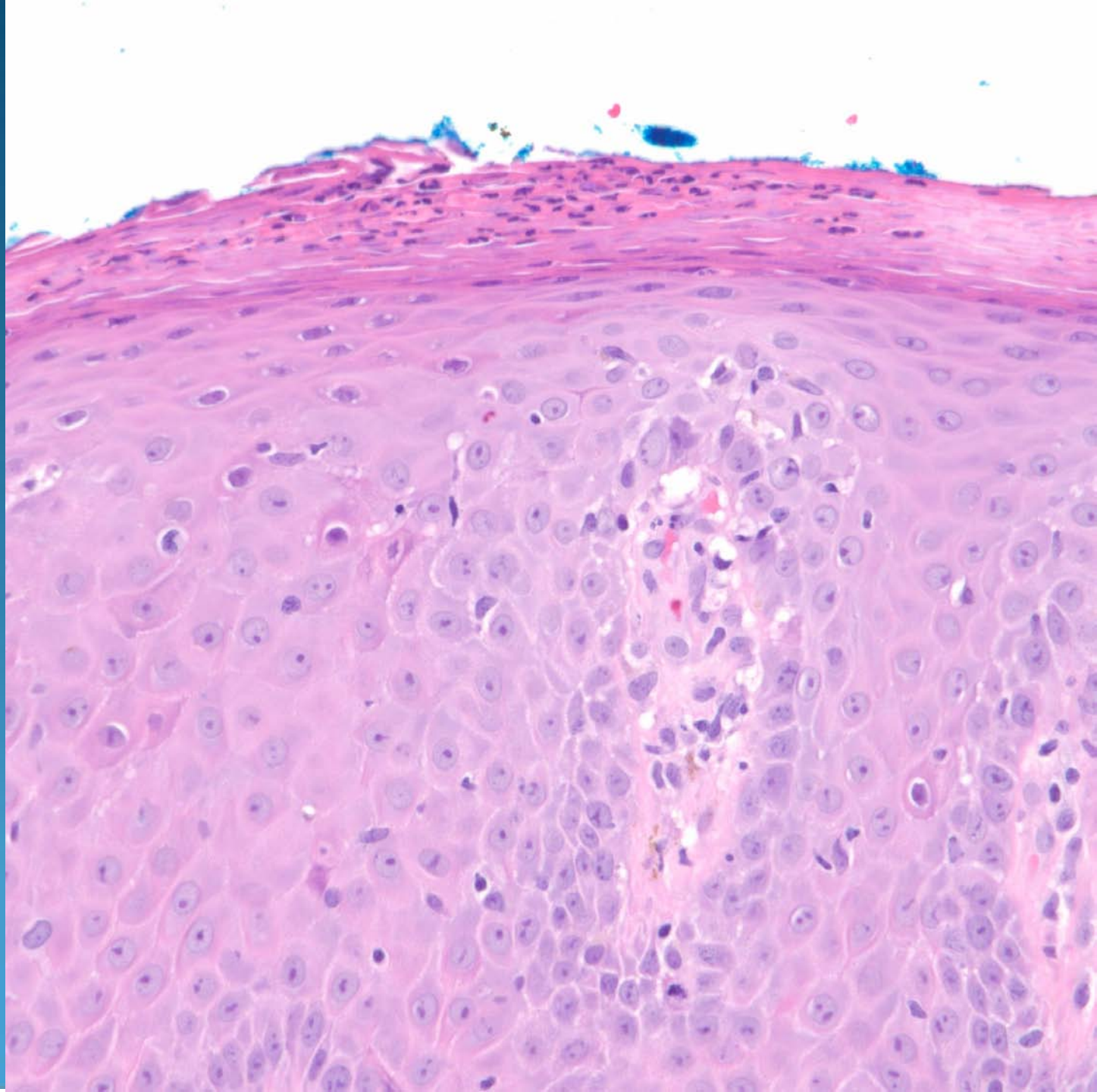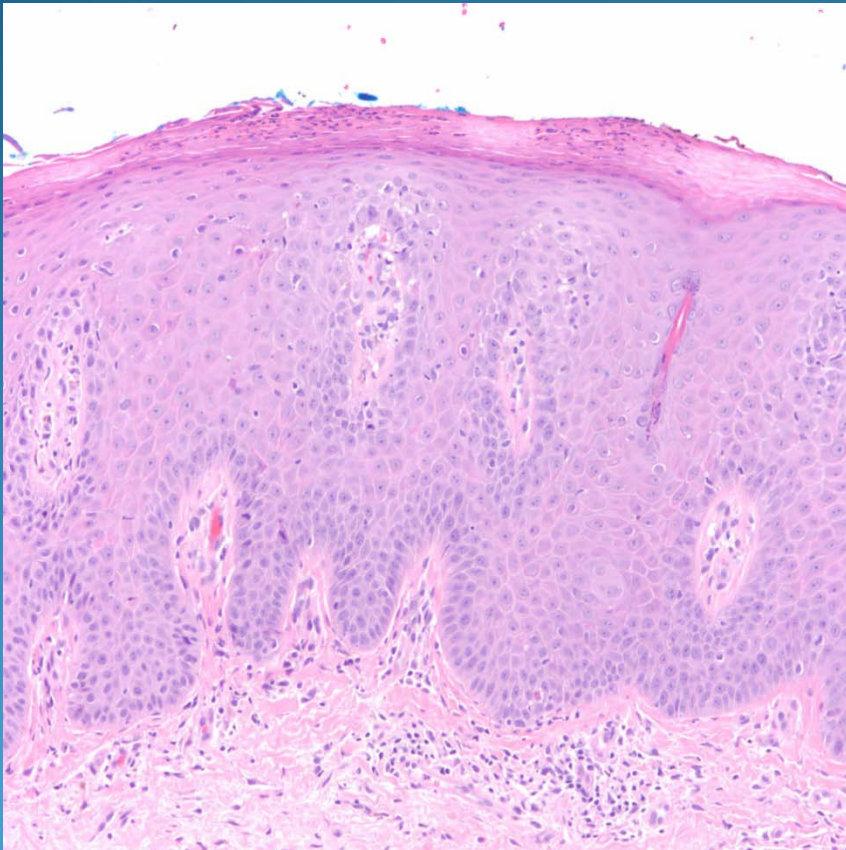


Psoriasis Vulgaris

Pearls



- Regular psoriasiform elongation of the rete ridges
- Hypogranulosis
- Intracorneal and intraepidermal collections of neutrophils
- Capillary tortuosity within papillary dermis
- Pallor of epidermal keratinocytes