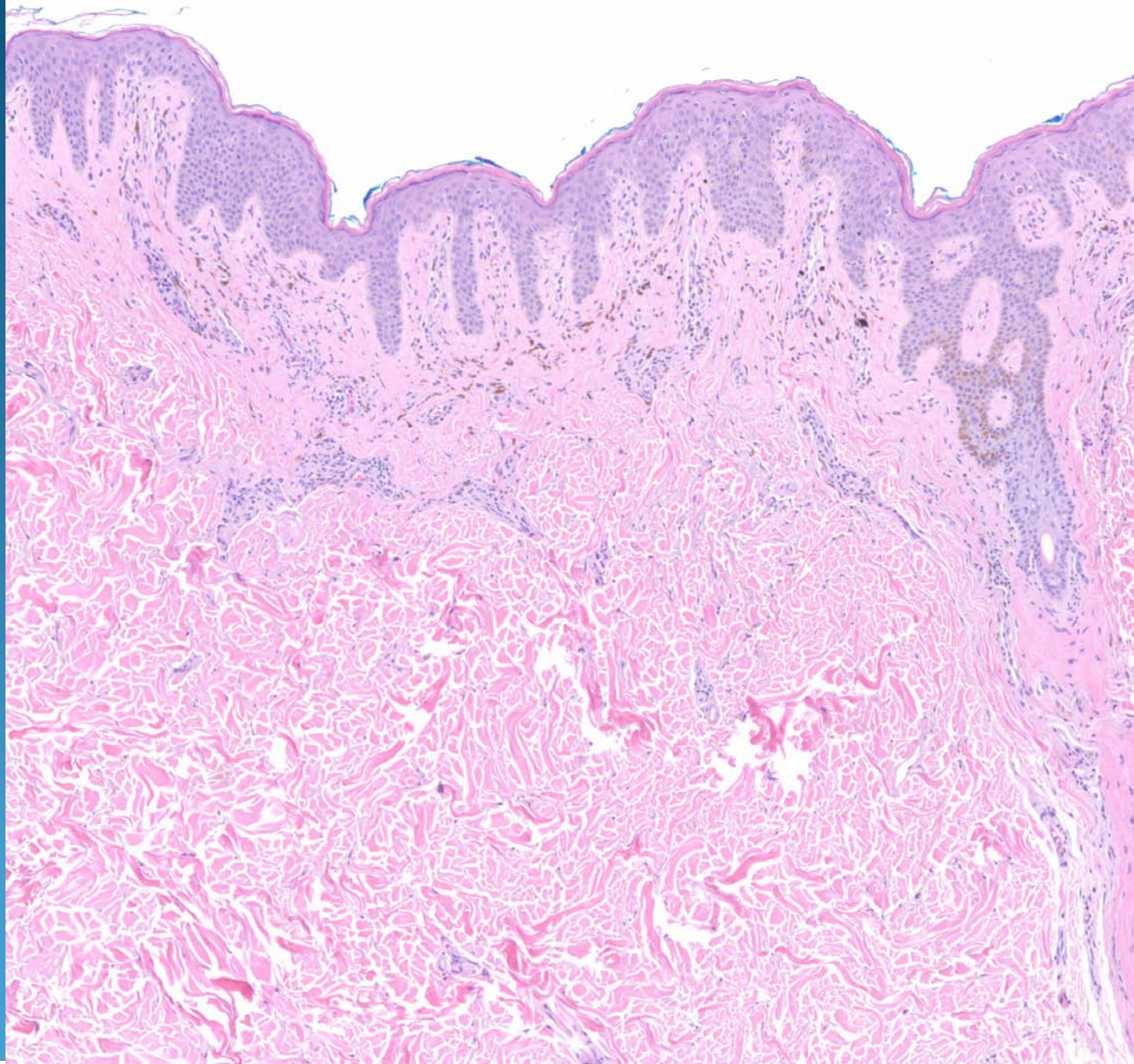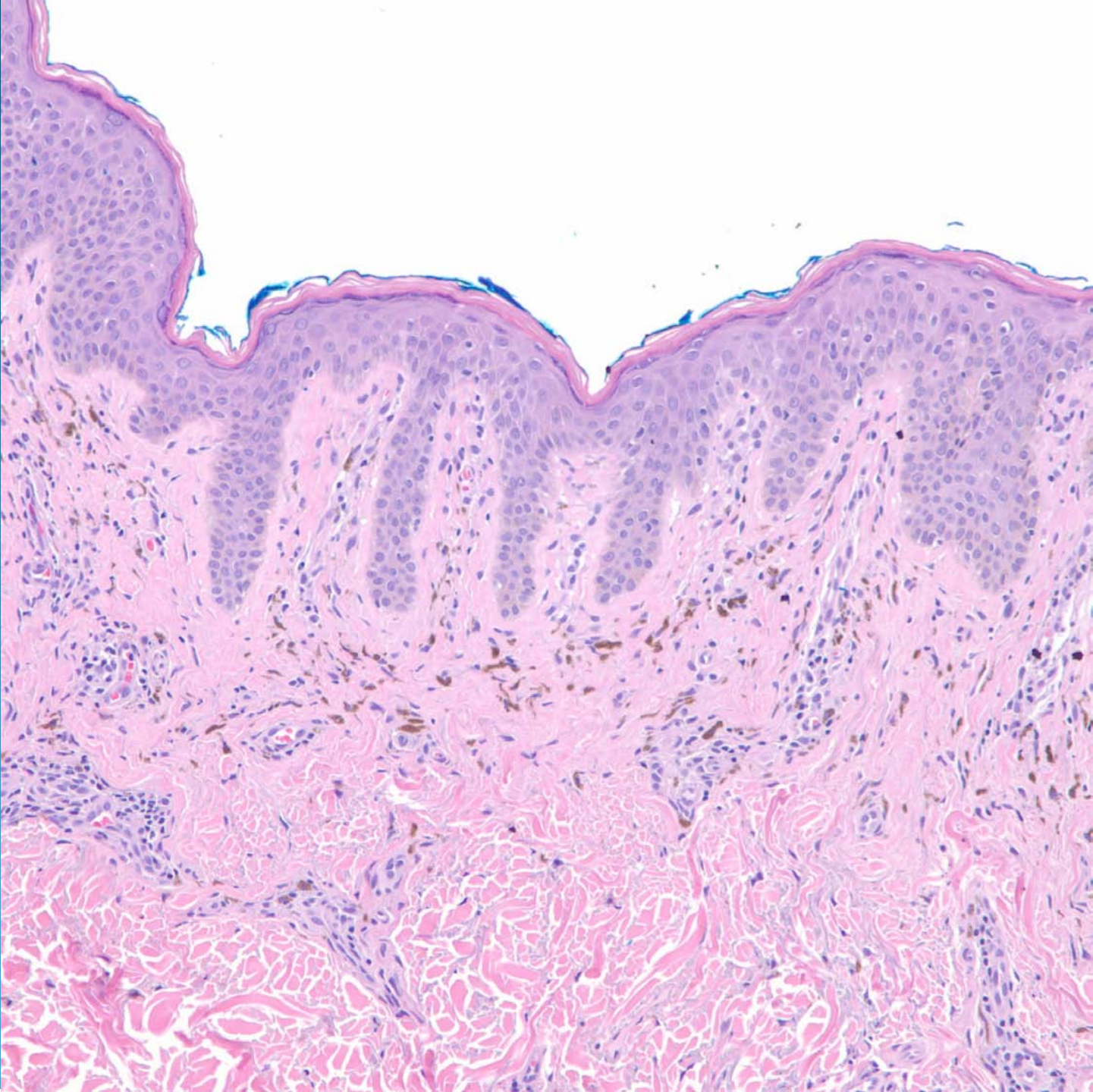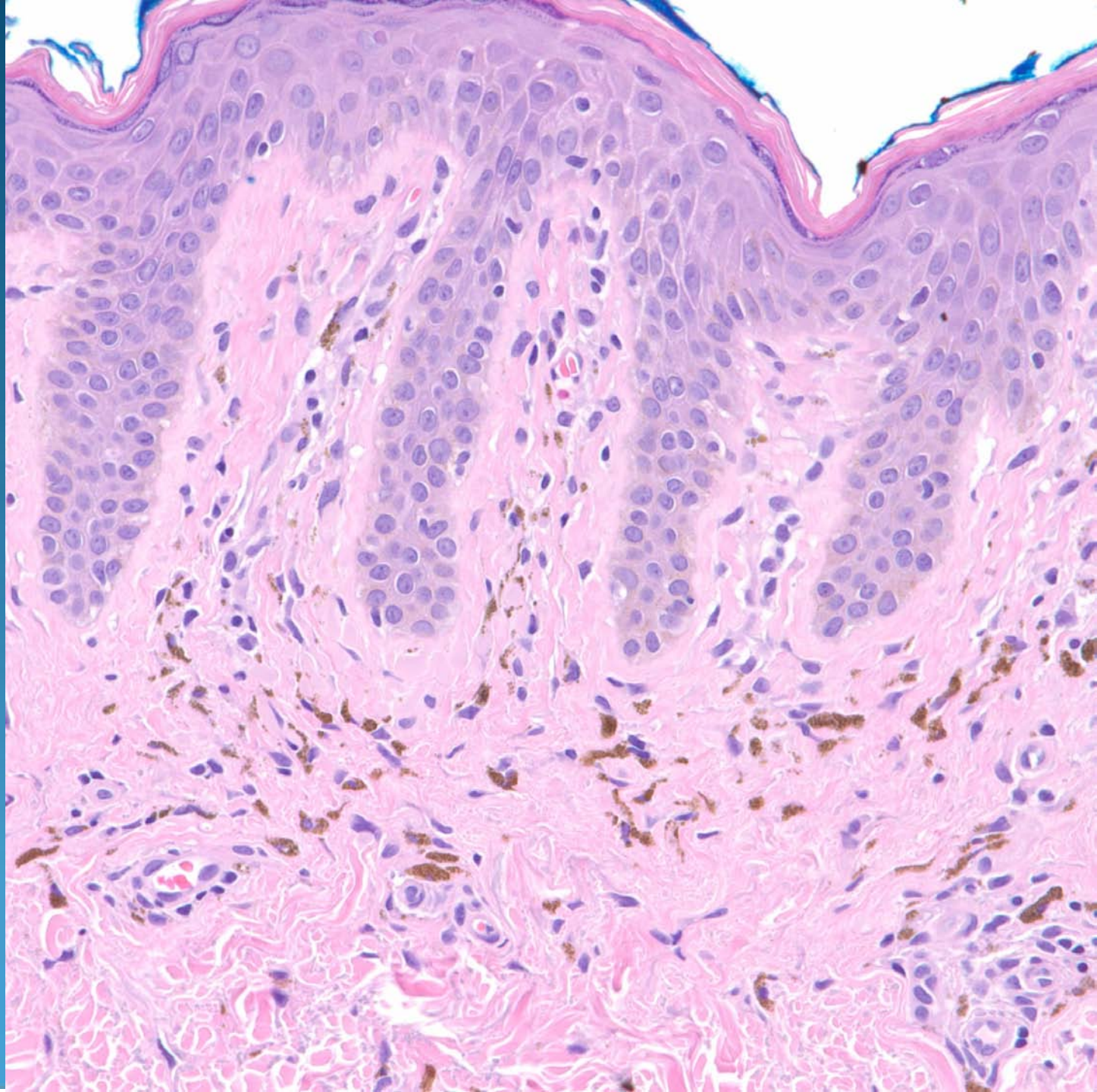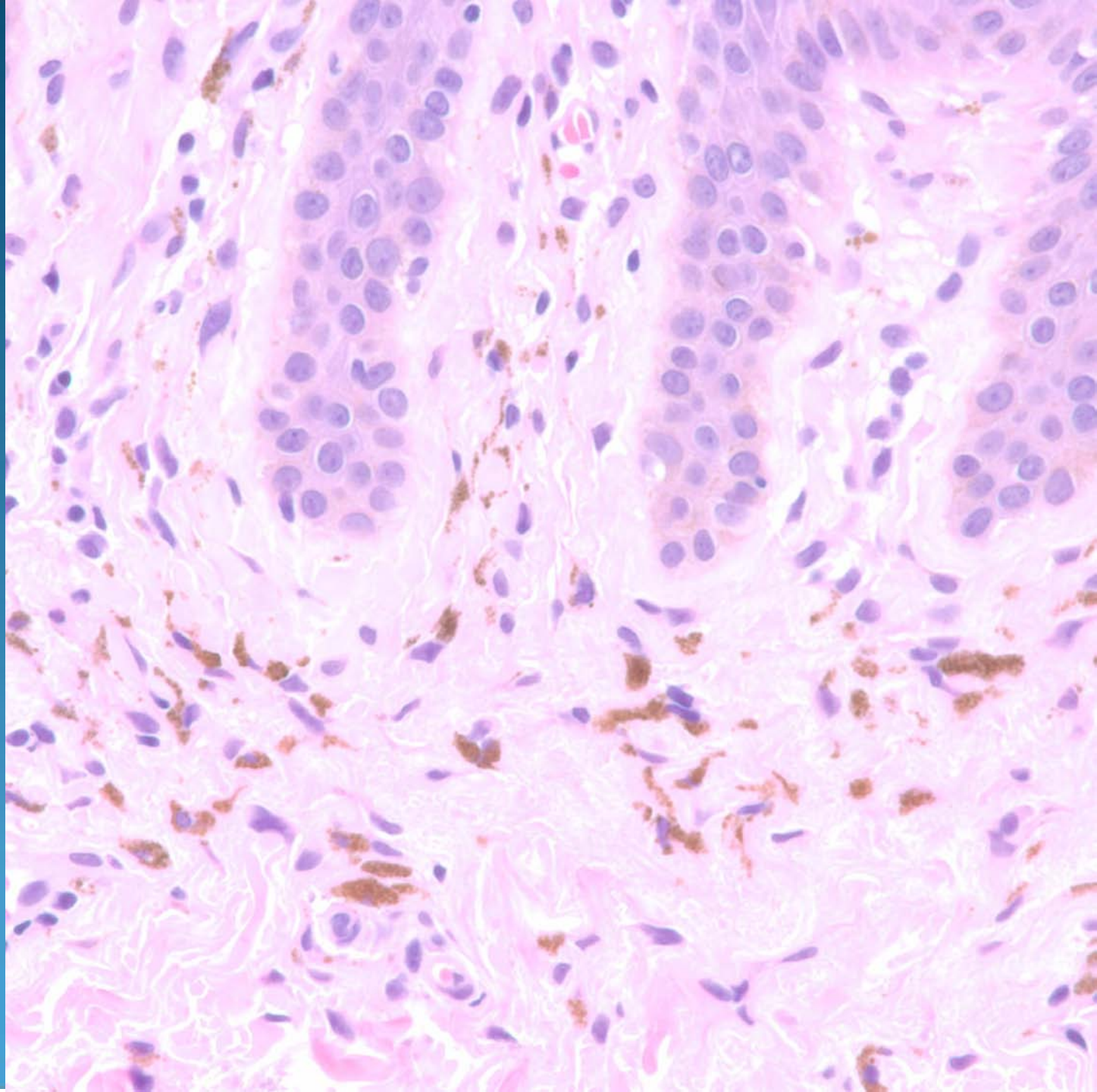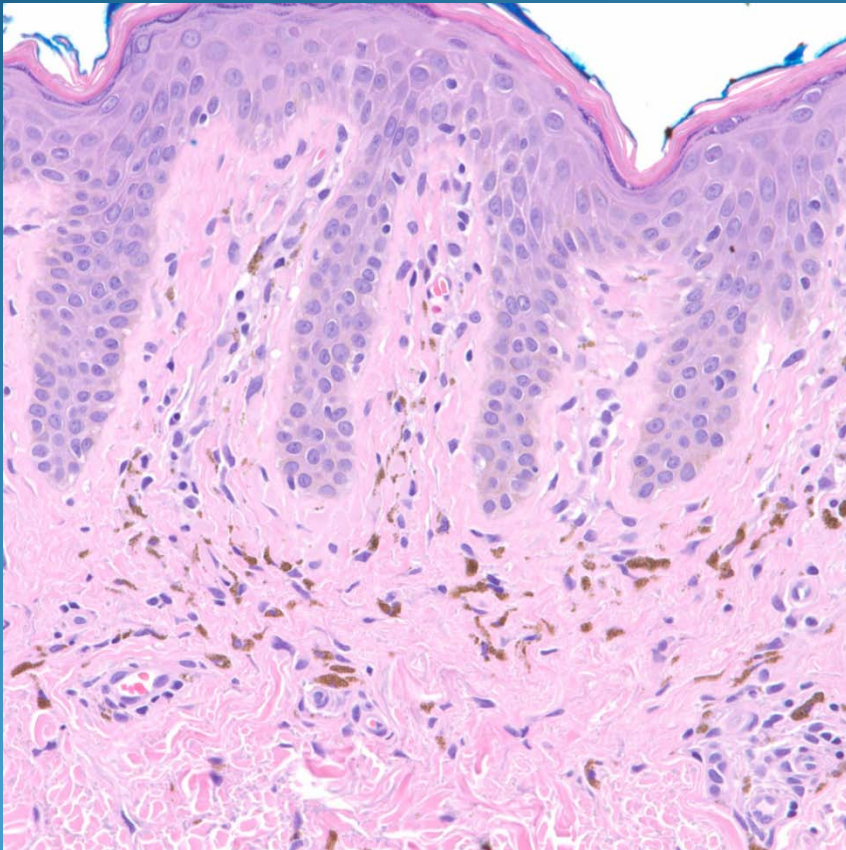


Post-Inflammatory Pigmentary Alteration (Ashy Dermatitis)

Pearls



- Superficial Perivascular dermatitis with melanophages
- Rule out macular amyloidosis
- Clinical-pathological correlation