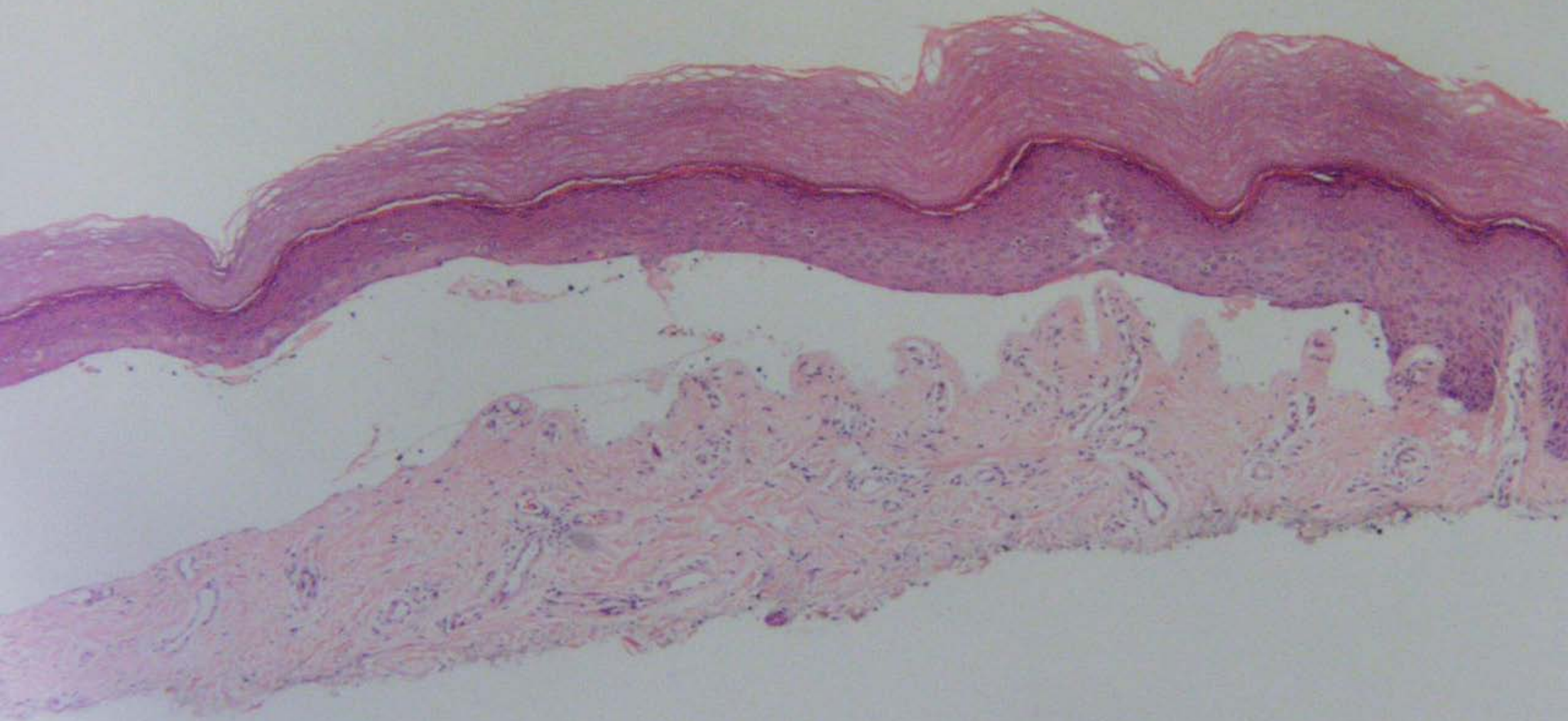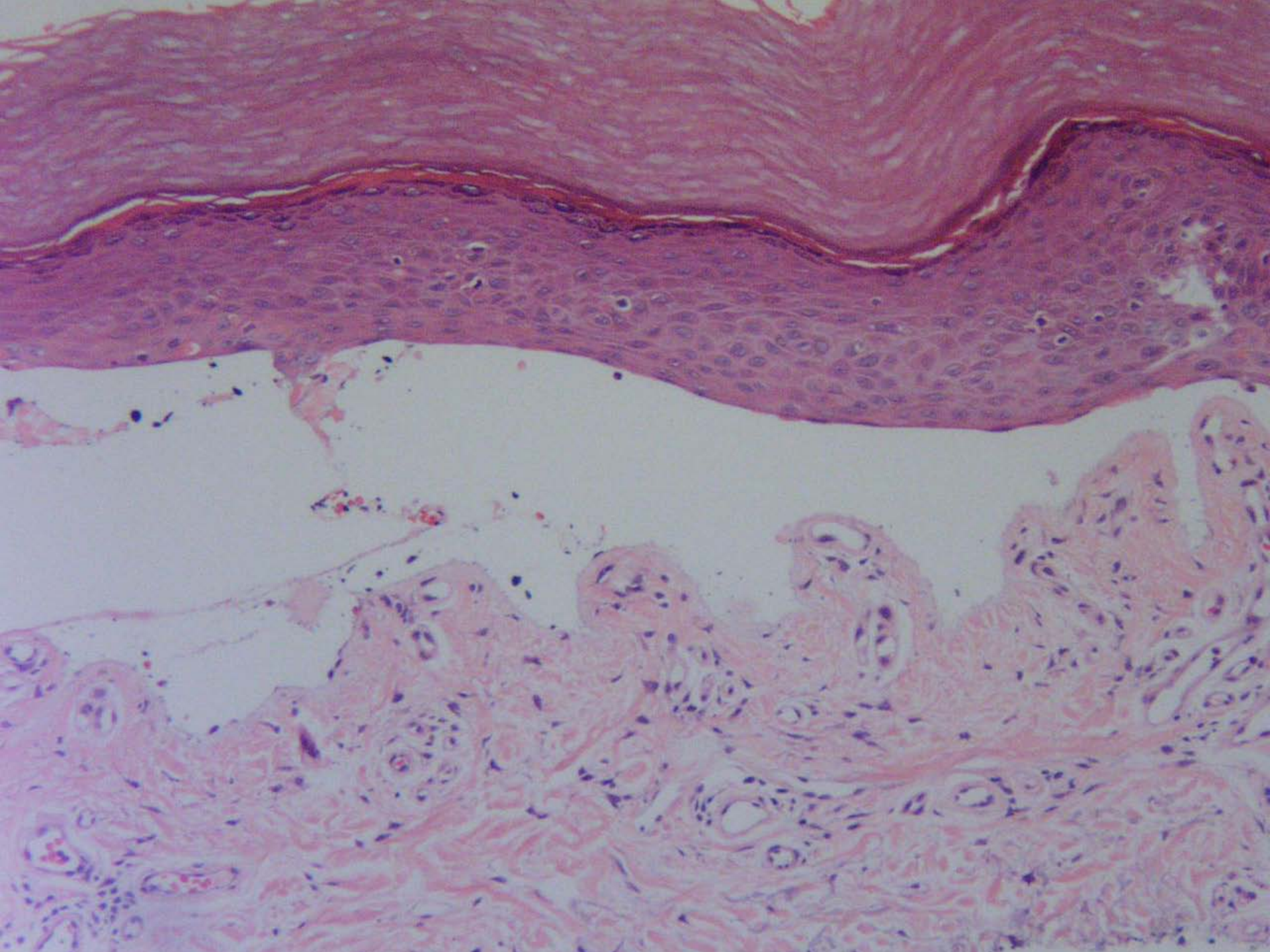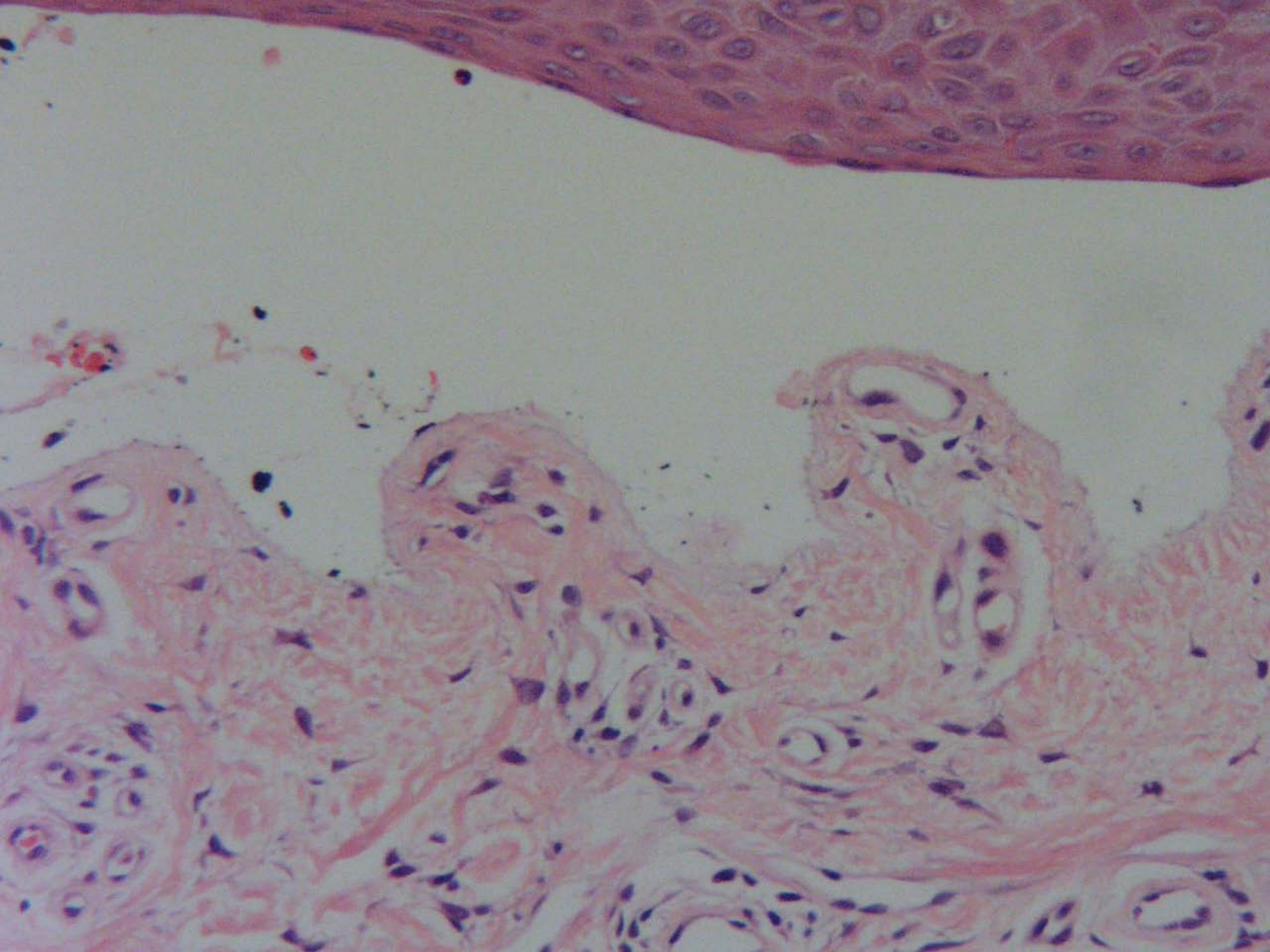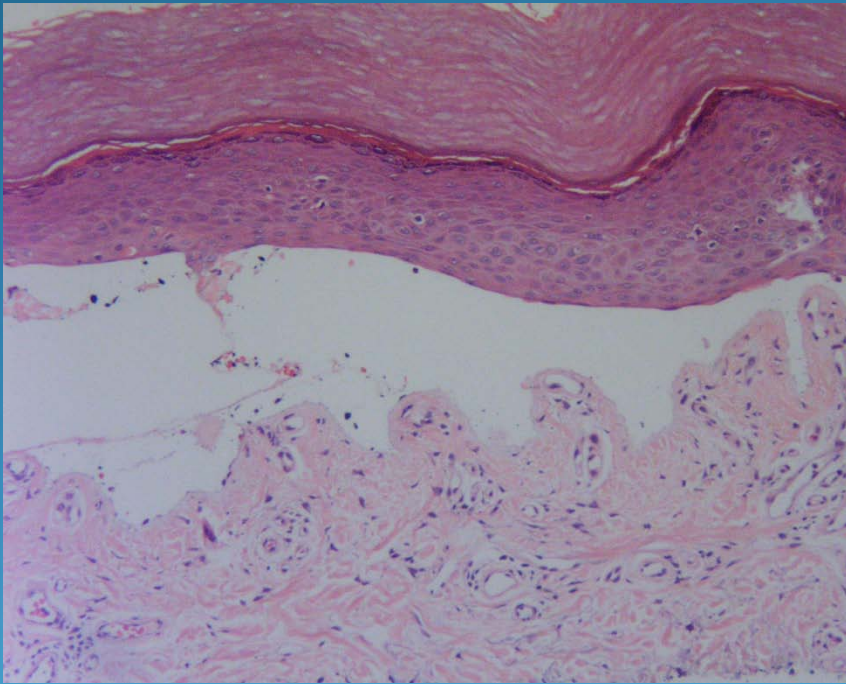


Porphyria Cutanea Tarda

Pearls



- Subepidermal non-inflammatory bullae
- Lymphs only, no neutrophils or eosinophils
- May have festooning
- Rarely pink hyalinized material around vessels