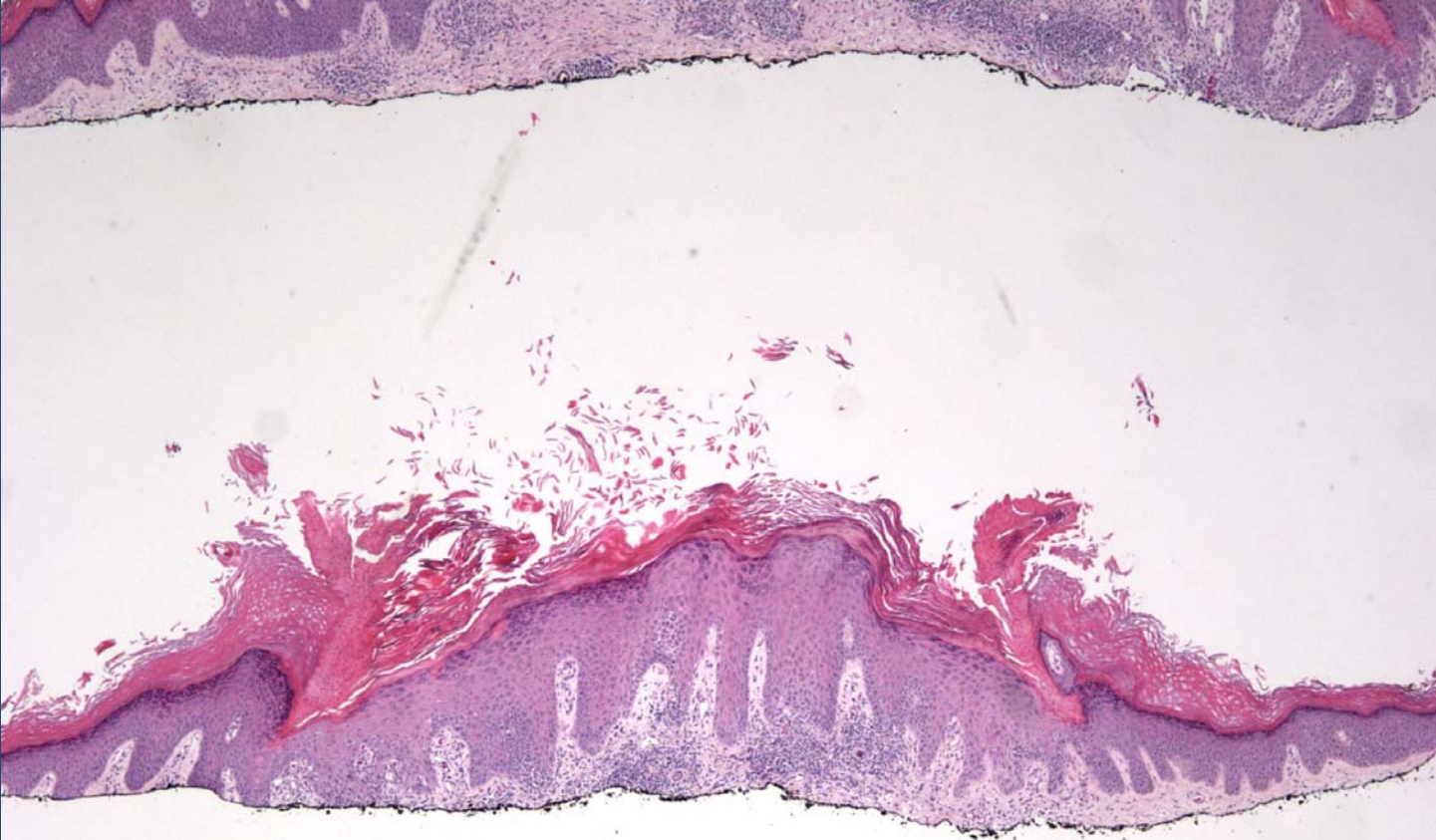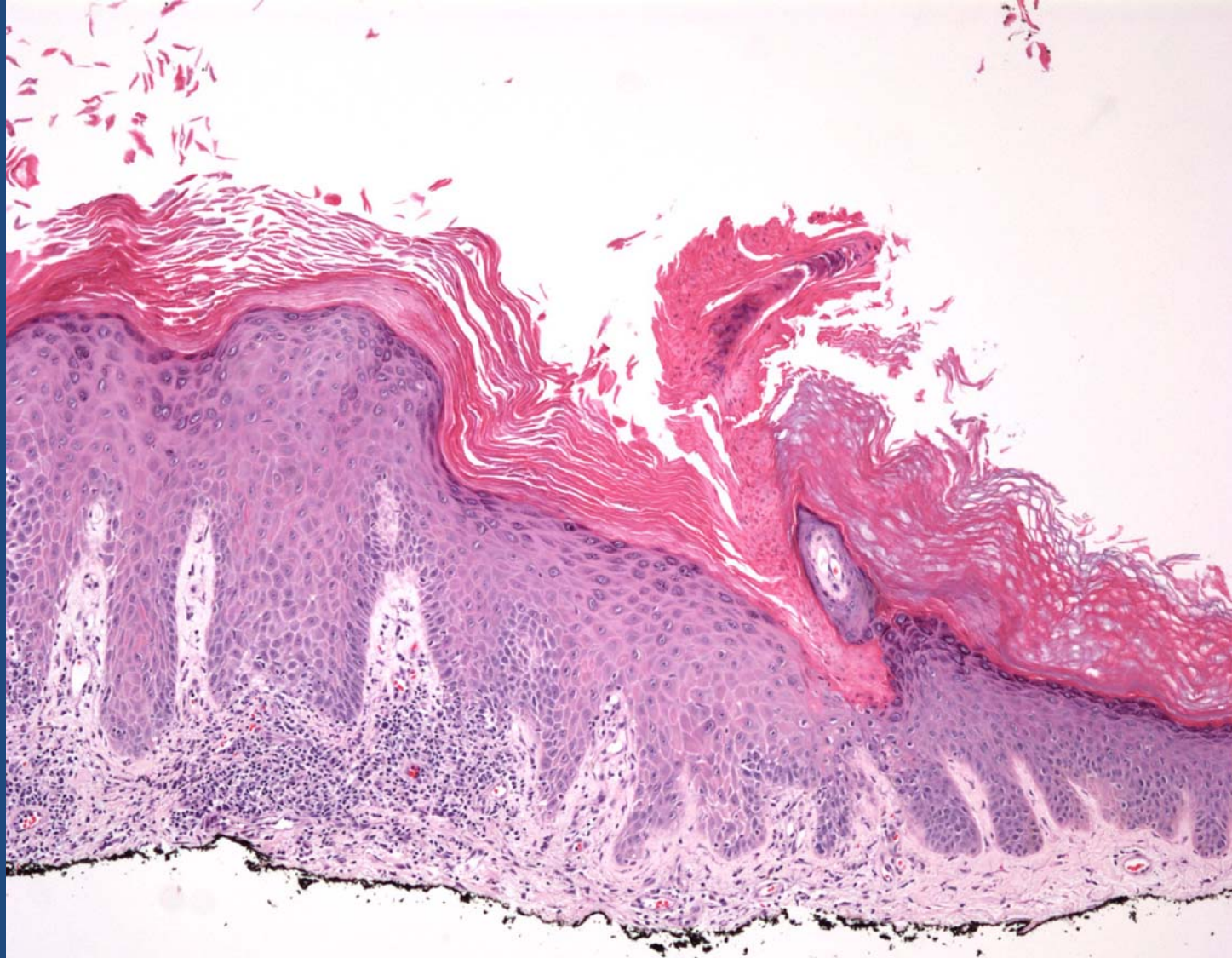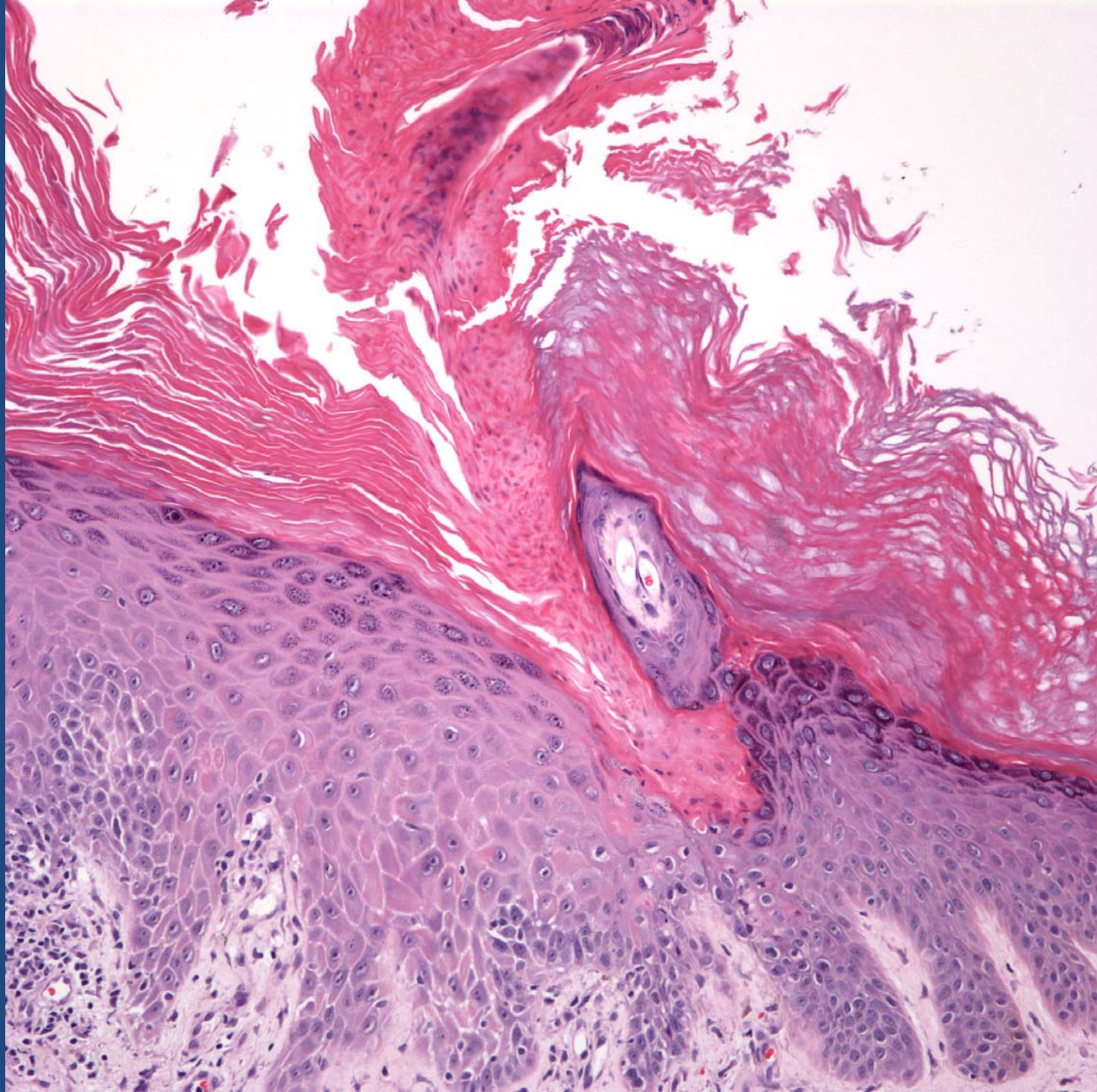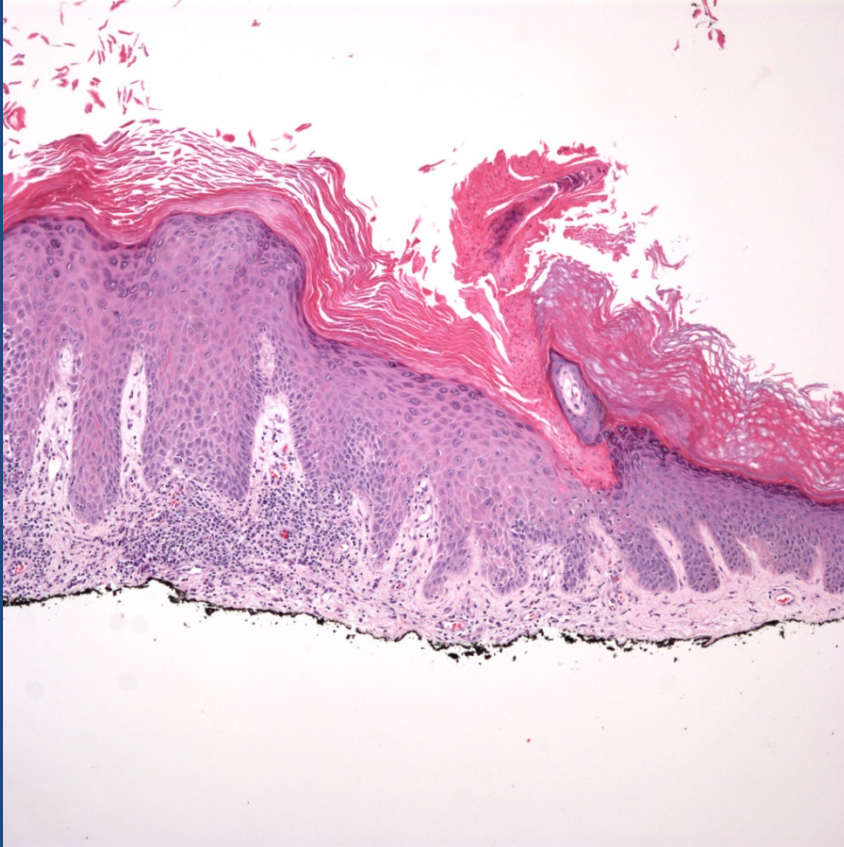


# Porokeratosis of Mibelli

# Pearls



- Cornoid lamella adjacent to epidermal papillomatosis
- Diminished granular layer beneath the cornoid lamella