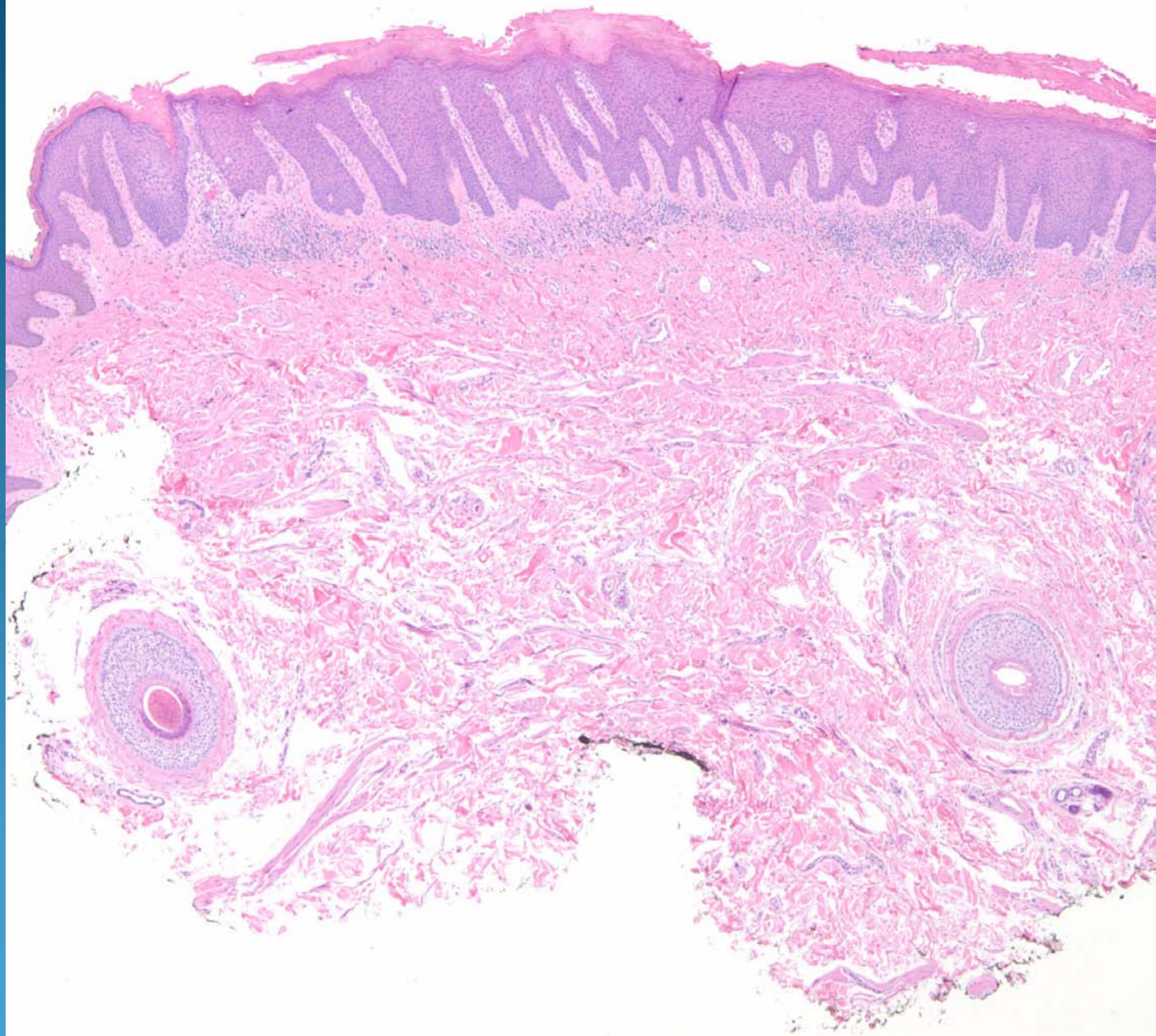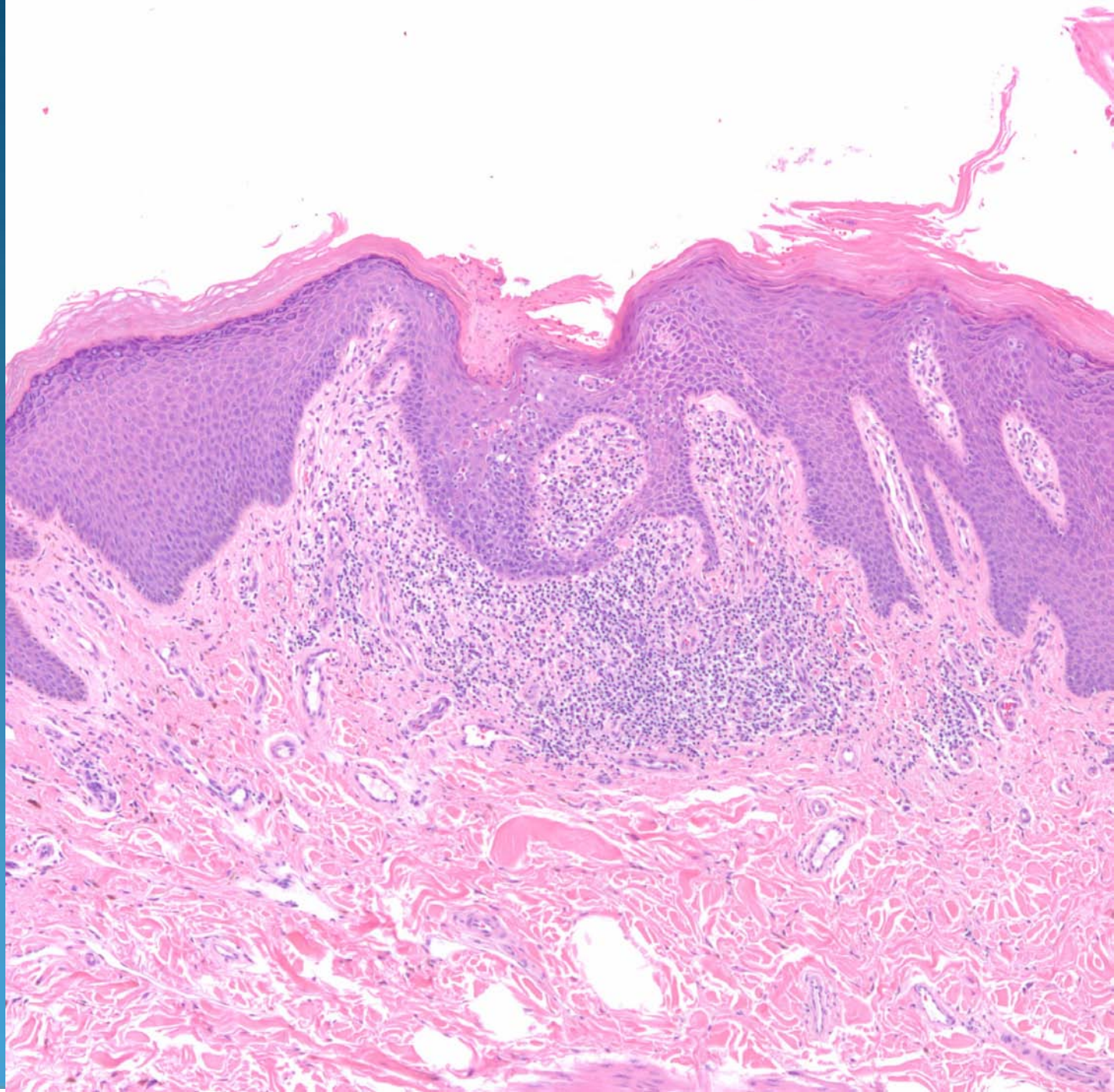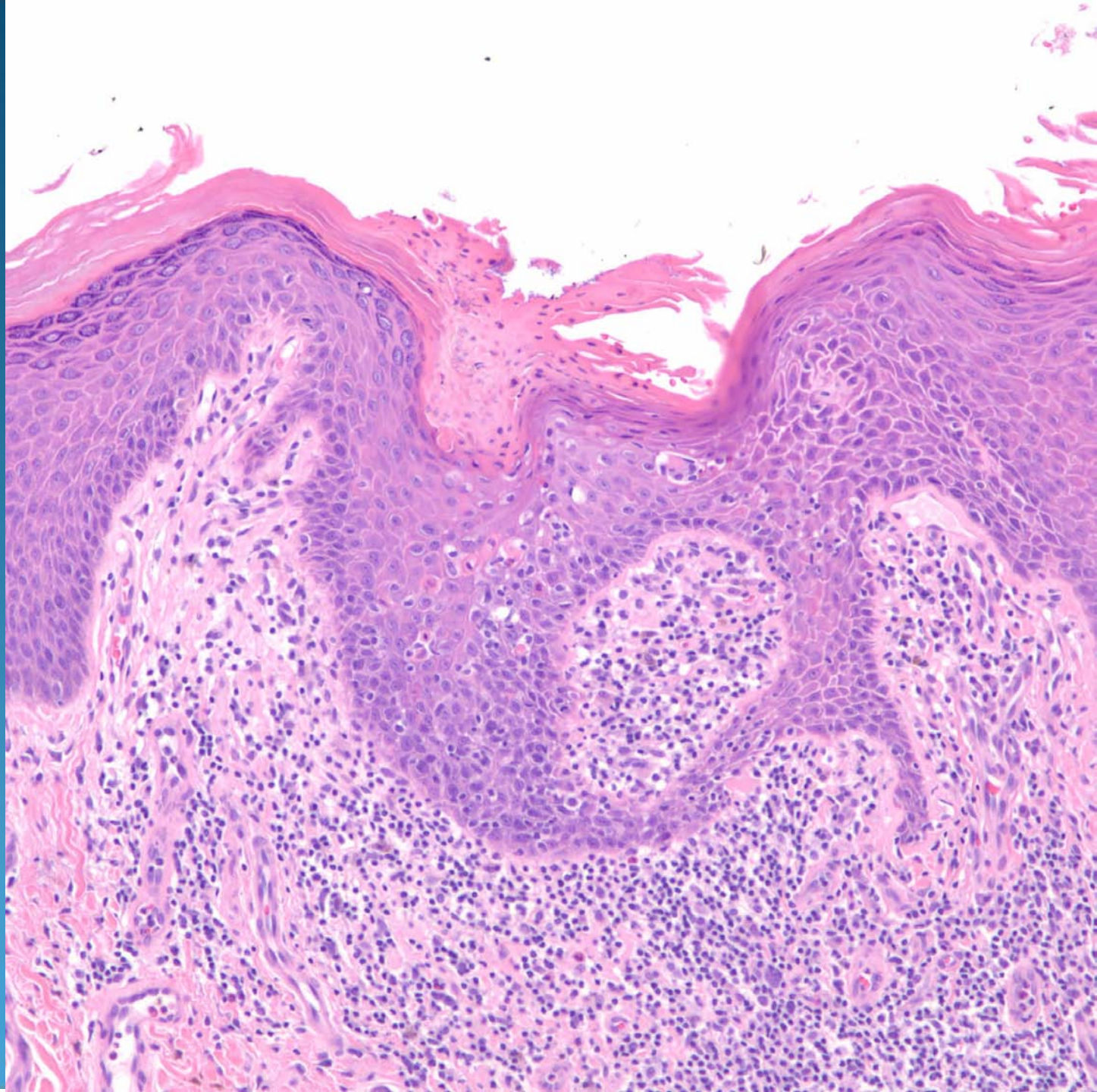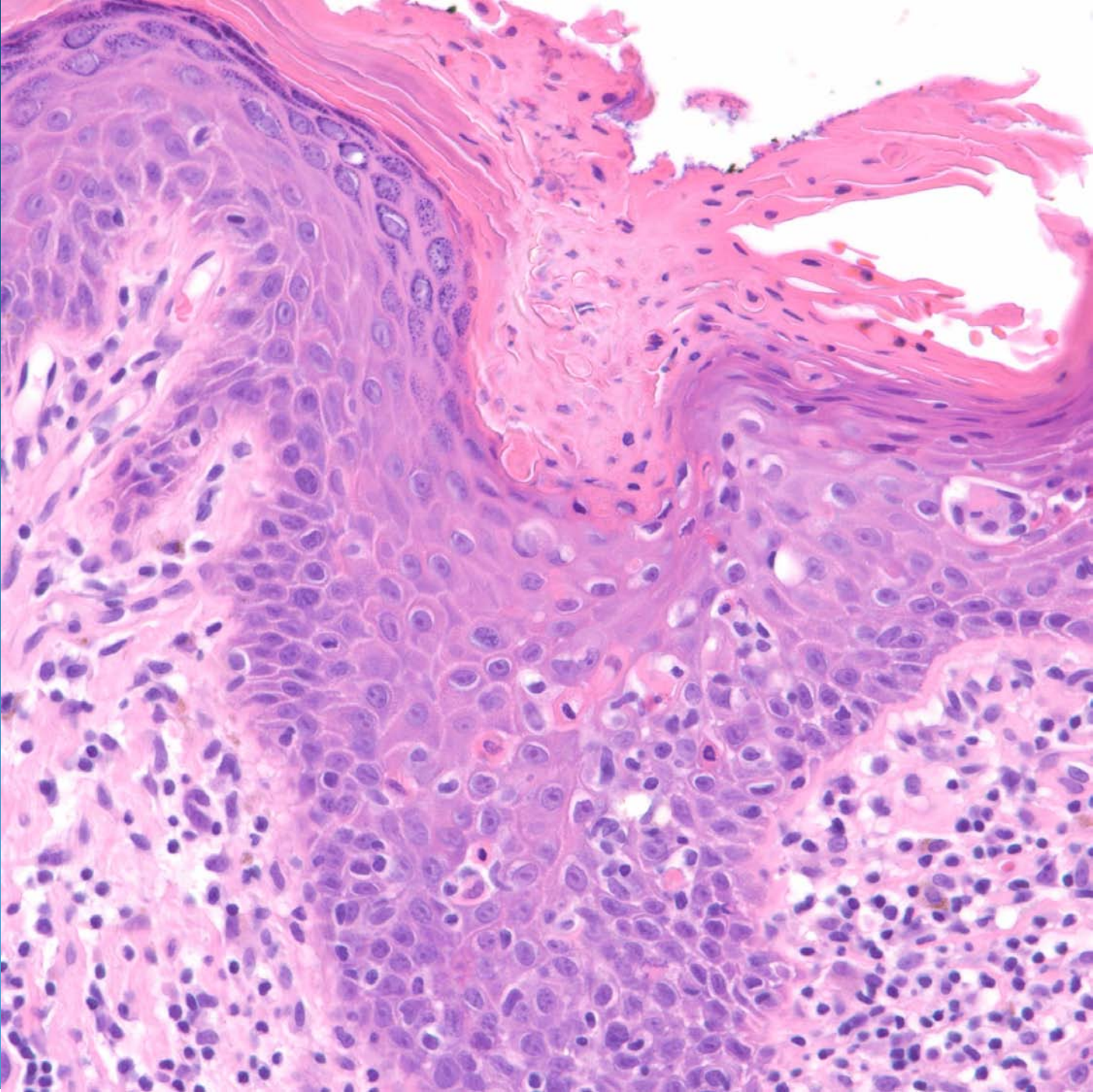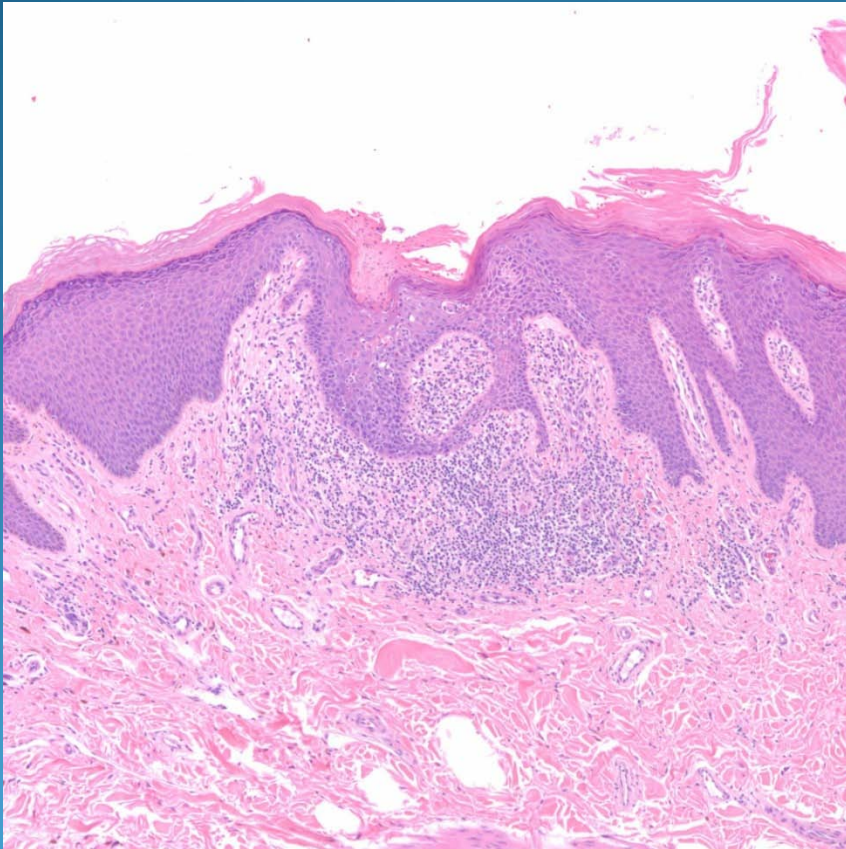


# Porokeratosis of Mibelli

# Pearls



- Silhouette of benign keratosis
- Look for cornoid lamella
- May have focal lichenoid inflammatory cell infiltrate