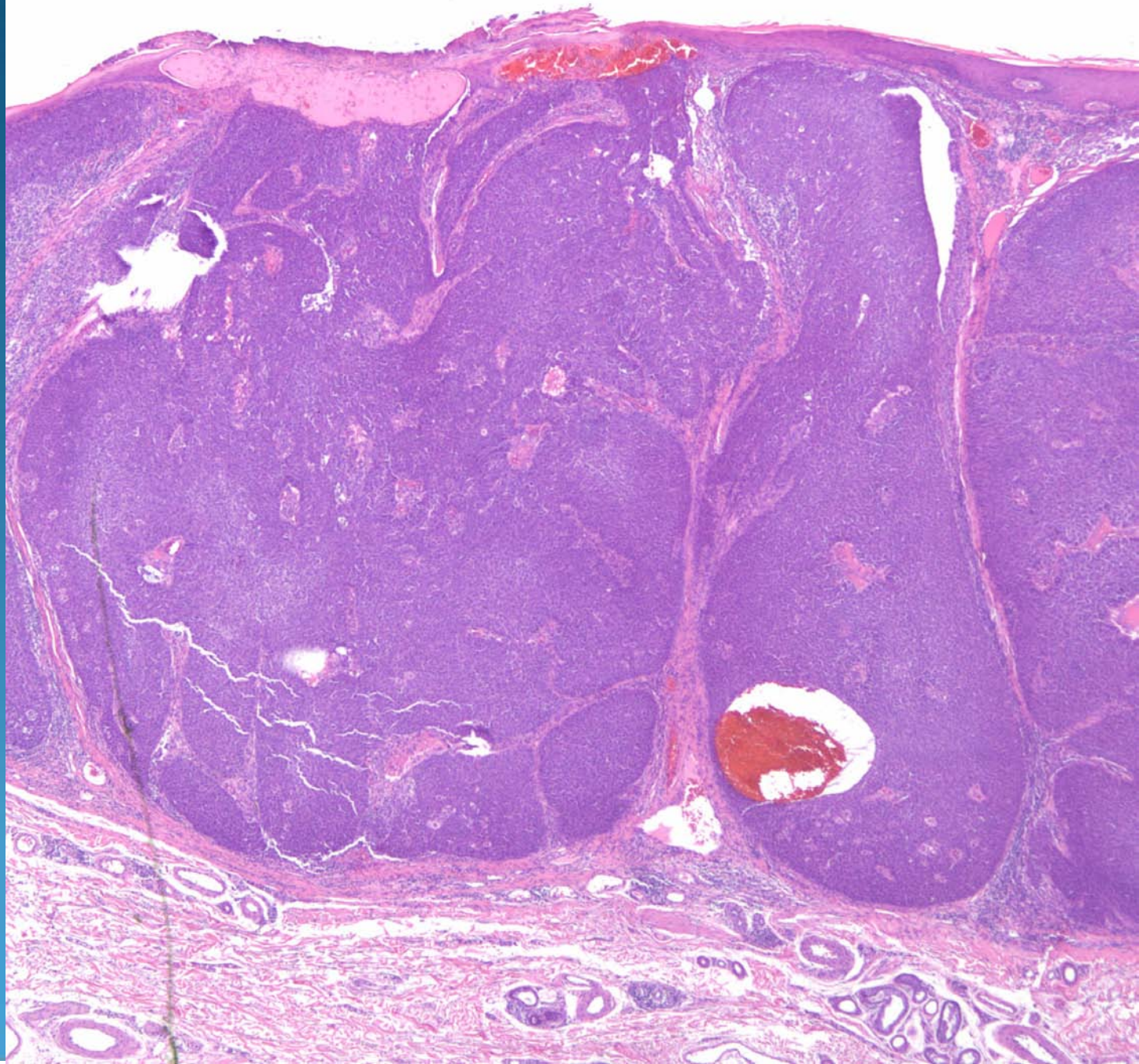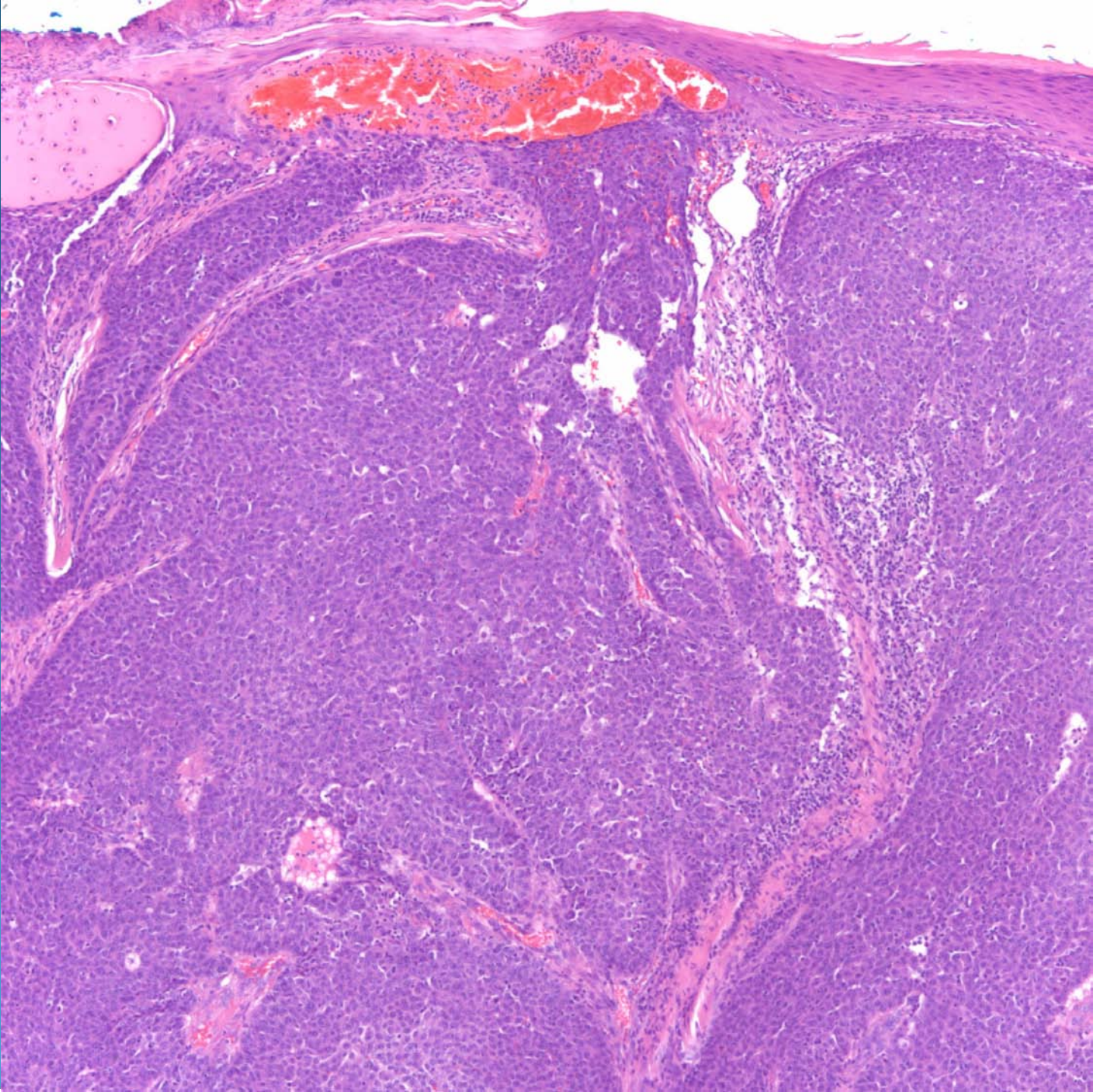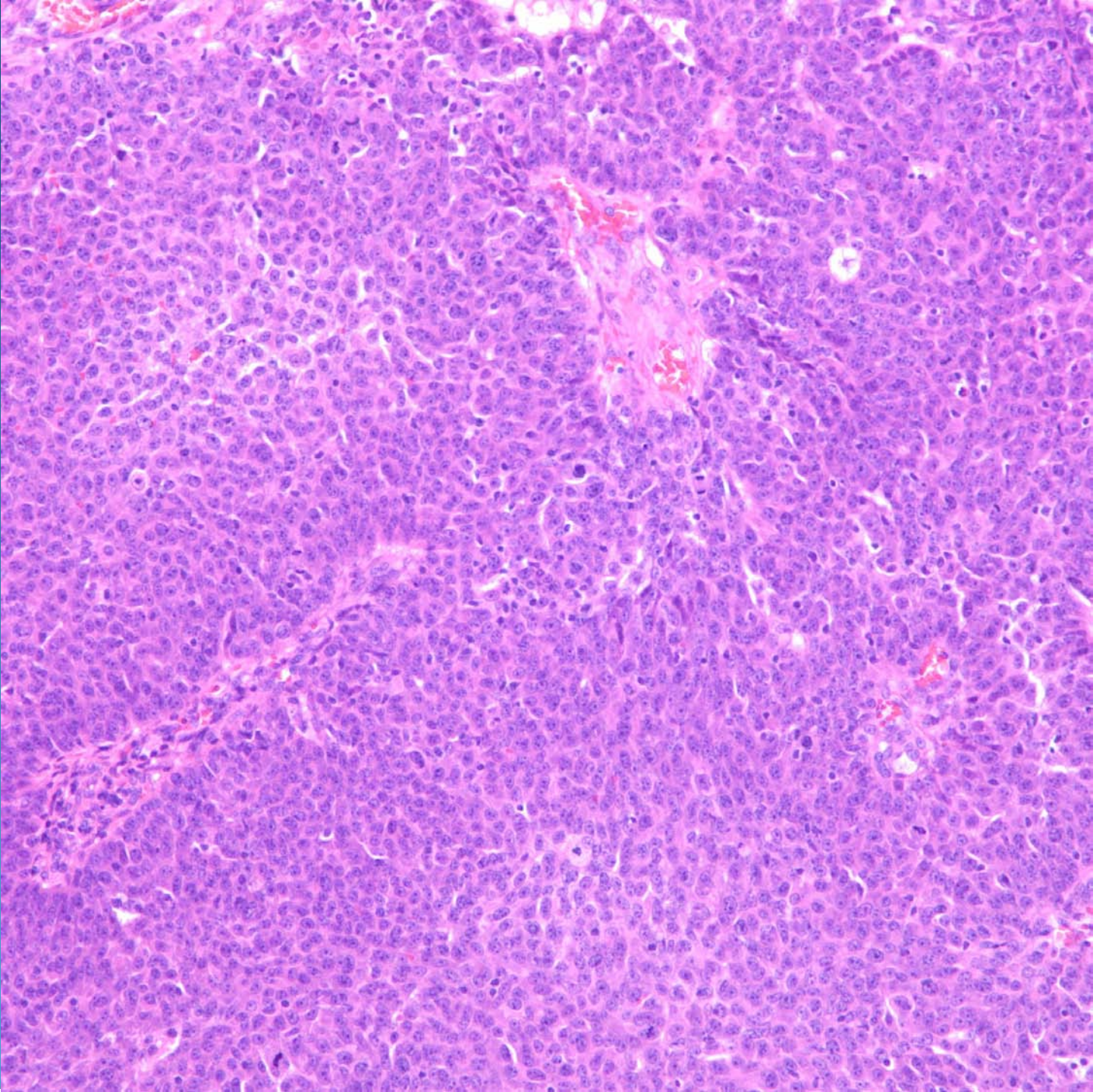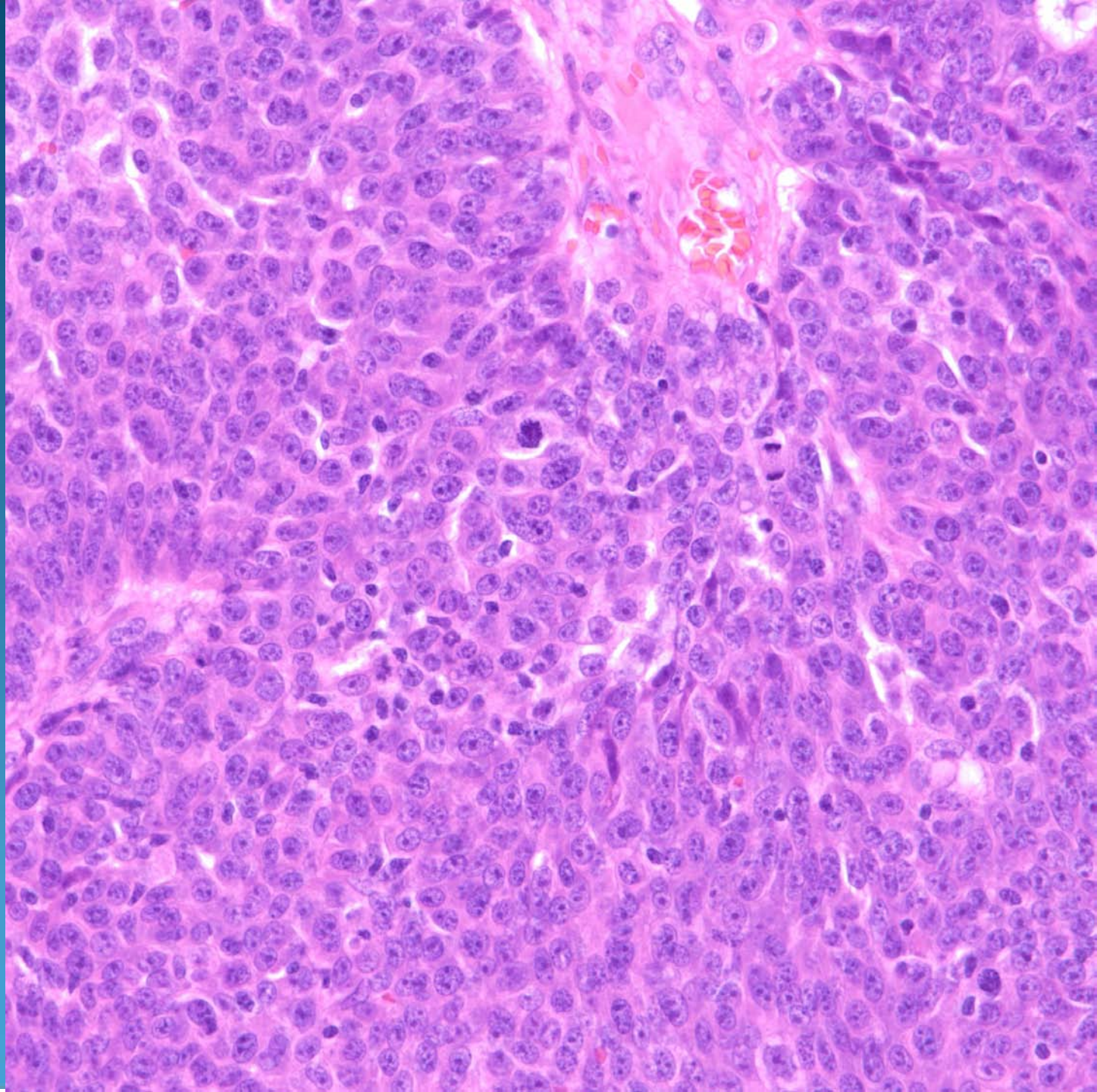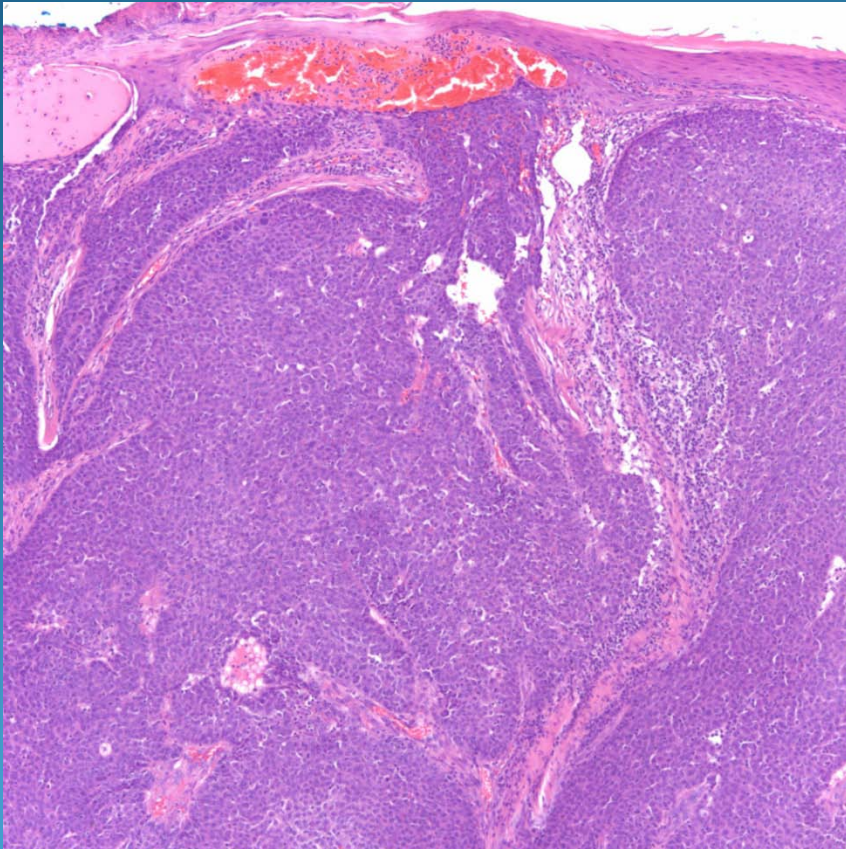


Eccrine Porocarcinoma

Pearls



- Broad based basophilic tumor attached to epidermis
- Broad pushing front with focally infiltrative borders
- Cytologically malignant
- Hyalinized vessels