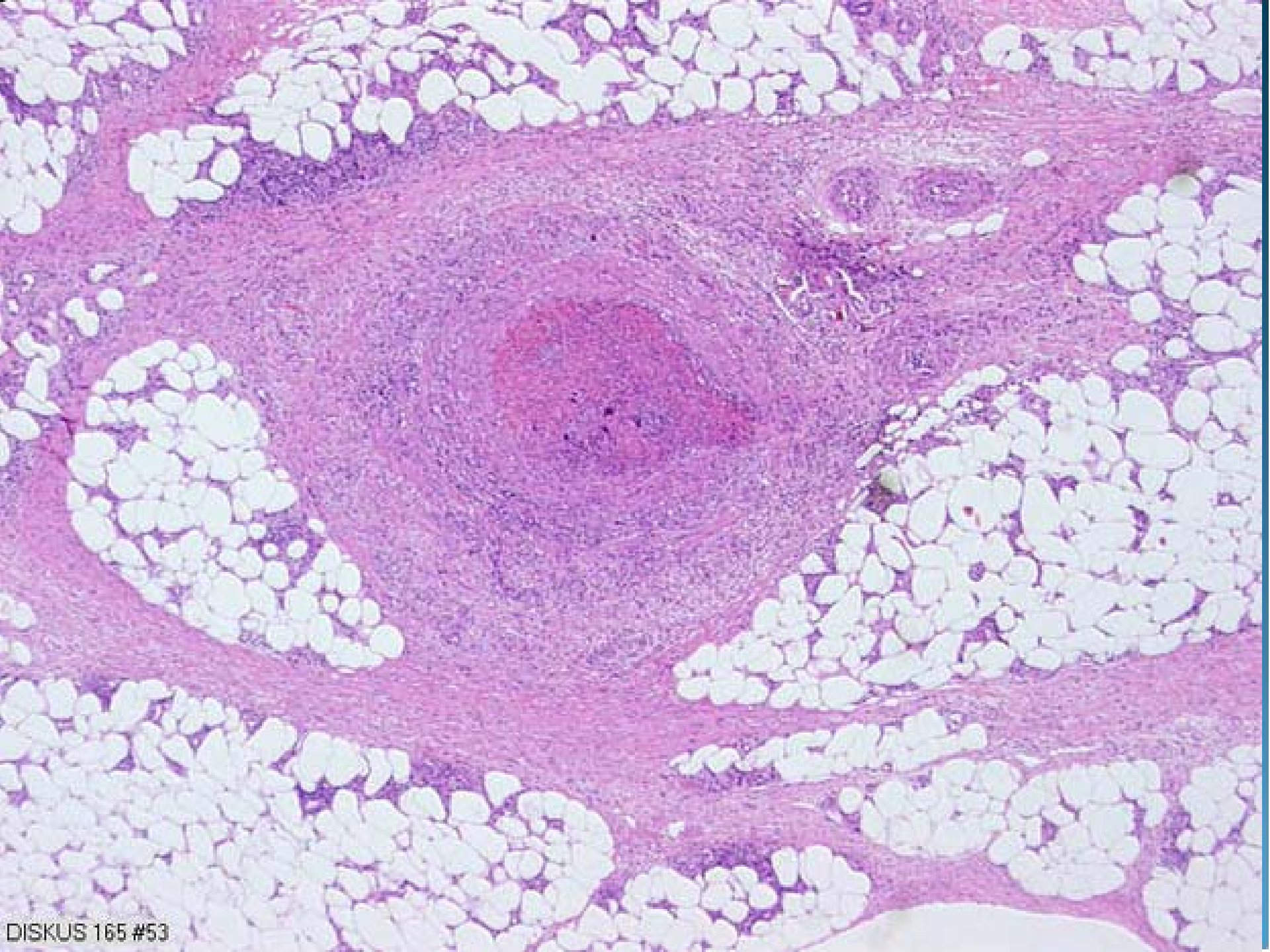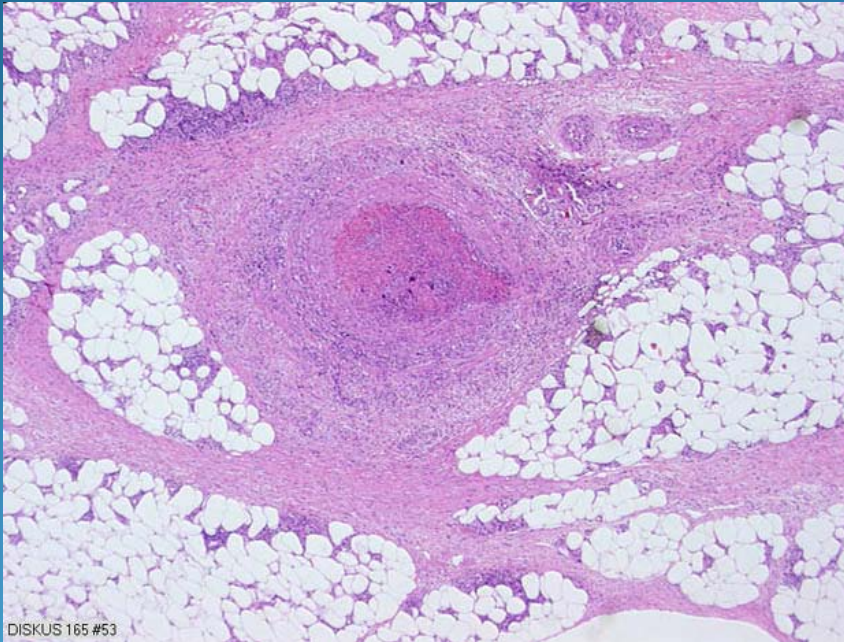


Polyarteritis Nodosa

Pearls



- Large vessel vasculitis with minimal necrosis
- Only focal involvement with neutrophils surrounding in small focus around vessel
- *E. induratum* usually has necrosis