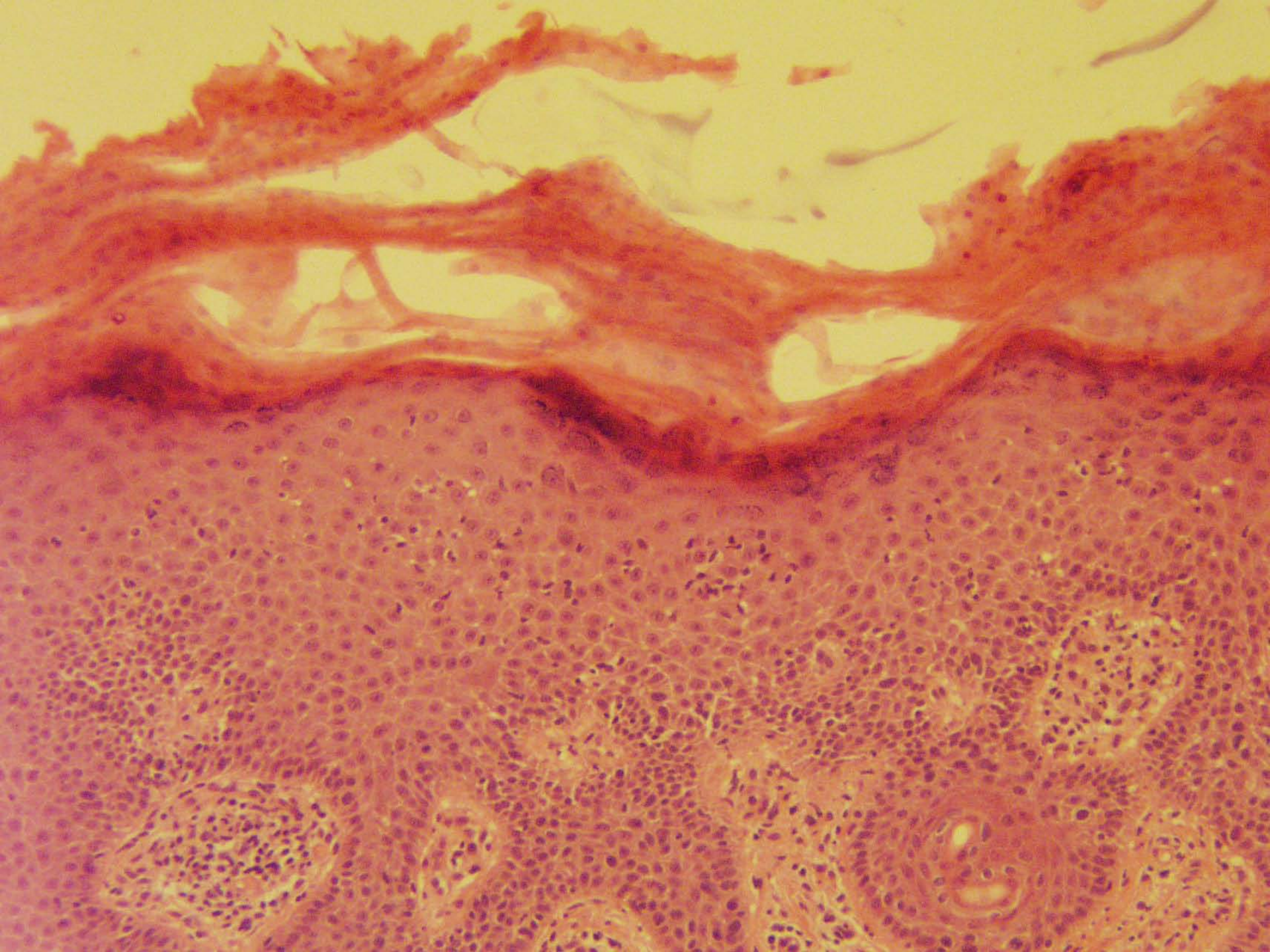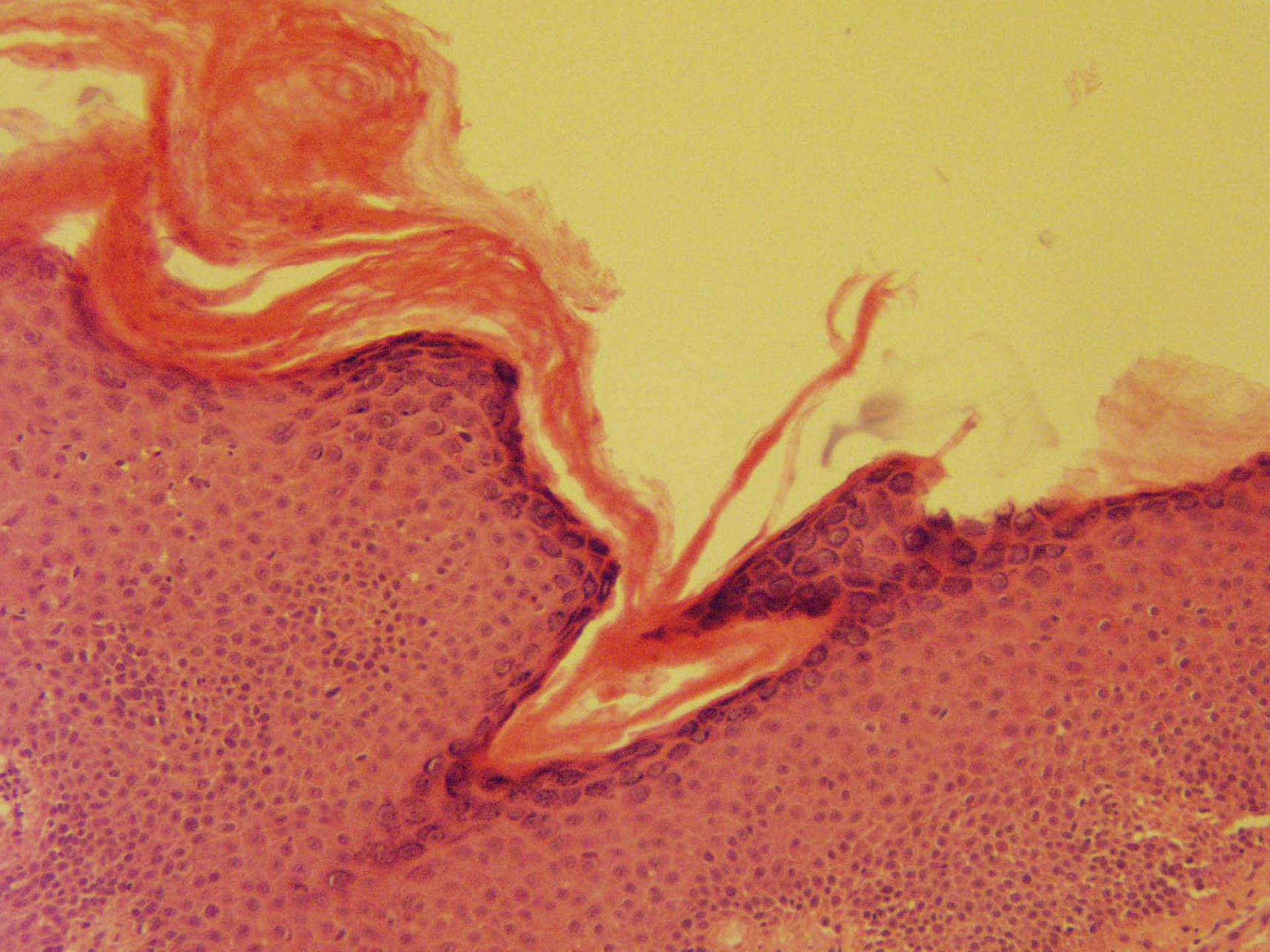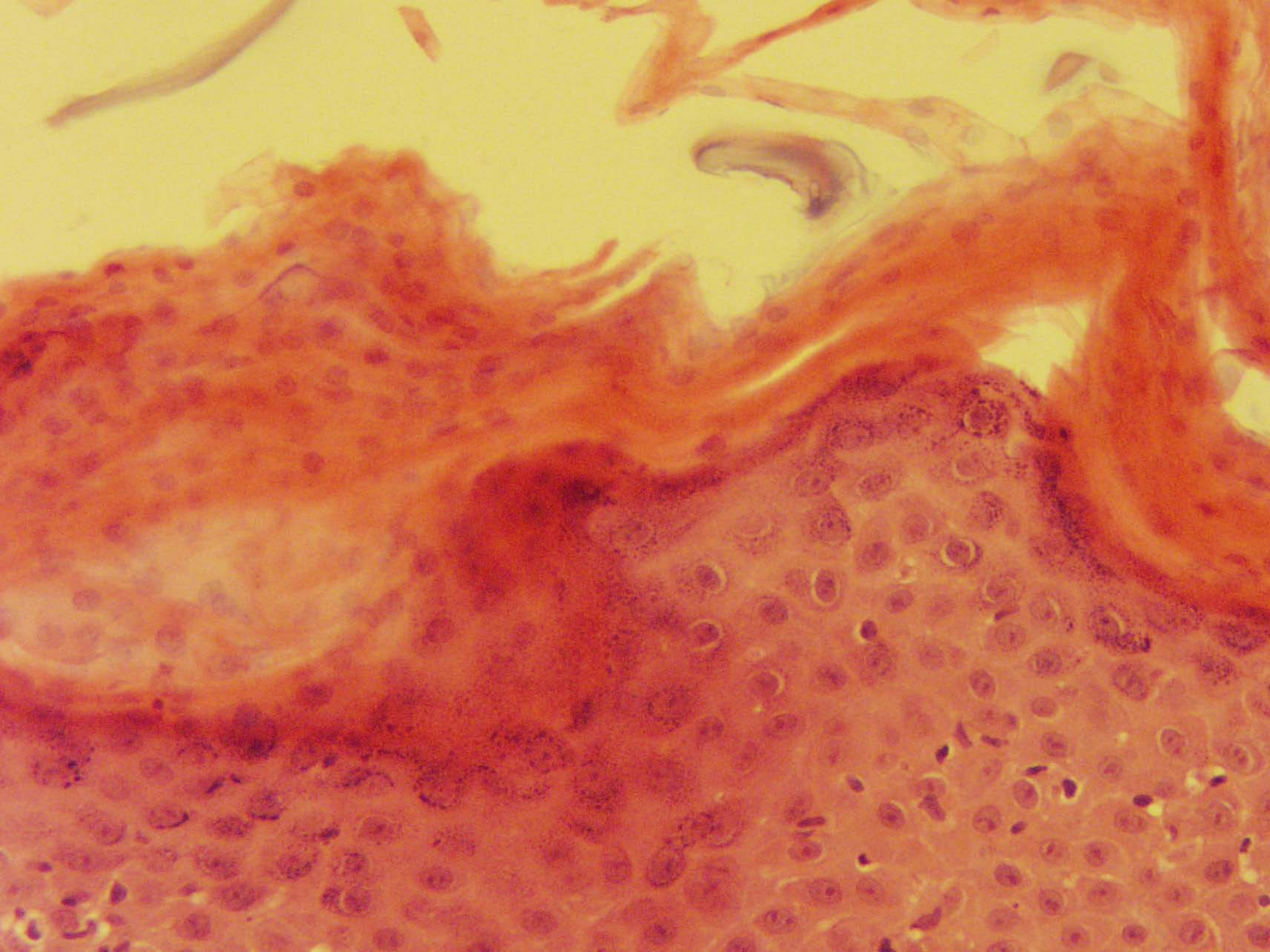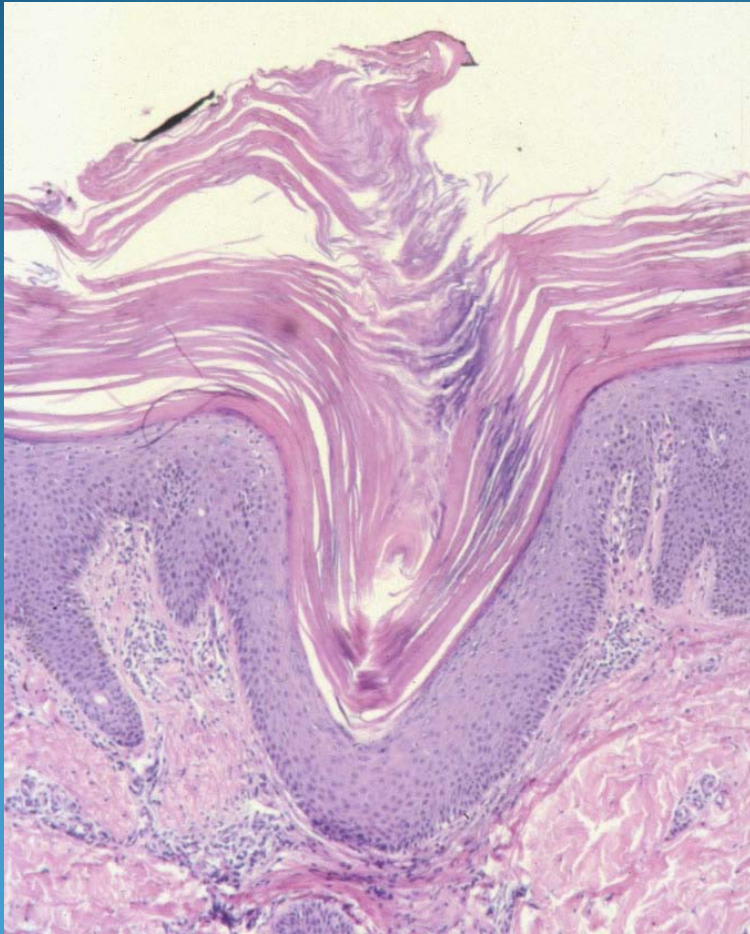


# Pityriasis Rubra Pilaris

# Pearls



- Keratotic follicular plug above level of epidermis is diagnostic
- Hyper or hypogranulosis
- Alternating para and orthokeratosis with pmns
- Shouldering parakeratosis extending into follicle