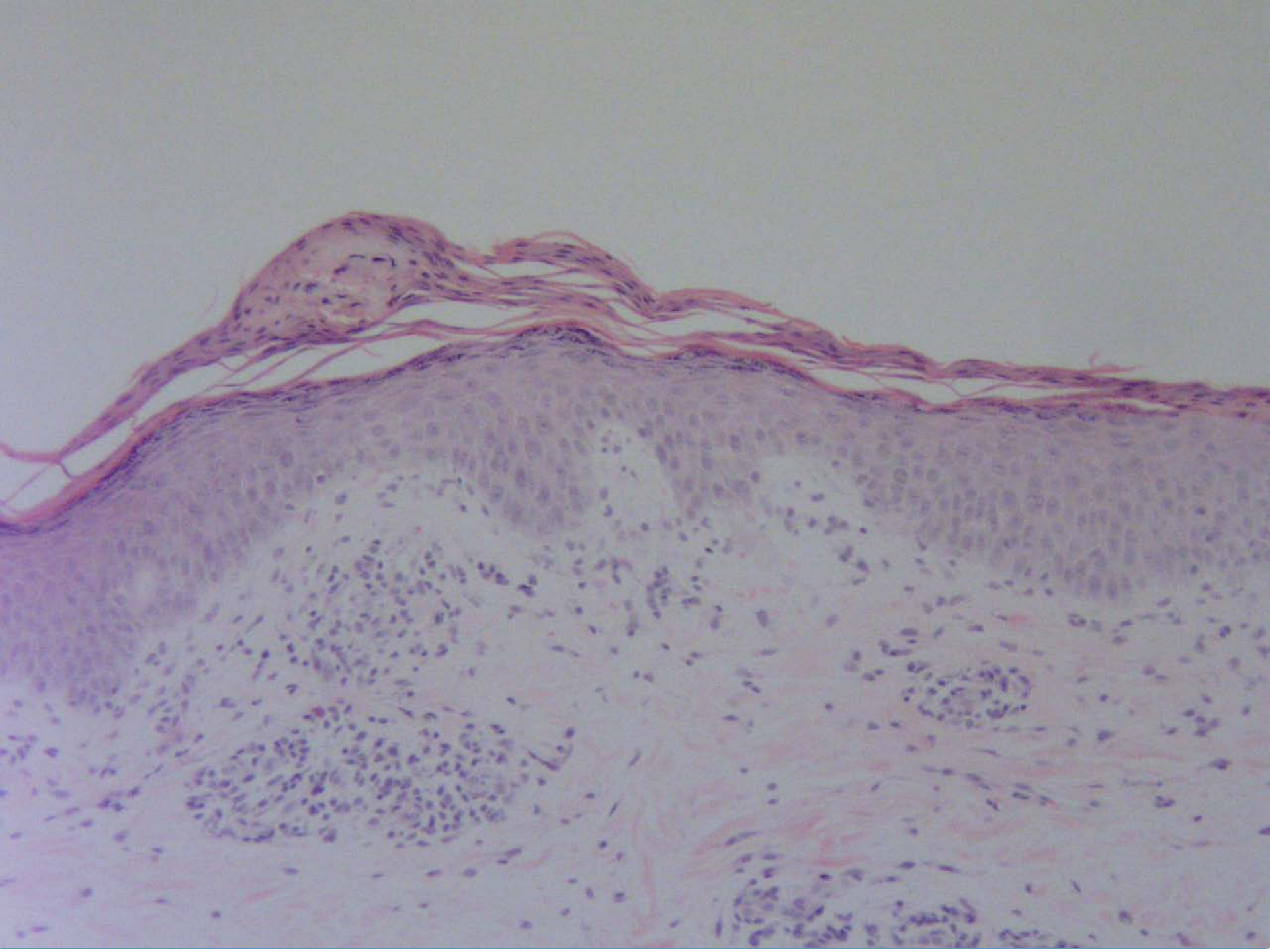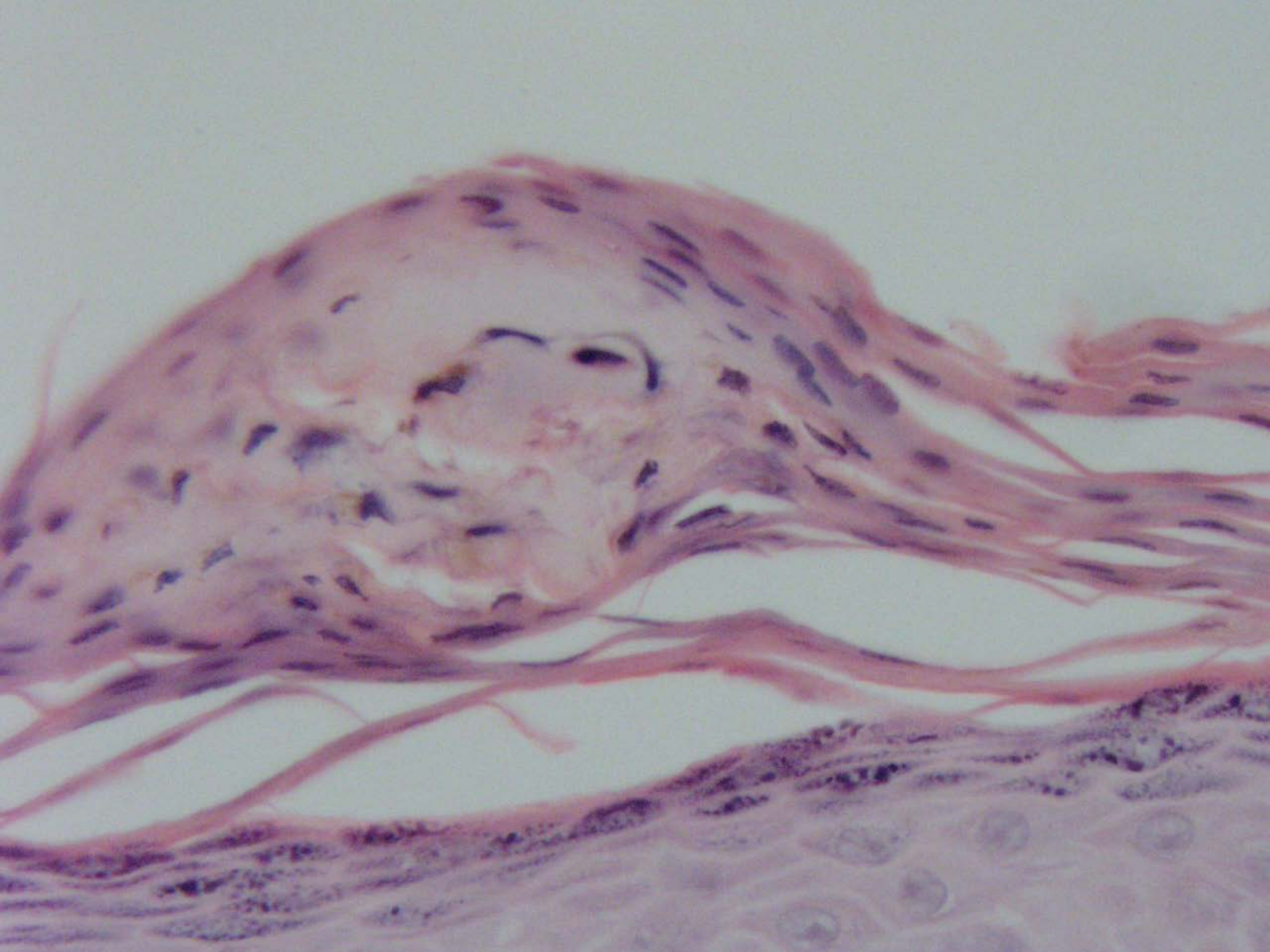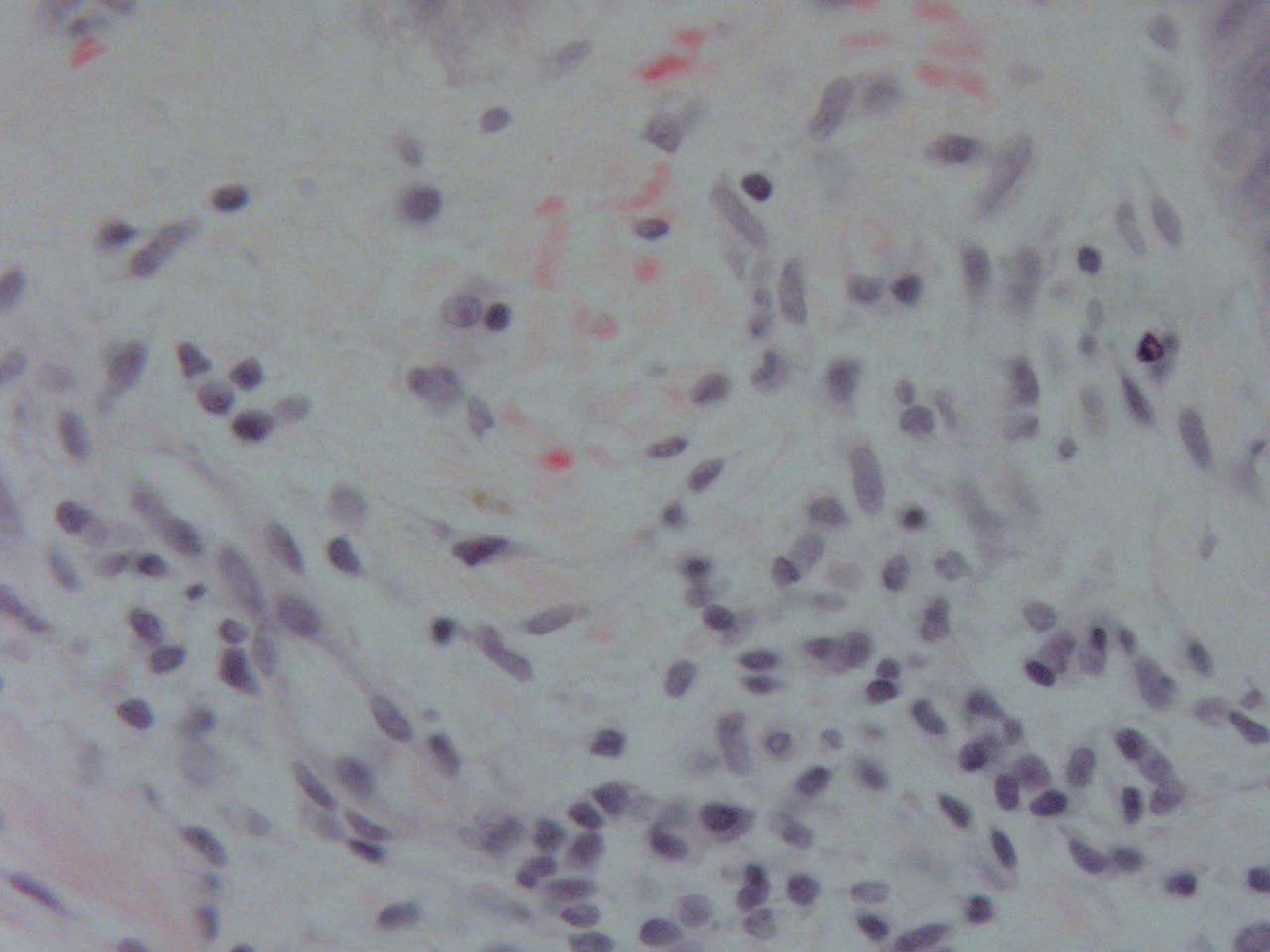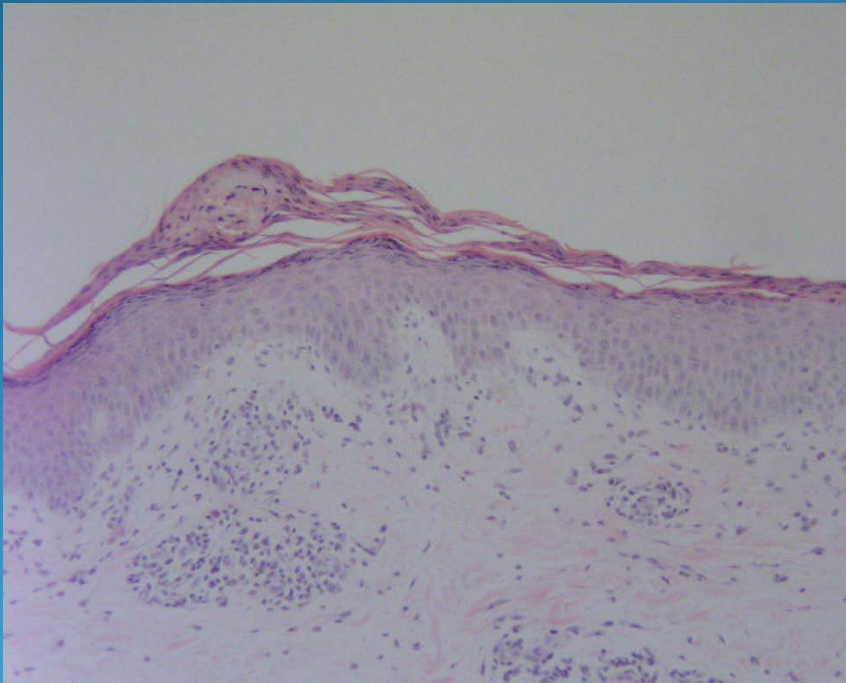


Pityriasis Rosea

Pearls



- Parakeratotic mound
- Minimal spongiosis
- Perivascular lymphocytic infiltrate
- Granular layer present
- Not wafer-like scale as in psoriasis
- If plasma cells, think syphilis